

Peritoneal Hydatid Cysts in Children: A Case Series of Rare Echinococcosis Localization

Nahla Kechiche, MD;  Dorsaf Makhoulouf, MD; Rachida Lamiri, MD; Arije Zouaoui, MD; Lassaad Sahnoun, PhD; Mongi Mekki, PhD; Mohssen Belguith, PhD; Abdellatif Nouri, PhD

Research Laboratory Children Malformative and Tumoral Pathology LR12SP13, Department of Pediatric Surgery, University of Monastir, Monastir, Tunisia

Correspondence:

Nahla Kechiche, MD;
LR12SP13, Department of Pediatric Surgery, University Hospital Fattouma Bourguiba Monastir, University of Monastir, P.O. Box: 5000, Monastir, Tunisia

Email: kechichenahla@gmail.com

Received: 07 May 2019

Revised: 17 August 2019

Accepted: 27 August 2019

Abstract

Peritoneal hydatid cysts are rare in children even in endemic areas. The primary or secondary origin of this site remains controversial, especially in children. Secondary peritoneal hydatid cysts are mainly the result of spontaneous or traumatic rupture of concomitant liver cysts or the leakage of cystic content during surgery. The purpose of our study is to present the largest case series of peritoneal hydatidosis in children. In addition, we aimed to assess the clinical and paraclinical findings as well as the management of echinococcosis at this location in children. The present case series is a study of ten children with peritoneal hydatid cysts, who underwent surgical intervention between 2013 and 2018 in the Pediatric Surgery Department, University of Monastir (Monastir, Tunisia). The mean age of the children was six years. All children presented abdominal pain, and underwent ultrasonography and contrast-enhanced computed tomography of the abdomen. Two patients had been operated on for lung hydatid cysts six months prior to the study. In two cases, radiologic investigations revealed the presence of an uncomplicated hepatic hydatid cyst located in segments II and IV. All patients underwent surgery, of which four underwent laparoscopy. Post-surgery, all patients received albendazole for three months, and the follow-up period was uneventful. Currently, all patients are in good health. Peritoneal hydatid disease is frequently secondary to the rupture of a primary hepatic cyst. Diagnosis is performed by abdominal ultrasound, computed tomography, and a positive serology result. Open or laparoscopic excision can be combined with medical treatment.

Please cite this article as: Kechiche N, Makhoulouf D, Lamiri R, Zouaoui A, Sahnoun L, Mekki M, Belguith M, Nouri A. Peritoneal Hydatid Cysts in Children: A Case Series of Rare Echinococcosis Localization. *Iran J Med Sci*. 2021;46(1):68-72. doi: 10.30476/ijms.2020.82004.0.

Keywords • Child • Echinococcosis • Peritoneum

What's Known

- Peritoneal hydatid cysts are rare in children even in endemic areas.
- The most common sites of involvement are the lungs and the liver.

What's New

- There is no consensus as to whether peritoneal localization of hydatid cysts is of primary or secondary origin.
- Laparoscopic excision of peritoneal cysts is safe and efficient.

Introduction

Hydatid disease is relatively uncommon in children even in endemic areas. The most common sites of involvement are the lungs and the liver. This cystic lesion rarely occurs in the peritoneal cavity, which is an unusual site. Peritoneal hydatid cyst disease is expected to occur after the rupture of the primary hepatic cyst (secondary origin) or as the primary localization without the involvement of any other organ.¹ Several case studies on adults have been conducted in different countries,¹ but pediatric cases are rarely reported. Therefore, little is known about peritoneal hydatidosis in this age group.¹ The present study presents the largest case series of peritoneal hydatidosis in children. We aimed to determine the clinical and paraclinical findings as well

as the management of such a rare location of echinococcosis in children.

Case Presentation

A case series study of children was conducted at the Pediatric Surgery Department, University of Monastir, Monastir, Tunisia. The medical records of the patients with peritoneal hydatid cysts, who were operated at our department between January 2013 and December 2018 were reviewed. We included all patients with a confirmed diagnosis of hydatid cyst of the peritoneum, who underwent surgery. Patients, who had undergone the surgery in other departments or those with incomplete medical records were excluded from the study. Written informed consent was obtained from the patients' guardians.

A total of ten patients (four boys and six girls) with a mean age of 6 years (range: 3-10 years) were enrolled in the study. None of the patients had a history of blunt trauma. Only two patients underwent surgery for lung hydatid cysts six months prior to the study with an uneventful postoperative course and no relapse. However, the peritoneal hydatid cysts were present prior to the first intervention.

All children presented abdominal pain, two had abdominal distension, and three had fever. Abdominal mass was revealed by palpation in two patients, and one patient experienced vomiting. The results of the hydatid serological test were positive in all cases. Abdominal ultrasonography and computed tomography showed cystic masses in the peritoneal cavity with a diameter ranging from 5 to 14 cm (figure 1). Four cysts were in the pelvic peritoneum, and the other six were located in the mesentery, adherent to the serosa of the small gut and colon (figure 2). Except for one, all other cysts were independent of other abdominal viscera. That one cyst arose from the mesentery and was

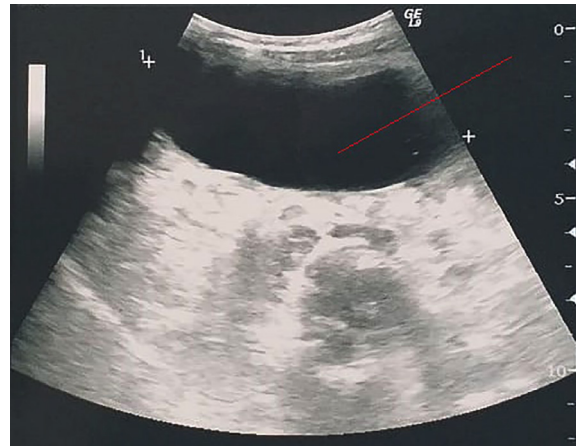


Figure 1: Ultrasonography shows a cystic mass in the peritoneal cavity.

found to be firmly adherent to the right ovary. The liver, spleen, and other organs showed no cystic lesions in six cases. However, in two cases, radiologic investigations revealed the presence of an uncomplicated hepatic hydatid cyst, located in segments II and IV.

All patients were operated on, four of whom underwent laparoscopy. In these patients, the cysts were excised along with the rim of the omentum all around without any spillage (figure 3). In patients treated by laparoscopy, we performed a puncture, aspiration, and evacuation of the cyst contents; including the hydatid membrane. The patients were discharged after an uneventful recovery period (range: 3-7 days), and postoperatively treated with albendazole 10 mg/kg/day (Opalia Pharma) for three months. The progress of all patients was satisfactory. Abdominal ultrasonography during follow-up did not show any evidence of recurrence. The abdominal and pelvic cavity remained totally free from cysts. The mean follow-up was 13 months (range: 3-34 months). Demographic, clinical, and paraclinical characteristics of all patients are summarized in table 1.

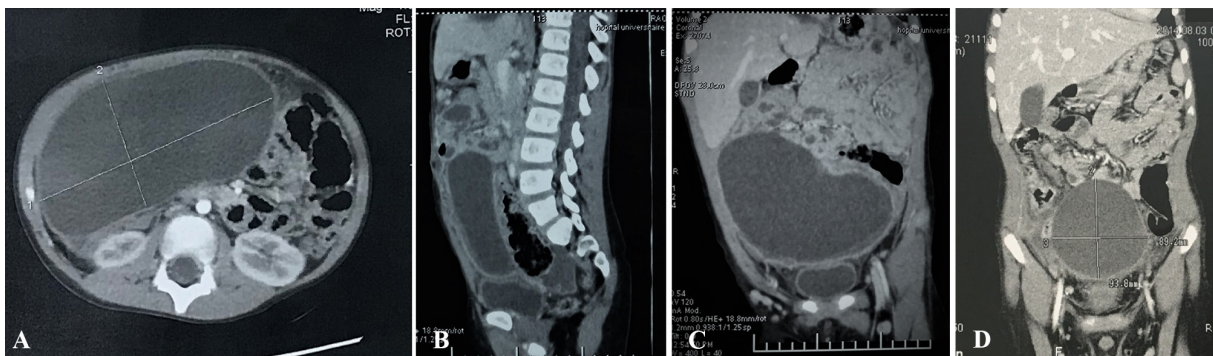


Figure 2: A) Computed tomography reveals a cystic mass adherent to the liver and the right ovary, B) Computed tomography reveals a cystic mass adherent to the liver and the right ovary, C) Computed tomography shows a large peritoneal cyst. D) This figure shows an image of a pelvic hydatid cyst.

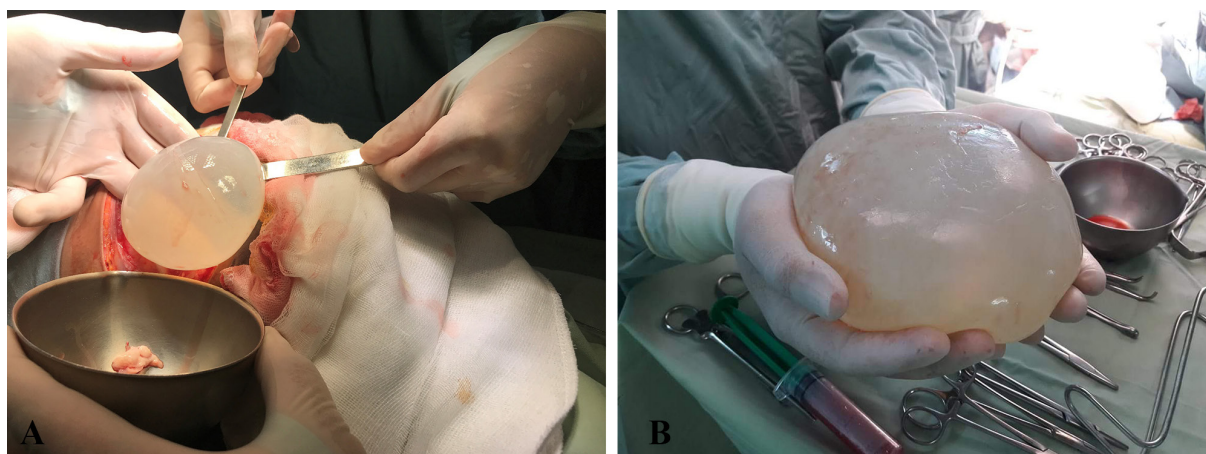


Figure 3: A) Peritoneal hydatid cyst bulges out through the incision, B) A hydatid unilocular cyst is shown in this figure.

Table 1: Demographic, clinical, and paraclinical characteristics of patients

Patient	Sex	Age	Medical history	Symptoms	Hydatid serology	Abdominal ultrasonography+CT scan	Treatment
1	Boy	5 years	Operated on for lung hydatid cyst 6 months earlier	Chronic abdominal pain+fever	+	3 cm hydatid cyst located in segment VI+7cm peritoneal hydatid cyst in continuity with bladder	Laparoscopy
2	Boy	7 years	Contact with dogs	Abdominal pain+abdomino-pelvic lump	+	8 cm cyst arising from pelvic peritoneum	Open approach
3	Girl	3 years	Contact with dogs	Abdominal pain +abdominal mass	+	8 cm hydatid cyst in the peritoneal cavity+liver hydatid cyst located in segment II	Laparoscopy
4	Boy	9 years	Contact with dogs	Abdominal pain+fever	+	9 cm cyst arising from pelvic peritoneum	Open approach
5	Girl	5 years	Contact with dogs	Abdominal pain +abdominal distension	+	13 cm unilocular cyst filling the cavity of the peritoneum	Open approach
6	Girl	6 years	Contact with dogs	Abdominal pain+vomiting+ abdominal distension	+	14 cm unilocular cyst filling the cavity of the peritoneum	Open approach
7	Girl	10 years	Contact with dogs	Abdominal pain	+	5 cm unilocular cyst filling the cavity of the peritoneum	Laparoscopy
8	Boy	3 years	Contact with dogs	Abdominal pain+fever	+	5 cm cystic lesion in the right iliac fossa, lateral to the descending colon	Open approach
9	Girl	7 years	Operated on for lung hydatid cyst 6 months earlier	Abdominal pain+abdominal mass	+	7 cm cyst arising from pelvic peritoneum, adherent to the right ovary	Laparoscopy
10	Girl	4 years	Contact with dogs	Abdominal pain	+	7 cm cyst filling the cavity of the peritoneum	Open approach

Discussion

Peritoneal hydatid cyst is an uncommon and rare location of echinococcosis.¹ Due to slow enlargement of the cyst, the most common clinical feature is vague abdominal pain. This may cause diagnostic delay, which could be life-threatening, since peritoneal cysts can cause peritonitis and anaphylactic shocks.² Surgeons must be aware of the possibility of cyst growth at this site and its implications to avoid serious complications.

Peritoneal hydatid disease has been reported to occur in 13% of all abdominal hydatidosis.² In the present case series, peritoneal hydatid cysts accounted for 10% of all intra-abdominal hydatid cysts. They are more frequent when secondary to a spontaneous rupture of a liver hydatid cyst or spillage of cystic fluid during intraperitoneal surgery.² In our patients, imaging showed a unilocular uncomplicated cyst in all cases, and none of the patients underwent surgery for a hepatic hydatid cyst.

A peritoneal hydatid cyst is considered primary, when no other cysts are present.¹ According to the literature, the secondary type occurs in only 2% of cases.³ Physical barriers to the diffusion of cysts are created by the liver and lungs. This could explain the reason for the low prevalence of echinococcosis of the peritoneum.³ There are ambiguities and a lack of consensus on the mechanism of primary peritoneal infection by parasites.² A previous study on primary peritoneal hydatid cysts have proposed several hypotheses, none of which have been confirmed.³ In fact, its dissemination into the peritoneal cavity could be through systemic or lymphatic circulation. However, some researchers have suggested that it could also be the result of hepatic cyst migration or the rupture of adventitia without rupturing the cyst membrane.⁴ To differentiate primary from secondary hydatid cysts, one could consider criteria such as the absence of any history of rupture, abdominal trauma, or adhesions.

In this study, peritoneal cyst localization in the liver and peritoneum was noted in two cases. However, it is difficult to confirm that these cysts developed secondary to the liver cysts. In fact, patient history and preoperative imaging findings did not indicate the rupture of the hepatic hydatid cyst. Multiple intra-abdominal localization is often secondary to the micro-rupture of cysts or the microscopic intraoperative spillage of hydatid fluid.²

In all our patients, irrespective of association with hepatic localization, the peritoneal hydatid cysts were solitary. This could be explained by the fact that the cysts are unilocular in pediatric patients. However, the primary or secondary origin of the peritoneal hydatid cyst cannot be confirmed with absolute certainty. Although the origin could be unimportant, since it does not have any clinical or therapeutic implications, and the only prognostic factor is the number of hydatid cysts and its dissemination.⁵

Hydatid serological testing and imaging are the main diagnostic tools.² ELISA could also be a suitable serological test to confirm a hydatid cyst, since its sensitivity varies from 95%-97%.⁶ In our study, the tests were positive in all cases. Ultrasonography of the abdomen is the most common first-line imaging modality to identify the originating organ and to characterize the cyst.⁶ It leads to diagnosis in more than 95% of cases with a sensitivity of 90%-95%.^{7,8} Computed tomography is another useful modality for the diagnosis and therapeutic planning.⁶ It has a high sensitivity of about 95%-100%.⁸ Differential diagnosis of intra-abdominal cystic lesions arising from omentum may include ovarian cysts, pancreatic

cysts, mesenteric cysts, lymphangiomas, and gastrointestinal duplication cysts.⁶

The main treatment goals are to eliminate localized diseases, prevent complications, and minimize the risk of recurrence. Open surgery with complete excision of the cyst remains the treatment of choice for peritoneal echinococcosis, especially with coexistent hepatic cysts.⁷ Laparoscopic cyst excision, although technically difficult, is also an option.⁶ In our case series, open excision was performed in six patients, and the other four patients were treated by laparoscopy. All patients progressed well, suggesting no preference for either surgical technique. None of the patients were treated with the percutaneous procedure to thoroughly explore the abdominal cavity and to ensure no cyst was overlooked. We considered this procedure too risky, since the cysts were in close proximity to the intestine.

There is no consensus on the exact indications for anthelmintic therapy. Albendazole suppresses parasite growth following inoculation of protoscolices into the peritoneum. Therefore, the combination of preoperative albendazole therapy, surgery, and postoperative albendazole therapy seems to be the treatment of choice to prevent recurrences.² A previous study recommended the use of albendazole except in cases, where the patient is not fit for surgery or the cyst size is small or located deep within the body.⁸ It is also proposed that surgical excision, with or without adjuvant antiparasitic therapy, is the best treatment modality with a low recurrence rate.⁸ In our study, postoperative albendazole (10 mg/kg body weight) was administered for three months, and no recurrence was detected in any of the patients. As the main strength of our study, we demonstrated that both open and laparoscopic excisions of peritoneal cysts in combination with anthelmintic therapy are safe and effective.

Conclusion

The peritoneal hydatidosis is a rare localization of hydatid disease in children. It is often secondary to the rupture (spontaneous or accidental during surgery) of primary hepatic or splenic cysts. Its clinical manifestations are dominated by abdominal pain. Pediatricians and pediatric surgeons must be aware of peritoneal hydatidosis and localization of hydatid disease for timely diagnosis and to avoid life-threatening complications. Diagnostic modalities are an abdominal ultrasound, computed tomography, and hydatid serological test. Both open and laparoscopic excisions are safe and should be

combined with pharmacological treatment to prevent recurrences.

Conflict of Interests: None declared.

References

- 1 Pandya JS, Bhambare MR, Waghmare SB, Patel AR. Primary hydatid cyst of peritoneum presented as abdominal lump: a rare presentation. *Clin Case Rep.* 2015;3:331-2. doi: 10.1002/ccr3.214. PubMed PMID: 25984316; PubMed Central PMCID: PMC4427379.
- 2 Acharya AN, Gupta S. Peritoneal hydatidosis: a review of seven cases. *Trop Gastroenterol.* 2009;30:32-4. PubMed PMID: 19624085.
- 3 Almasri B, Albitar L. Rare isolated primary peritoneal hydatid cysts: A case report from Syria. *Qatar Med J.* 2016;2016:13. doi: 10.5339/qmj.2016.13. PubMed PMID: 28567367; PubMed Central PMCID: PMC442311.
- 4 Haddad N, Tabbane S, Ellouze N. Clinical aspects and problems of diagnosis of peritoneal echinococcosis. *Tunis Med.* 1976;54:753-64. PubMed PMID: 1025814.
- 5 Kosmidis C, Efthimiadis C, Anthimidis G, Vasileiadou K, Koimtzi G, Tzeveleki I, et al. Management of peritoneal hydatid cysts: A forty-year experience. *Heliyon.* 2018;4:e00994. doi: 10.1016/j.heliyon.2018.e00994. PubMed PMID: 30555954; PubMed Central PMCID: PMC6280071.
- 6 Sable S, Mehta J, Yadav S, Jategaokar P, Haldar PJ. Primary omental hydatid cyst: a rare entity. *Case Rep Surg.* 2012;2012:654282. doi: 10.1155/2012/654282. PubMed PMID: 23050190; PubMed Central PMCID: PMC3461611.
- 7 Kumar KS. A Case of Primary Peritoneal Hydatidosis. *Med J Armed Forces India.* 2009;65:278-9. doi: 10.1016/S0377-1237(09)80027-0. PubMed PMID: 27408268; PubMed Central PMCID: PMC4921401.
- 8 Geramizadeh B. Isolated Peritoneal, Mesenteric, and Omental Hydatid Cyst: A Clinicopathologic Narrative Review. *Iran J Med Sci.* 2017;42:517-23. PubMed PMID: 29184259; PubMed Central PMCID: PMC5684372.