

Severe Optic Disc Cupping Following the Methanol Toxicity in a 20-Year-old Man: A Case Report

Narges Hassanpoor, MD, MPH;¹
Mohamadreza Niyousha, MD²

Department of Ophthalmology, School of Medicine, University of Medical Sciences, Tabriz, Iran

Correspondence:

Mohamadreza Niyousha, MD;
Eye Research Center, Nikookari Eye Hospital, Abbasi st., Postal code: 51546-45395, Tabriz, Iran

Tel: +98 9143154300

Fax: +98 41 36577332

Email: mreza63neusha@gmail.com

Received: 21 October 2020

Revised: 19 January 2021

Accepted: 13 March 2021

Abstract

In April 2018, a 20-year-old man with a history of methanol intoxication from an alcoholic drink two years ago, when he was 18 years old, was referred to Nikookari Eye Hospital in Tabriz, Iran. He was admitted to emergency service and underwent eight hours of hemodialysis at the time of poisoning. His past medical history was negative, and he did not take any medication after discharge. The patient had a driving license and never experienced any visual problems before. At presentation, his visual acuity was 160/200 in both eyes with the main complaint of visual field deterioration. Other neurologic exams and brain magnetic resonance imaging (MRI) were reported normal by a neurologist. Optic disc cupping was near total in both eyes with a very narrow remaining rim. Optic disc cupping was very similar to glaucomatous cupping. Intraocular pressure was checked several times via Goldmann tonometry and was 13 mmHg. There was no history of refractive surgery leading to thin cornea. Based on this case, methanol poisoning can mimic glaucomatous optic disc cupping. This is the first case report of methanol toxicity-related optic disc cupping from Iran.

Please cite this article as: Hassanpoor N, Niyousha MR. Severe Optic Disc Cupping Following the Methanol Toxicity in a 20-Year-old Man: A Case Report. *Iran J Med Sci.* 2021;46(5):395-398. doi: 10.30476/IJMS.2021.88370.1914.

Keywords • Poisoning • Methanol • Glaucoma • Optic disc • Cupping

What's Known

- Methanol toxicity can lead to optic disc atrophy. There are few articles for optic disc cupping after methanol poisoning.

What's New

- Methanol toxicity can lead to severe optic disc cupping with good central visual acuity and can mimic normal tension glaucoma. After methanol toxicity, long term follow-ups are needed, as it can progress over time. In patients diagnosed with normal tension glaucoma, a complete history is needed prior to confirming the diagnosis.

Introduction

Methanol poisoning can cause severe vision loss and is usually accidental or after unbranded alcohol intoxication.¹ Vision loss is caused by severe metabolic injury to the optic nerve and retina. Methanol toxicity is a well-known cause of optic neuritis. Patients usually have optic disc swelling in the acute phase of the disease that later leads to optic disc atrophy and pallor.^{2,3} In most patients, methanol toxicity leads to optic disc atrophy and pallor causing central vision loss.³ There are few reports of severe disc cupping with preserved central vision and dense scotoma in the peripheral visual field after methanol toxicity.^{3,4} Herein, we report a case of severe optic disc cupping due to methanol toxicity with preserved central vision and visual field constriction. The importance of this case would be considering methanol toxicity in differential diagnoses of glaucomatous, namely cupping. To the best of our literature review, this is the first reported near-total optic disc cupping with preserved central visual acuity following the methanol toxicity from Iran. Methanol toxicity seems to be more prevalent in Islamic countries and the low socioeconomic

subgroup of people due to ignorance and legal constraints.⁵ Therefore, there are many reported outbreaks of methanol toxicity from Iran.^{5, 6} On the other hand, there are fewer articles regarding their unusual ophthalmic presentations. In the current study, we report an unusual presentation of methanol poisoning in a young man.

Case Presentation

We present the case of a 20-year-old Caucasian man from the northwest of Iran with a history of methanol toxicity due to hand-made alcohol drinking two years ago, when he was 18 years old. He was admitted to emergency service and underwent eight hours of hemodialysis at the time of poisoning. His medical history was negative, and he did not take any medication after discharge. He also denied any history of metals or solvent exposure during these two years. The patient had a driving license just before toxicity with no visual problems before. At the presentation (Nikookari Eye Hospital, April 2018), his visual acuity was 160/200 in both eyes with the main complaint of visual field deterioration. He experienced problems, such difficulty in finding his way and needed someone to guide him. Other neurologic exams and brain MRI were reported normal by a neurologist. In the ophthalmic exam, the anterior segment was normal, and there was no significant refractive

error. The relative afferent pupillary defect was absent. In room light, pupils were dilated about 6 mm, and pupillary reflex was dull in both eyes. Macular reflex was present in both eyes. Optic disc cupping was near total in both eyes with a very narrow remaining rim. Optic disc cupping was very similar to glaucomatous cupping (figure 1). Peripapillary nerve fiber layer thickness was severely reduced on optical coherence tomography (OCT, Heidelberg Engineering) (figure 2). Intraocular pressure was checked several times using Goldmann applanation tonometry (Haag-Streit, USA) equal to 13 mmHg in both eyes. There was no history of refractive surgery leading to a thin cornea and a false low intraocular pressure measurement. Central corneal thickness was 535 μ m. Anterior chamber angle was examined by a glaucoma specialist revealing normal structure. Anterior chamber depth was normal with no iris atrophy, pigment on the lens, or any other sign of previous acute pupillary block attack. Intraocular pressure was checked with an optical response analyzer (ORA, Reichert Ophthalmic Instruments, Depew, NY). The intraocular pressure was 13 mmHg in both eyes based on ORA and Goldmann tonometer. Standard automated perimetry Humphrey 24-2 field test (Zeiss Meditech, model 750, USA) showed dense ring scotoma. The patient was followed up for more than two years with no change in visual acuity, ophthalmic exam, and perimetry. The patient received Brimonidine eye drop twice a day and supplement therapy, for instance, folic acid for maintenance therapy.

Written informed consent was obtained from the patient to publish his clinical data.

Discussion

This patient had a history of methanol toxicity two years before with good central visual acuity and total optic disc cupping, while methanol toxicity resulted in severe optic disc cupping. Normal tension glaucoma was not a suitable suspicion,

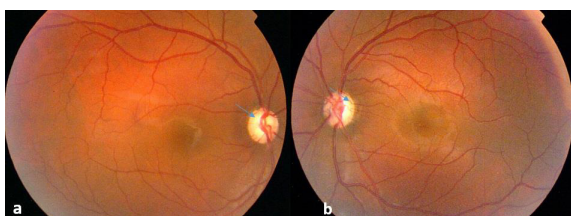


Figure 1: Near total optic disc cupping (but not optic disc atrophy and pallor) in a 20-year-old man right (a) and left (b) eye (blue arrows) is evident due to severe methanol toxicity. The patient had good central vision (160/200) with dense scotoma in peripheral vision that is not typical for methanol toxicity patients.

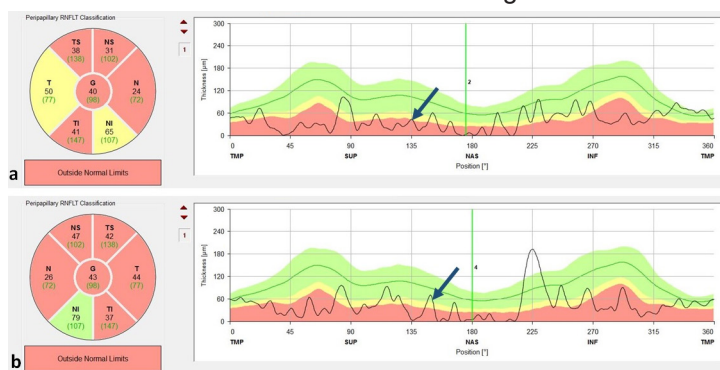


Figure 2: Prepapillary nerve fiber layer thickness (arrow) has significantly decreased in right (a) and left (b) eye, two years after methanol toxicity.

since he was so young for normal tension glaucoma to result in total optic disc cupping. In most patients, methanol toxicity leads to optic disc atrophy and pallor, but optic disc cupping is uncommon.³ In the literature search, there are few reports of severe disc cupping after methanol toxicity.^{2,3}

In a case report by Shin and others, they reported a 30-year-old man with methanol poisoning and severe vision loss. At presentation, he had optic disc swelling and visual acuity was hand motion in both eyes. Four years later the patient returned for re-evaluation with the same visual acuity. Optic disc re-evaluation showed 0.5 cupping on the right eye and 0.9 on the left eye.³ However, in our patient, central visual acuity was preserved with 0.9 symmetric cupping.

In a retrospective study by Galvez-Ruiz and others, in 50 patients with methanol toxicity, 43 eyes with optic disc cupping in the chronic phase of disease were reported. They also mentioned that the older the patients were, the more severe the disc cupping was, along with being highly symmetric in both eyes. Therein, the severity of optic disc cupping was not correlated with putaminal necrosis or neurological signs. Records of two patients revealed progressive optic disc cupping in the period of one month. The higher rate of cupping mentioned in their study may be due to the evaluation of patients with symptomatic chronic visual loss missing milder cases, the presence of prior cupping, and older patients (mean age: 41 years).⁴

Optic disc cupping may happen in some other neuropathies other than glaucoma. It can happen in about 90% of arteritic acute ischemic optic neuropathy (AAION) eyes. However, it is less often in non-arteritic acute ischemic optic neuropathy (NAAION), which may be due to more ischemic assault in arteritic patients. Severe ischemia in AAION leads to both axonal and glial atrophy in the pre-laminar area and causes optic disc cupping. However, in NAAION, less severe ischemia leads to axonal atrophy with remained sufficient glial cells that anatomically replace lost axonal tissue.^{4,7} This may be the same process that happens after the methanol poisoning.⁴ Galvez-Ruiz and others believed that in most patients with methanol poisoning, axonal atrophy is replaced by astrocytes, and there is no cupping after injury, because usually the toxic assault is not enough to lead to astrocyte death, such as NAAION. However, in severe methanol toxicity cases or susceptible patients, there might be severe damage to astrocytes alongside axonal damage that axonal damage cannot be covered and leads to optic disc cupping such as AAION.⁴

Methanol poisoning can mimic glaucomatous optic disc cupping and should be discriminated from normal tension glaucoma. A good past medical history is needed, however, due to religious and cultural issues in several countries, it may be denied by patients. Optic disc cupping can occur in a short time or during the following years of the assault depending on the severity of poisoning, timely treatment, or personal susceptibility. Follow-ups should be conducted following the poisoning for late complications even with good visual acuity. Neuroprotective drugs, such as brimonidine might have a potential protective effect on remaining axonal tissue. We tried to rule out any other possible cause or confounding factor with exact history taking.

Conclusion

Methanol poisoning can lead to optic disc cupping with preserved central visual acuity in severe cases or more susceptible patients mimicking glaucomatous cupping.

Conflict of Interest: None declared.

References

- 1 Kraut JA, Mullins ME. Toxic Alcohols. *N Engl J Med*. 2018;378:270-80. doi: 10.1056/NEJMra1615295. PubMed PMID: 29342392.
- 2 Gouda AS, Khattab AM, Megarbane B. Lessons from a methanol poisoning outbreak in Egypt: Six case reports. *World J Crit Care Med*. 2020;9:54-62. doi: 10.5492/wjccm.v9.i3.54. PubMed PMID: 32844091; PubMed Central PMCID: PMC7416361.
- 3 Shin YW, Uhm KB. A case of optic nerve atrophy with severe disc cupping after methanol poisoning. *Korean J Ophthalmol*. 2011;25:146-50. doi: 10.3341/kjo.2011.25.2.146. PubMed PMID: 21461231; PubMed Central PMCID: PMC3060395.
- 4 Galvez-Ruiz A, Elkhamary SM, Asghar N, Bosley TM. Cupping of the optic disk after methanol poisoning. *Br J Ophthalmol*. 2015;99:1220-3. doi: 10.1136/bjophthalmol-2014-306354. PubMed PMID: 25777817.
- 5 Aghababaeian H, Araghi Ahvazi L, Ostadtaghizadeh A. The Methanol Poisoning Outbreaks in Iran 2018. *Alcohol Alcohol*. 2019;54:128-30. doi: 10.1093/alcal/agz005. PubMed PMID: 30715164.
- 6 Delirrad M, Mohammadi AB. New Methanol Poisoning Outbreaks in Iran Following COVID-19 Pandemic. *Alcohol Alcohol*.

- 2020;55:347-8. doi: 10.1093/alcalc/agaa036. PubMed PMID: 32400874; PubMed Central PMCID: PMC7239215.
- 7 Danesh-Meyer HV, Savino PJ, Sergott RC. The prevalence of cupping in end-stage arteritic and nonarteritic anterior ischemic optic neuropathy. *Ophthalmology*. 2001;108:593-8. doi: 10.1016/s0161-6420(00)00602-3. PubMed PMID: 11237915.