

# Superior Vena Cava Syndrome due to Thrombosis: A Rare Paraneoplastic Presentation of Bronchogenic Carcinoma

Avradip Santra, MD;  
Saumen Nandi, MD;  
Saibal Mondal, MD;  
Subhankar Chakraborty, MD

Department of Pulmonary Medicine,  
Nilratan Sircar Medical College and  
Hospital, Kolkata, India

## Correspondence:

Avradip Santra, MD;  
C/O, Arun Kumar Santra  
15/1, Karar Pukur Lane, P.S. Bantra  
P.O.+Dist. Howrah  
West Bengal, Pin- 711101, India  
Tel: 08013459427  
Email: dravradip@gmail.com  
Received: 20 October 2014  
Revised: 30 November 2014  
Accepted: 04 January 2015

## What's Known

- Superior vena cava (SVC) syndrome usually occurs in the advanced stage of bronchogenic carcinoma, with the clinical presentation being slowly progressive due to a gradually increasing pressure effect by the mass on the SVC.
- Hypercoagulability of blood in a background of malignancy (as a paraneoplastic syndrome) predisposes to venous thromboembolism.

## What's New

- We reported sudden-onset SVC syndrome as a primary manifestation of bronchogenic carcinoma (due to SVC thrombosis) without any evidence of a local mass effect.
- Occurrence in early stage malignancy due to paraneoplastic syndrome (i.e., hypercoagulability of blood).

## Abstract

Superior vena cava (SVC) syndrome is not an uncommon occurrence in patients with malignancy and it is often described as a medical emergency. In majority of the cases, SVC syndrome occurs due to mechanical obstruction of the SVC by extraluminal compression with primary intrathoracic malignancies. However, intraluminal obstruction due to thrombosis can also produce symptoms and signs of SVC syndrome. Clot-related SVC obstruction is mostly associated with indwelling central venous catheter and pacemaker leads, although such thrombosis can occur spontaneously in a background of a hypercoagulable state, e.g., malignancy. Here, an unusual case of sudden onset SVC syndrome has been reported, which on initial radiologic evaluation was found to have a lung nodule without any significant mediastinal mass or adenopathy compressing SVC. Subsequent investigation with Doppler ultrasonography of the neck showed thrombosis in the right internal jugular, right subclavian and right brachiocephalic vein, which was responsible for SVC syndrome. Histopathological evaluation of lung nodule confirmed presence of an adenocarcinoma. Therefore, venous thromboembolism as a paraneoplastic syndrome should be kept in mind while evaluating a case of SVC obstruction in a cancer patient. Management of the underlying disease is of prime importance in such cases and anticoagulation is the mainstay of therapy. Ability to identify paraneoplastic syndrome may have a significant effect on clinical outcome, ranging from early diagnosis to improved quality of life of the patient.

Please cite this article as: Santra A, Nandi S, Mondal S, Chakraborty S. Superior Vena Cava Syndrome due to Thrombosis: A Rare Paraneoplastic Presentation of Bronchogenic Carcinoma. *Iran J Med Sci*. 2016;41(4):354-358.

**Keywords** • Venous thromboembolism • Paraneoplastic syndrome • Superior vena cava syndrome • Bronchogenic carcinoma

## Introduction

Superior vena cava (SVC) syndrome occurs due to mechanical obstruction of blood flow to the right atrium of the heart through SVC. This occurs mostly due to compression or invasion of SVC by mediastinal masses (e.g. tumour, enlarged lymph node) and less commonly due to thrombosis. In a gradually developing SVC syndrome, bronchogenic carcinoma is the commonest cause. Other malignancies like lymphoma, thymoma, and germ cell tumours are frequently responsible for this condition. On the other hand, in an acutely developed SVC syndrome, benign

aetiology should be suspected first. In this current era of medical science, an increase in the use of interventional procedures such as central venous catheter insertion, implantable cardiac defibrillator, and cardiac pacemaker placement has caused a significant rise in the number of SVC syndrome of benign aetiology by predisposing to thrombosis. However, SVC thrombosis may occur in patients with hypercoagulable state like underlying malignancy as a paraneoplastic syndrome. Such association has been mentioned in several case reports as in renal cell carcinoma,<sup>1</sup> uterine carcinosarcoma<sup>2</sup> etc. Here, we report an unusual case of sudden onset SVC syndrome due to thrombosis, which was eventually found out to have bronchogenic carcinoma without any significant SVC compression.

### Case Report

A 55-year-old Southeast Asian male patient, chronic smoker with smoking index of 350, without any significant previous medical history, presented to us with a complaint of sudden onset swelling of face, neck, and anterior part of the chest since 18 days. The swelling was associated with shortness of breath and headache. However, the patient denied any history of cough, haemoptysis, chest pain, or wheeze. There was no history of fever, loss of weight or anorexia, although the patient mentioned about easy fatigability for the similar duration. He was a non-alcoholic and denied any use of illicit drugs. On clinical examination, the patient was found to be afebrile, tachypneic and non-pulsatile venous engorgement was seen over the neck and anterior chest wall with direction of blood flow from above downward. Dilated and tortuous veins were also noted over upper extremities and abdomen (figure 1).

Bilateral conjunctiva was suffused, but no icterus, clubbing, oedema or cyanosis was detected. There was palpable right supraclavicular small but firm lymph node along with bilateral significant axillary lymphadenopathy. The patient was hospitalized with a provisional diagnosis of SVC syndrome and was kept at head end elevated position with oxygen supplementation.

However, unlike to the majority of the cases of SVC syndrome, the chest X-ray (posteroanterior view) did not show any obvious mass lesion, mediastinal widening, or hilar enlargement, which resulted in a diagnostic dilemma regarding aetiology of the current case. Only emphysematous bullous lesion was noted in the right upper lung zone (figure 2).

Routine blood investigations, including complete blood count, plasma glucose, serum electrolytes, renal and liver function test were all within normal range except for mild anaemia (haemoglobin 12.3 gm/dl). HIV status was negative. A contrast enhanced computed tomography (CT) of the thorax and neck was done which showed the presence of a small, moderately enhancing nodular lesion (21×20 mm) with spiculated margin in the apical segment of right upper lobe along with surrounding emphysematous bullae (figure 3).

Multiple marginally enlarged lymph nodes were noted at pretracheal, right paratracheal, subcarinal region and at aortopulmonary window; but once again, the aetiology of SVC syndrome remained undiagnosed as no lymph node or mass was found to compress SVC. An additional small well-defined heterogeneously

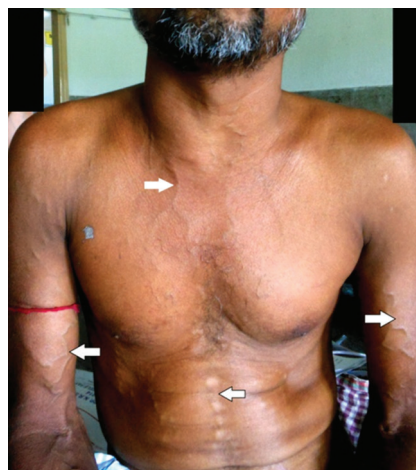

Figure 1: Venous engorgement over neck and anterior chest wall, along with visible dilated veins over upper extremities and abdomen were noted (marked by arrows).

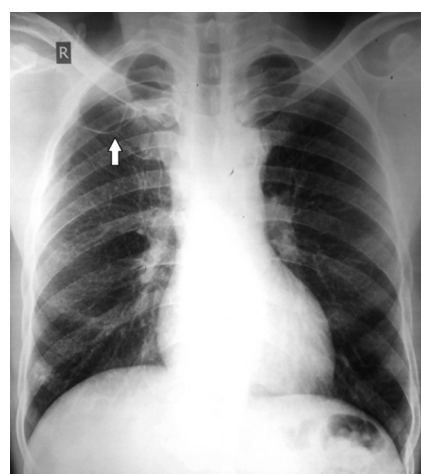
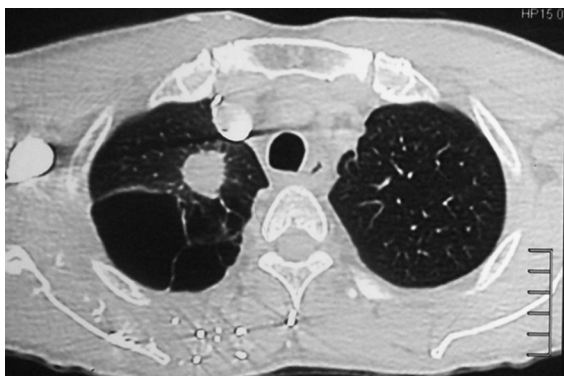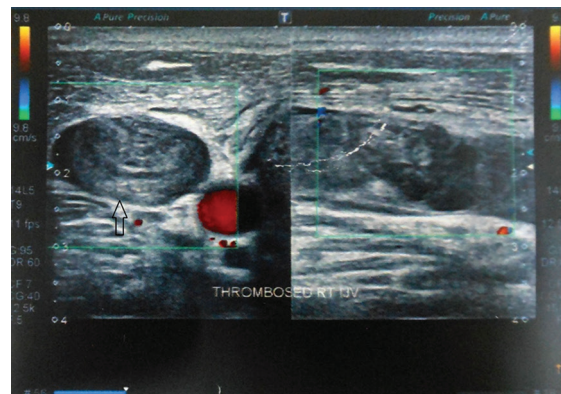


Figure 2: Chest X-ray (PA view) showing emphysematous bullae in the right upper lung zone (marked by arrow) without any visible mass or mediastinal widening.



**Figure 3:** CT thorax (lung window) showing spiculated pulmonary nodule at the right upper lobe along with emphysematous bullae.



**Figure 4:** Doppler ultrasonography of the neck showing thrombosed right internal jugular vein (marked by arrow).

enhancing nodule (26×33 mm) was detected in right lobe of thyroid.

Subsequently, Doppler ultrasonography (USG) of neck was advised to find the cause of SVC syndrome, which revealed intraluminal thrombus in the right internal jugular, right subclavian and visualised extent of right brachiocephalic vein with no significant flow (figure 4)

Superior most part of the right internal jugular vein and right axillary veins were patent showing normal colour uptake. Right external jugular vein was found to be prominent with significant collateralization. Few discrete bilateral cervical lymph nodes with preserved morphology were also detected on USG of neck.

Next, a CT guided trucut biopsy was done from the right upper lobe pulmonary nodule and the histopathological examination confirmed presence of a non-small cell lung cancer (NSCLC) of adenocarcinoma type. Thyroid nodules were also evaluated which showed normal thyroid profile and only nodular hyperplasia in a background of nodular goitre on USG guided fine needle aspiration from the right thyroid lobe nodule.

On review of the history, patient stressed on the mode of onset of the symptoms which was acute in nature, but denied any previous history of venous thrombosis or any drug intake which increases blood coagulability. There was no history of prolonged immobilization or any cardiac procedure or central venous cannulation. Clinical examination did not reveal any feature of deep vein thrombosis (DVT) as well.

Later on, a battery of tests was done to exclude other causes of hypercoagulability of blood. Bleeding time, clotting time, prothrombin time, activated partial thromboplastin time (aPTT) and international normalized ratio (INR) were all normal. Antiphospholipid antibody IgG and IgM were found to be negative by ELISA

method. Other coagulation studies, like factor V Leiden mutation, prothrombin gene mutation, protein C and protein S level did not detect any prior prothrombotic state. Transthoracic 2D echocardiography was normal except for grade I diastolic dysfunction. Other investigations like fiberoptic bronchoscopy and bronchoalveolar lavage were inconclusive. Sputum examination for acid-fast bacilli and malignant cell yielded negative results. Thereby, the patient was finally diagnosed to have SVC syndrome due to thrombosis as a paraneoplastic syndrome in bronchogenic carcinoma.

After consultation with cardiothoracic surgeon and oncologist, the patient was put on systemic corticosteroid, low molecular weight heparin (LMWH) and was subsequently taken up for concurrent chemoradiotherapy. Curative surgery for bronchogenic carcinoma was not considered as excision biopsy from right supraclavicular lymph node showed metastatic deposit (T1bN3M0, stage IIIb). Although only partial improvement was seen initially with the above-mentioned conservative management, stenting of SVC could not be considered due to financial constraint. Currently, he is being treated for bronchogenic carcinoma with chemoradiation under the department of oncology and is on long-term LMWH treatment.

## Discussion

Paraneoplastic syndromes are generally described as hormonal, neurologic, haematologic, or other remote effects of cancer not related to direct invasion, obstruction, or metastatic effect of tumour. This phenomenon is seen in 10-20% of bronchogenic carcinoma patients.<sup>3</sup> The extent of this syndrome is unrelated to the size of the primary tumour and it may precede the diagnosis of malignancy.<sup>4</sup> This scenario partially corroborates our case as SVC

syndrome was the primary presentation in this patient and size of the tumour was even less than three centimetres at diagnosis. Although we could not opt for a curative intent surgery in this patient due to advanced staged bronchogenic carcinoma, but an early suspicion may be helpful to detect a malignancy in its early stage.

At present, the most commonly described paraneoplastic syndromes are attributed to secretion of hormones and functional peptides from the tumour (as happens in endocrine manifestation) or immunological cross-reaction between normal host tissue and tumour (as found in neurologic manifestation).<sup>5</sup> But apart from them, venous thromboembolism (VTE) has also been found frequently in malignancy patients. The incidence of VTE is significantly higher in lung carcinoma patients (around 40-100 cases per 1000 person-years) in comparison to that of the general population (estimated 1-2 cases per 1000 person-years). Unlike most other paraneoplastic manifestations, patients with NSCLC have two-fold higher risk of VTE than small-cell lung cancer (SCLC).<sup>6</sup> Also; it has been found that cases with adenocarcinoma have higher VTE risk than squamous cell carcinoma, which corroborated our case. But in spite of documented evidence of increased thrombosis and pulmonary embolism, a literature search came up with only a few case reports of SVC thrombosis due to paraneoplastic syndrome.

Diagnosis of SVC syndrome is not difficult and can be diagnosed with detailed history and physical examination. Usually SVC syndrome in a background of lung cancer develops gradually over time due to progressive compression of SVC by a slowly enlarging mass or lymph node. However, possibility of thrombotic event should always be kept in mind, particularly when a patient complains of an acute onset event as happened in this patient. For a definitive diagnosis, imaging modalities are essential. Although USG Doppler was helpful in diagnosis of our patient, it has limited capabilities in visualizing central subclavian and brachiocephalic veins. Contrast venography can confirm the diagnosis of SVC syndrome, but venous cannulation may be difficult in setting of obstruction apart from other contrast related complications.<sup>7</sup> Thereby, CT angiography and magnetic resonance angiography are most commonly advised investigations.

Management of SVC syndrome is directed towards the treatment of underlying cause. As majority of the SVC syndrome cases are due to mechanical extraluminal compression, radiotherapy and/or chemotherapy are most commonly advised. Radiotherapy often causes

rapid improvement, even within 72 hours. However, if a patient fails to improve with radiotherapy, underlying SVC thrombosis should be suspected. Moreover, in an unlikely scenario of SVC thrombosis, anticoagulation is the mainstay of treatment. Although the majority of clinicians advise thrombolytic therapy first, followed by parenteral heparin therapy, we opted for a less aggressive management as the patient was mildly symptomatic and had a delayed presentation, i.e., eighteenth day of symptom onset. Quick symptomatic relief can be provided by balloon angioplasty with stenting and that is why it is often considered as a first-line therapy in thrombotic SVC obstruction.<sup>7</sup>

Extended duration LMWH for at least six months is currently the standard of care for treatment of acute DVT and pulmonary embolism in active cancer patients. However, no such specific recommendation can be found to manage paraneoplastic SVC thrombosis. Therefore, we put the patient on a long-term LMWH therapy considering its efficacy in settings of acute DVT; however, the optimal duration of anticoagulation in such patients is not known. Long-term therapy beyond six months can be considered, especially for those with active cancer and/or those receiving anticancer treatments.<sup>8</sup> As per a randomized trial (CLOT study) regarding chemoprophylaxis against recurrent VTE in cancer patients, LMWH (dalteparin) was found to be more effective than an oral anticoagulant without increasing the risk of bleeding.<sup>9</sup> However, another randomized trial compared efficacy of aspirin, warfarin and enoxaparin in preventing VTE in multiple myeloma patients and they concluded that all three drugs are likely to be similarly effective except in elderly cases where warfarin showed lesser efficacy than LMWH.<sup>10</sup>

## Conclusion

SVC syndrome in a lung cancer patient does not necessarily mean an end of the road as it may occur early in the course of the disease where surgical therapy may be an option. In addition, an underlying thrombosis should be looked for in such cases as it may require a long-term anticoagulant therapy apart from chemotherapy and/or radiotherapy.

## Acknowledgment

The authors gratefully acknowledge Dr. Pranab Mondal, Professor and Head of the Department of Pulmonary Medicine, Nilratan Sircar Medical

College, for his excellent contribution and technical support in the management of this case.

**Conflict of Interest:** None declared.

## References

1. May M, Seehafer M, Helke C, Uberruck T, Gunia S, Hoschke B. [Superior vena cava syndrome with bilateral jugular and subclavian vein thrombosis. Paraneoplastic manifestation of renal cell carcinoma]. *Urologe A*. 2003;42:1374-7. doi: 10.1007/s00120-003-0401-9. PubMed PMID: 14569387.
2. Kimura T, Chino M, Ogasawara N, Nakano T, Izumi S, Takeuchi H. Trousseau's syndrome with brachiocephalic vein thrombosis in a patient with uterine carcinosarcoma. A case report. *Angiology*. 1999;50:515-8. doi: 10.1177/000331979905000611. PubMed PMID: 10378829.
3. Silvestri GA, Jett JR. Clinical aspects of lung cancer. In: Mason RJ, Broaddus VC, Martin TR, King TE Jr, Schraufnagel DE, Murray JF, Nadel JA, editors. *Murray and Nadel's Textbook of Respiratory Medicine*. 5th ed. Vol. 2. Philadelphia: Elsevier Saunders; 2010. p. 1116-44.
4. Heinemann S, Zabel P, Hauber H-P. Paraneoplastic syndromes in lung cancer. *Cancer Therapy*. 2008;6:687-98.
5. Pelosof LC, Gerber DE. Paraneoplastic syndromes: an approach to diagnosis and treatment. *Mayo Clin Proc*. 2010;85:838-54. doi: 10.4065/mcp.2010.0099. PubMed PMID: 20810794; PubMed Central PMCID: PMC2931619.
6. Tesselaar ME, Osanto S. Risk of venous thromboembolism in lung cancer. *Curr Opin Pulm Med*. 2007;13:362-7. doi: 10.1097/MCP.0b013e328209413c. PubMed PMID: 17940477.
7. Shaikh I, Berg K, Kman N. Thrombogenic catheter-associated superior vena cava syndrome. *Case Rep Emerg Med*. 2013;2013:793054. doi: 10.1155/2013/793054. PubMed PMID: 24194987; PubMed Central PMCID: PMC3806322.
8. Khorana AA. Cancer-associated thrombosis: updates and controversies. *Hematology Am Soc Hematol Educ Program*. 2012;2012:626-30. doi: 10.1182/asheducation-2012.1.626. PubMed PMID: 23233644.
9. Lee AY, Levine MN, Baker RI, Bowden C, Kakkar AK, Prins M, et al. Low-molecular-weight heparin versus a coumarin for the prevention of recurrent venous thromboembolism in patients with cancer. *N Engl J Med*. 2003;349:146-53. doi: 10.1056/NEJMoa025313. PubMed PMID: 12853587.
10. Palumbo A, Cavo M, Bringhen S, Zamagni E, Romano A, Patriarca F, et al. Aspirin, warfarin, or enoxaparin thromboprophylaxis in patients with multiple myeloma treated with thalidomide: a phase III, open-label, randomized trial. *J Clin Oncol*. 2011;29:986-93. doi: 10.1200/JCO.2010.31.6844. PubMed PMID: 21282540.