

Comparing Adrenaline with Tranexamic Acid to Control Acute Endobronchial Bleeding: A Randomized Controlled Trial

Mitra Samareh Fekri¹, MD;
Seyed Mehdy Hashemi-Bajgani², MD;
Ahmad Shafahi², MD;
Rozita Zarshenas¹, MD

¹Cardiovascular Research Center,
Institute of Basic and Clinical Physiology
Sciences, Kerman University of Medical
Sciences, Kerman, Iran;

²Department of Pulmonary, Afzalipour
Hospital Research Center, Kerman
University of Medical Sciences,
Kerman, Iran

Correspondence:

Rozita Zarshenas, MD;
Cardiovascular Research Center,
Institute of Basic and Clinical
Physiology Sciences, Kerman University
of Medical Sciences, Kerman, Iran

Tel: +98 917 7160355

Fax: +98 341 2264097

Email: rozezarshenas@gmail.com

Received: 02 August 2015

Revised: 18 January 2016

Accepted: 31 January 2016

What's Known

- Oral and intravenous administration of tranexamic acid efficiently controlled bleeding and prevented recurrence.
- The first step to control pulmonary bleeding is instillation of cold saline and adrenaline.

What's New

- Similar to adrenaline, tranexamic acid could successfully control hemoptysis by endobronchial instillation.
- As a first-line drug, treatment of pulmonary bleeding with tranexamic acid fully controlled bleeding without the need for a secondary drug.

Abstract

Background: Hemoptysis occurs due to either pulmonary diseases or bronchoscopy interventions. The aim of the present study was to compare the efficacy of the endobronchial instillation of adrenaline with that of tranexamic acid.

Methods: Fifty patients were randomly selected as 2 double-blinded sample groups (n=25). In these patients, bleeding could not be controlled with cold saline lavage during bronchoscopy and they, therefore, required prescription of another medicine. Adrenaline (1 mg) in one group and tranexamic acid (500 mg) in the other group were diluted in 20 mL of normal saline and instilled through the bronchoscope. This technique was repeated 3 times at 90-second intervals, if necessary. In the case of persistent bleeding, 90 seconds after the last dose, a second medicine was given for bleeding control. Observation of clot through the bronchoscope meant that the bleeding had stopped. The efficacy of tranexamic acid and adrenaline was evaluated and then compared using the Mann–Whitney test.

Results: The time of bleeding control had no significant difference between tranexamic acid and adrenaline (P=0.908). Another analysis was done to evaluate bleeding control with a second medicine; the results showed that 1 (4%) patient in the tranexamic acid and 8 (32%) in the adrenaline group needed the second medicine and there was no significant difference between the 2 groups (P=0.609).

Conclusion: Our results suggested that tranexamic acid by endobronchial instillation was as efficient as adrenaline in controlling hemoptysis and required less frequent use of a second medicine.

Trial Registration Number: IRCT2014120220188

Please cite this article as: Fekri MS, Hashemi-Bajgani SM, Shafahi A, Zarshenas R. Comparing Adrenaline with Tranexamic Acid to Control Acute Endobronchial Bleeding: A Randomized Controlled Trial. *Iran J Med Sci.* 2017;42(2):129-135.

Keywords • Epinephrine • Bronchoscopy • Hemoptysis
• Tranexamic acid

Introduction

Hemoptysis is one of the symptoms of pulmonary diseases such as parenchymal diseases (like infections) and endobronchial lesions (like tumors) as well as vasculitis (like Wegener's disease and anti-glomerular basement membrane disease).¹ Based on its severity, hemoptysis is classified as mild, moderate, and severe. Moderate bleeding is attributed to 50–100 mL/h bleeding in those without any history of pulmonary disease

and 25–50 mL/h in those with an underlying pulmonary disease. Severe hemoptysis is attributed to 100–150 mL/h bleeding in those without a history of pulmonary disease and 50 mL/h bleeding in those with underlying pulmonary problems. In other words, severe hemoptysis can be life-threatening.² The causes of hemoptysis can be iatrogenic or noniatrogenic.³ The most common life-threatening pulmonary bleedings are due to malignancies. According to the previous studies, 5–15% of patients with lung tumors have life-threatening hemoptysis.² Other causes of life-threatening hemoptysis include bronchiectasis, pulmonary tuberculosis, mycetoma, necrotizing pneumonia, and bronchogenic carcinoma.⁴

Bronchoscopy is a technique for observing airways and has 2 applications: 1) diagnostic: evaluating patients with hemoptysis, probable lung cancer, and chronic coughs and observing abnormalities in the airways and bronchoalveolar lavage and 2) therapeutic: removing external objects, blood, and secretions; applying tumor laser therapy; treating bronchial stenosis; and implementing stents for the palliative care of malignancies causing stenosis in the trachea.⁵ An exact diagnosis of lung tumor requires several endobronchial biopsies. The susceptibility of tumors with a necrotic center and vascular tumors to bleeding after the first sampling is a major problem during bronchoscopy.¹ In the recent decade, according to the Spanish national guideline, cold saline lavage and adrenaline instillation on the bleeding site has been done as a treatment for hemoptysis.⁶ Nonetheless, not all patients fully respond to this method of treatment.

The instillation of hemostatic factors such as tranexamic acid on the bleeding site is a new technique that has been investigated recently.¹⁻³ Tranexamic acid is a synthetic antifibrinolytic acid applied for the short-term control of bleeding. It inhibits fibrin degradation and consequently prevents blood loss through binding to plasminogen and plasmin.⁴⁻⁶ In lethal massive hemoptysis, early investigation, including endobronchial adrenaline use, balloon tamponade, and intubation, is necessary for bleeding control. However, rebleeding may start 10–15 minutes after adrenaline is absorbed.⁷ Bronchial artery embolization is the treatment of choice for massive hemoptysis not controlled by another procedure.⁸ The local application of tranexamic acid has been approved in several cases. For example, it has been reported that in patients with malignant mesothelioma, intrapleural tranexamic acid and, during oral surgeries, its oral solution can be used for

controlling blood loss.⁹ This drug can be used for bleeding control following surgery on the heart, liver, and large veins or surgery necessitated by trauma-related bleedings. Furthermore, it has been reported that tranexamic acid can decrease mortality.¹⁰ According to previous studies, oral or intravenous tranexamic acid has been used extensively in the treatment or prevention of mucosal or post-surgical bleedings.

The endobronchial administration of tranexamic acid is a potential therapeutic agent to treat acute pulmonary bleeding; accordingly, it is a safe and useful method before intervention (balloon occlusion or embolization) in patients with uncontrolled hemoptysis.⁶ The present study was designed to compare the efficacy of endobronchial instillation of tranexamic acid with that of adrenaline in controlling acute endobronchial bleeding.

Patients and Methods

The present study was approved by the Ethics Committee of Kerman University of Medical Sciences (K/92/228) and was conducted in the Research Center of Afzalipour Hospital, Kerman, Iran, from 2012 to 2013.

Among 276 patients who met the inclusion criteria for participation in the current study, 226 were excluded because of successful bleeding control with cold saline, cardiovascular disease, bleeding tendency, or anticoagulant and antiplatelet drug consumption. Patients who already had hemoptysis or those who started bleeding after biopsy and could not be controlled with cold saline lavage during bronchoscopy were selected.

First, CBC, PTT, PT, and INR were determined in all the patients. In the bronchoscopy room, after a peripheral venous access was obtained, cardiovascular monitoring, oxygen therapy, local anesthesia of the throat with 2% lidocaine (2 mL in 5 mL of saline), and sedation/anesthesia with an intravenous injection of 2.5 mg of midazolam were performed. During the bronchoscopy procedure, a biopsy specimen was taken through a Pentax bronchoscope (Japan) using type 1 biopsy forceps (size 100–18) (Germany). The same size of bronchoscopes and forceps was used for all the patients. Based on the census method and the random allocation method, the process of patient selection was performed (figure 1). Fifty patients were divided into 2 equal groups of 25. In cases of persistent bleeding, after 90 seconds of cold saline lavage, adrenaline (1 mg diluted in up to 20 mL

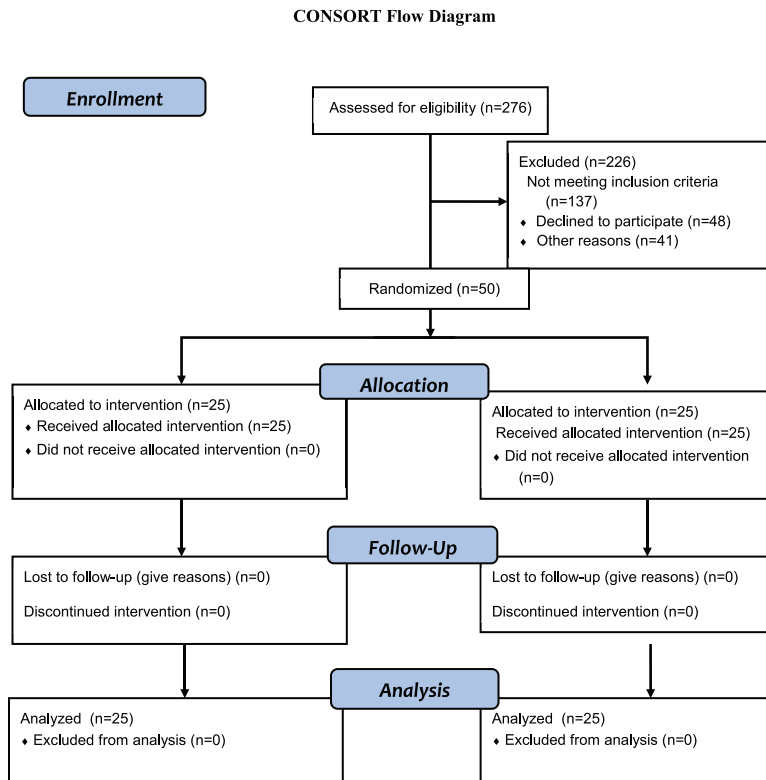


Figure 1: CONSORT 2010 flow diagram is depicted.

of saline) in the first group and tranexamic acid (500 mg diluted in up to 20 mL of saline) in the second group were directly instilled on the bleeding site. If necessary, the medication was repeated 3 times.^{6,9} Ninety seconds after the last dose, in cases of bleeding control failure, crossover with a second medicine was done in order to save the patient's life.⁶

Direct observation of clot through the bronchoscope was considered as bleeding control. In this study, SaO₂ before, during, and after the procedure was measured by using an Oxypleth 520A Pulse Oximeter (USA) in order to ensure that clot did not disturb ventilation. All the patients were followed up for 3 months after the procedure for bleeding recurrence or complications of drugs such as vascular thromboembolism.

In the present study, the data were analyzed with SPSS, version 20, using the chi-square test and the *t* test.

Based on the previous studies such as the one by Márquez-Martín E.⁶ and by considering the maximum sample value in those studies, the percentage of blood loss in the 2 groups was 18.8% and 58.3% with the statistical ability of 80% and reliability of 95% by applying the average comparison of the 2 samples with 28 members ($\alpha=0.0500$, power=0.8000; $N=2(Z_{1-\alpha/2}+Z_{1-\beta})^2 \times \delta^2/D^2$).

Results

The present study recruited 50 patients. In terms of gender, the study population was comprised of 69.4% males and 30.6% females, showing a significant difference ($P=0.032$). The mean age of the patients had no statistically significant difference between the tranexamic acid group (61.47 ± 12.86 y) and the adrenaline group (58.14 ± 17.48 y) ($P=0.589$).

Among the patients, 55.1% were cigarette smokers and 44.9% did not smoke; there was no significant relationship between bleeding control and cigarette smoking ($P=0.256$). Moreover, 38.8% of the study population reported a history of using narcotics, while 61.2% reported no such history; no significant relationship was found between bleeding control and the consumption of narcotics ($P=0.773$) (table 1).

The mean time of bleeding control showed no significant difference between the tranexamic acid group (133.9 ± 77.91 sec) and the adrenaline group (136.66 ± 83.5 sec) ($P=0.908$). There was also no significant difference in regard to the number of injections between the tranexamic acid group (2.08 ± 0.66) and the adrenaline group (1.80 ± 0.74) ($P=0.352$) (table 1).

In the current study, the patients were divided into iatrogenic and noniatrogenic groups based on the cause of bleeding. From

Table 1: Characteristics of the study population according to the type of treatment

	Adrenaline	Tranexamic acid	Total	P value
Sex				
Female	11 (45.8)	4 (16)	15 (30.60)	0.032
Male	14 (54.2)	21 (84)	35 (69.4)	
Opium use				
Yes	10 (41.7)	9 (36)	19 (38.8)	0.773**
No	15 (58.3)	16 (64)	31 (61.2)	
Cigarette smoking				
Yes	11 (45.8)	16 (64)	27 (55.1)	0.256**
No	14 (54.2)	9 (36)	23 (44.9)	
Iatrogenic	14 (56)	13 (52)	27 (54)	0.77**
Noniatrogenic	11 (44)	12 (48)	23 (46)	0.77**
Frequency of injection	1.8±0.74***	2.08±0.66***		0.352*
Time of bleeding control	136.6±83.5***	133.90±77.93***		0.908*

*According to the *t* test; **According to the Chi-square test; ***Mean±SD

the whole study population, 54% had iatrogenic bleeding occurring during bronchoscopic biopsy. According to our data analysis, 52% of the patients with iatrogenic bleeding belonged to the tranexamic acid group and 56% belonged to the adrenaline group, while in the noniatrogenic group, 48% of the patients were in the tranexamic acid group and 44% were in the adrenaline group. These findings showed no significant differences between the 2 study groups with regard to bleeding control in the iatrogenic and noniatrogenic cases ($P=0.77$) (table 1).

Furthermore, all the patients were studied in terms of the relationship between bronchoscopic findings and bleeding control with 2 drugs. The most frequent bronchoscopic findings were respectively endobronchial tumors (16 cases), anthracofibrosis (10 cases), bronchomalacia (4 cases), abnormal mucous (4 cases), and tracheomalacia (1 case). Fifteen patients did not have any abnormal findings on bronchoscopy; in these patients, bronchiectasis, pneumonia, and exacerbation of chronic obstructive lung disease were the most frequent causes of hemoptysis. The data revealed no significant relationship between bronchoscopic findings and bleeding control by tranexamic acid and adrenaline (table 2). In the present study, all the patients underwent pulse oximetry before, during, and after bronchoscopy and in all the cases, mean SaO_2 was $>94\%$.

The number of patients who needed a second drug for bleeding control was 1 (4%) patient in the tranexamic acid group and 8 (32%) patients in the adrenaline group. Although this rate of crossover was lower in the tranexamic acid group, the difference was not significantly different ($P=0.609$) (figure 2).

The patients who received tranexamic acid as the first medicine needed a second medicine

for bleeding control less frequently than did the adrenaline group.

All the patients were followed 3 months later; none of them had bleeding recurrence or complications such as thromboembolism either during hospitalization or after hospital discharge.

Discussion

Pulmonary bleeding is a life-threatening complication resulting from pulmonary diseases or following bronchoscopic therapies and biopsy taking. Bleeding during bronchoscopy may be severe and require serious intervention. Previous studies have emphasized on the oral or intravenous administration of tranexamic acid for bleeding control and preventing bleeding recurrence.⁸ Tranexamic acid is an antifibrinolytic agent and is effective against blood loss in patients with increased fibrinolysis activity after surgery and in patients with a normal hemostatic pathway.¹¹ The use of local hemostatic agents for bleeding control has been recently under controversy.⁸ The results of the present study suggested that the efficiency of tranexamic acid and adrenaline in controlling iatrogenic and noniatrogenic bleedings was the same. Indeed, in most of our patients treated with tranexamic acid, bleeding was adequately controlled without any need for a second drug. According to the previously published statistics, the rate of bleeding after bronchoscopy is 1–20%.¹² The rate of bleeding following biopsy is the same for the malignant and benign tumors of the airways. Vascular, necrotic endobronchial, and other hypervascular tumors, including carcinoid tumors, often tend to have the highest rate of bleeding during bronchoscopy.^{4,12} An endobronchial injection of epinephrine or other vasoactive agents before

Table 2: Bronchoscopic findings in the two groups

	N (%)		Total	P value*
	Adrenaline	Tranexamic acid		
Endobronchial tumor	7 (43.8)	9 (56.2)	16	0.419
Abnormal mucus	3 (75)	1 (25)	4	0.349
Bronchomalacia	3 (75)	1 (25)	4	0.349
Tracheomalacia	1 (100)	0	1	0.490
Anthracofibrosis	7 (70)	3 (30)	10	0.171

*According to the Chi-square test or the Fisher exact test

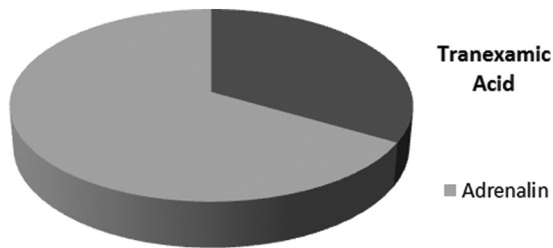


Figure 2: Percentage of medicine crossover between the two groups is depicted.

biopsy may not prove effective.¹² Furthermore, due to systemic absorption and side effects such as vasoconstriction, hypertension, and tachyarrhythmia, the dose of epinephrine and other drugs should be limited.⁸ It was recently reported that tranexamic acid was able to reduce transfusion post cardiovascular surgery; however, seizures and thrombotic events remained side effects of this drug.¹³ Generally, tranexamic acid is tolerated well and has only a few side effects, including digestive side effects (nausea, vomiting, and abdominal pain) following oral consumption and hypotension following rapid intravenous injections.¹⁴ In the present study, the patients tolerated the endobronchial instillation of tranexamic acid well and it was efficient in bleeding control without any side effects. According to a case report, the instillation of tranexamic acid and then its oral administration, following relative response to bronchial artery embolization, in a patient with frequent severe pulmonary bleedings due to cystic fibrosis was able to stop hemoptysis successfully.¹⁵ Hemoptysis in cystic fibrosis is common, and major bleeding aggravates the decline in lung function or may even result in death. Sometimes, embolization fails to stop hemoptysis; therefore, tranexamic acid can assist in stabilizing the patient until lung transplantation.¹⁶ Another case report highlighted the beneficial effect of oral tranexamic acid in preventing hemoptysis recurrence and, indeed, rendering embolization unnecessary in a patient with cystic fibrosis.^{16,17} A study on patients with hemoptysis compared the efficacy of oral tranexamic acid and placebo and reported that

although the result of 1 week's treatment was not different between the 2 groups, bleeding was controlled sooner in the tranexamic acid group.¹⁸ In a similar study designed as a randomized, double-blinded, controlled trial on 46 patients with hemoptysis in 2002, a 1-week treatment with oral tranexamic acid led to no significant difference with the placebo group insofar as the results did not demonstrate that tranexamic acid shortened the duration of hemoptysis after 7 days.¹⁹ A survey reported the use of oral hemostatic agents such as tranexamic acid as an additional palliative therapy for lung cancer hemoptysis.²⁰ All the aforementioned studies investigated the effects of oral or intravenous tranexamic acid, while we studied the effects of the endobronchial instillation of tranexamic acid on the bleeding site. In a study on 2 patients with bleeding due to a pulmonary tumor, one following bronchoscopic biopsy and the other following endoluminal electrocautery, first cold saline and adrenaline were used for bleeding control and then because of failure in bleeding control, 500–1000 mg of endobronchial tranexamic acid was administered. Bleeding was controlled within a few seconds, and the patients were discharged some days later without any side effects or bleeding recurrence.²¹ These results are concordant with those in the current study. Invasive or surgical procedures to control bleeding have more complications.²² Not only can antifibrinolytic agents be used as a temporary treatment before surgery or embolization of the pulmonary artery, but also they can reduce mortality.^{6,23} In one study on patients with hemoptysis treated with endobronchial tranexamic acid for 2 years, malignancies and bronchiectasis were the most common causes of noniatrogenic bleeding and in patients who had responded to tranexamic acid, tumors were the most common cause of bleeding. In that study, almost all the patients with iatrogenic bleeding showed a good response to endobronchial tranexamic acid and the patients who did not respond to the treatment suffered from bronchiectasis.⁶ These findings chime in with our results in as much as tranexamic acid

was as efficient as adrenaline in both groups of our patients with iatrogenic and noniatrogenic bleedings. According to a case report on a patient with severe pulmonary bleeding due to vascular malformation, intrabronchial epinephrine and cold saline lavage failed to control bleeding, while the endobronchial instillation of tranexamic acid was successful in bleeding control.²⁴ As was previously mentioned, in the current study, tranexamic acid was as beneficial as adrenaline in major hemoptysis; however, a larger sample size might have yielded a different result. In 2009, the effects of the endobronchial administration of tranexamic acid on 6 patients with pulmonary bleeding were investigated. Two patients who had bleeding during biopsy were treated with intrabronchial tranexamic acid and the rest of the patients, who had spontaneous hemoptysis, underwent inhalation of tranexamic acid. All the patients showed good responses to the first dose of tranexamic acid without any side effects and the study showed no difference between the inhalation and endobronchial instillation of tranexamic acid in controlling hemoptysis.²⁵ The results of that study were similar to our findings, although we did not investigate the effect of the inhalation of tranexamic acid. Another study used intrabronchial tranexamic acid for bleeding control after taking biopsies from tumors with a high risk of bleeding and reported that the injection of intrabronchial tranexamic acid was safe and useful.¹² More recent studies, albeit with small sample sizes, have also confirmed that local tranexamic acid is effective in hemoptysis.^{1,26} The same results have been observed from the effects of nebulized tranexamic acid in patients with tracheobronchial cancer and massive hemoptysis. In rare cases, seizures and bronchospasm were reported as common adverse effects after nebulized tranexamic acid.²⁷ It is deserving of note that in the present study, only 1 patient needed a second medicine in the group of tranexamic acid, whereas 8 patients in the adrenaline group required a second medicine; the difference, however, did not constitute statistical significance. The absence of discrepancy can be justified by the small sample size, which is the major limitation of the current study.

Conclusion

Hemoptysis is a life-threatening complication. The application of local hemostatic agents has recently received a great deal of attention. The present study, with a sample size larger than that in the previous studies, compared the efficacy of the local instillation of tranexamic

acid with that of adrenaline in bleeding control during bronchoscopy. Our data showed that tranexamic acid was as efficient as adrenaline in controlling pulmonary bleeding. Tranexamic acid had the same efficacy in controlling iatrogenic and noniatrogenic bleedings. Moreover, in the patients treated with tranexamic acid as the first drug, bleeding was controlled without any need for the use of a second drug.

Acknowledgment

The present article was extracted from a thesis written by Rozita Zarshenas and financially supported by Kerman University of Medical Sciences. The authors wish to thank the Clinical Research Center of Afzalipoor Hospital for data analysis. The authors would also like to thank the nurses who participated in this study.

Conflict of Interest: None declared.

References

1. Zamani A. Bronchoscopic intratumoral injection of tranexamic acid: a new technique for control of biopsy-induced bleeding. *Blood Coagul Fibrinolysis*. 2011;22:440-2. doi: 10.1097/MBC.0b013e328346efb7. PubMed PMID: 21577092.
2. Valipour A, Kreuzer A, Koller H, Koessler W, Burghuber OC. Bronchoscopy-guided topical hemostatic tamponade therapy for the management of life-threatening hemoptysis. *Chest*. 2005;127:2113-8. doi: 10.1378/chest.127.6.2113. PubMed PMID: 15947328.
3. Herth F, Ernst A, Becker HD. Long-term outcome and lung cancer incidence in patients with hemoptysis of unknown origin. *Chest*. 2001;120:1592-4. PubMed PMID: 11713139.
4. Sakr L, Dutau H. Massive hemoptysis: an update on the role of bronchoscopy in diagnosis and management. *Respiration*. 2010;80:38-58. doi: 10.1159/000274492. PubMed PMID: 20090288.
5. Lalwani AK. *Current diagnosis & treatment in otolaryngology*. USA: McGraw-Hill Medical; 2008.
6. Marquez-Martin E, Vergara DG, Martin-Juan J, Flacon AR, Lopez-Campos JL, Rodriguez-Panadero F. Endobronchial administration of tranexamic Acid for controlling pulmonary bleeding: a pilot study. *J Bronchology Interv Pulmonol*. 2010;17:122-5. doi: 10.1097/LBR.0b013e3181dc8c17. PubMed PMID: 23168726.

7. Dupree HJ, Lewejohann JC, Gleiss J, Muhl E, Bruch HP. Fiberoptic bronchoscopy of intubated patients with life-threatening hemoptysis. *World J Surg.* 2001;25:104-7. PubMed PMID: 11213148.
8. Lordan JL, Gascoigne A, Corris PA. The pulmonary physician in critical care* Illustrative case 7: Assessment and management of massive haemoptysis. *Thorax.* 2003;58:814-9. PubMed PMID: 12947147; PubMed Central PMCID: PMC1746797.
9. Lawson JH, Murphy MP. Challenges for providing effective hemostasis in surgery and trauma. *Semin Hematol.* 2004;41:55-64. PubMed PMID: 14872423.
10. Cherkas D. Traumatic hemorrhagic shock: advances in fluid management. *Emerg Med Pract.* 2011;13:1-19; quiz -20. PubMed PMID: 22164397.
11. Coats T, Hunt B, Roberts I, Shakur H. Antifibrinolytic agents in traumatic hemorrhage. *MedGenMed.* 2005;7:9. PubMed PMID: 16369314; PubMed Central PMCID: PMC1681427.
12. Zamani A. Bronchoscopic intratumoral injection of tranexamic acid to prevent excessive bleeding during multiple forceps biopsies of lesions with a high risk of bleeding: a prospective case series. *BMC Cancer.* 2014;14:143. doi: 10.1186/1471-2407-14-143. PubMed PMID: 24581173; PubMed Central PMCID: PMC3944730.
13. Esmaealzadeh M, Amini S. The effect of Tranexamic acid on cardiac surgery bleeding. *Reviews in Clinical Medicine.* 2014;1:7-11.
14. Suojanen J, Sorsa T, Salo T. Tranexamic acid can inhibit tongue squamous cell carcinoma invasion in vitro. *Oral Dis.* 2009;15:170-5. doi: 10.1111/j.1601-0825.2008.01507.x. PubMed PMID: 19207486.
15. Graff GR. Treatment of recurrent severe hemoptysis in cystic fibrosis with tranexamic acid. *Respiration.* 2001;68:91-4. doi: 50470. PubMed PMID: 11223738.
16. Barben JU, Ditchfield M, Carlin JB, Robertson CF, Robinson PJ, Olinsky A. Major haemoptysis in children with cystic fibrosis: a 20-year retrospective study. *J Cyst Fibros.* 2003;2:105-11. doi: 10.1016/S1569-1993(03)00066-3. PubMed PMID: 15463858.
17. Hurley M, Bhatt J, Smyth A. Treatment massive haemoptysis in cystic fibrosis with tranexamic acid. *J R Soc Med.* 2011;104 Suppl 1:S49-52. doi: 10.1258/jrsm.2011.s11109. PubMed PMID: 21719894; PubMed Central PMCID: PMC3128162.
18. Moen CA, Burrell A, Dunning J. Does tranexamic acid stop haemoptysis? *Interact Cardiovasc Thorac Surg.* 2013;17:991-4. doi: 10.1093/icvts/ivt383. PubMed PMID: 23966576; PubMed Central PMCID: PMC3829500.
19. Tscheikuna J, Chvaychoo B, Naruman C, Maranetra N. Tranexamic acid in patients with hemoptysis. *J Med Assoc Thai.* 2002;85:399-404. PubMed PMID: 12118485.
20. Ferrell B, Koczywas M, Grannis F, Harrington A. Palliative care in lung cancer. *Surg Clin North Am.* 2011;91:403-17, ix. doi: 10.1016/j.suc.2010.12.003. PubMed PMID: 21419260; PubMed Central PMCID: PMC3655433.
21. De Boer WA, Koolen MG, Roos CM, Ten Cate JW. Tranexamic acid treatment of hemothorax in two patients with malignant mesothelioma. *Chest.* 1991;100:847-8. PubMed PMID: 1889283.
22. Jean-Baptiste E. Clinical assessment and management of massive hemoptysis. *Crit Care Med.* 2001;29:1098. PubMed PMID: 11378596.
23. Prutsky G, Domecq JP, Salazar CA, Accinelli R. Antifibrinolytic therapy to reduce haemoptysis from any cause. *Cochrane Database Syst Rev.* 2012:CD008711. doi: 10.1002/14651858.CD008711.pub2. PubMed PMID: 22513965.
24. Hakanson E, Konstantinov IE, Fransson SG, Svedjeholm R. Management of life-threatening haemoptysis. *Br J Anaesth.* 2002;88:291-5. PubMed PMID: 11878664.
25. Solomonov A, Fruchter O, Zuckerman T, Brenner B, Yigla M. Pulmonary hemorrhage: A novel mode of therapy. *Respir Med.* 2009;103:1196-200. doi: 10.1016/j.rmed.2009.02.004. PubMed PMID: 19251406.
26. Juan JM, Romero BR, Worboys AM, Martín EM, Vergara DG, Arellano E. Evaluación del efecto de la administración endobronquial de ácido tranexámico (atx) en el sangrado de vía aérea. *Rev Esp Patol Torac.* 2014;26:181-8.
27. Hankerson MJ, Raffetto B, Mallon WK, Shoenberger JM. Nebulized Tranexamic Acid as a Noninvasive Therapy for Cancer-Related Hemoptysis. *J Palliat Med.* 2015;18:1060-2. doi: 10.1089/jpm.2015.0167. PubMed PMID: 26381600.