

# Primary Leiomyosarcoma of the Mesentery: A Case Report

Varsha Dalal<sup>1</sup>, MD;  
Manveen Kaur<sup>1</sup>, MD;  
Reetika Menia<sup>1</sup>, MD;  
Fouzia Siraj<sup>1</sup>, DNB;  
Amar Bhatnagar<sup>2</sup>, MD;  
Usha Agrawal<sup>1</sup>, MD

<sup>1</sup>Department of Pathology, National Institute of Pathology, ICMR, New Delhi, India;

<sup>2</sup>Department of Cancer Surgery, VMMC and Safdarjung Hospital, New Delhi, India

## Correspondence:

Usha Agrawal, MD;  
National Institute of Pathology, ICMR,  
Safdarjung Hospital Campus, New Delhi  
110029, India  
**Tel:** +91 931 3753559  
**Email:** uburra@gmail.com  
Received: 01 May 2016  
Revised: 18 June 2016  
Accepted: 13 July 2016

## What's Known

- Mesentery is a frequent recipient of metastases from gastrointestinal, pancreatic, and biliary cancers. Primary tumors are relatively rare and include lymphomas, gastrointestinal stromal tumors, and smooth muscle tumors.
- Majority of mesenchymal mesenteric lesions are benign in nature and usually appear cystic on imaging.

## What's New

- A case of primary leiomyosarcoma of the mesentery with a postoperative complication of colocutaneous fistula is presented.
- The case is being reported for its rarity and unusual clinico-radiological presentation and postoperative course.

## Abstract

Mesenteric masses are infrequent lesions ranging from benign cysts to aggressive malignancies and often present a diagnostic and therapeutic challenge. The mesentery is a frequent recipient of metastases from the gastrointestinal tract, pancreas, and biliary cancers. Primary mesenteric tumors are relatively rare, mostly mesenchymal in origin and benign in nature. Examples include gastrointestinal stromal tumors and smooth muscle tumors. We describe a 50-year-old woman, who presented with a lump in the left hypochondrium along with altered bowel habits of 2 years' duration. Imaging revealed a cystic lesion, raising the differentials of a benign lesion. Exploratory laparotomy revealed a large cystic mass in the mesentery closely abutting the jejunal loops. This was followed by mass resection along with a segment of the jejunum. Histopathological examination revealed features of a leiomyosarcoma. Postoperatively, the patient developed a colocutaneous fistula, which was re-excised. At 6 months' follow-up, the patient is doing well. Our case demonstrates the diagnostic challenge posed by the atypical clinical and imaging features of this tumor at an unusual site.

Please cite this article as: Dalal V, Kaur M, Menia R, Siraj F, Bhatnagar A, Agrawal U. Primary Leiomyosarcoma of the Mesentery: A Case Report. *Iran J Med Sci.* 2017;42(5):505-508.

**Keywords** • Mesentery • Leiomyosarcoma • Gastrointestinal

## Introduction

Leiomyosarcomas are aggressive soft tissue sarcomas derived from smooth muscle cells typically of uterine, gastrointestinal, or soft tissue origin. The clinical, radiological, and histopathological features of leiomyosarcomas are unique for each site of origin.<sup>1</sup> Primary leiomyosarcomas of the mesentery are rare tumors with an aggressive clinical course. An origin from the smooth muscle of blood vessels in the mesentery has been suggested. A majority of these tumors (two-thirds) arise from the small intestinal mesentery, ileum being the most commonly involved site. However, origin from the transverse and sigmoid mesocolon or the gastrohepatic ligament is also possible.<sup>1</sup>

## Case Presentation

A 50-year-old woman presented to the Surgery Outpatient Department of Safdarjung Hospital in June 2015 with an abdominal lump and altered bowel habits of 2 years' duration. The general physical examination was within normal limits, and the vitals were stable. Blood counts, renal function tests, and liver function tests were performed and all the values were within normal limits. Ultrasonography revealed a large round lesion with

central necrotic areas with echogenic periphery in the left hypochondrium. No other abnormality was detected. The uterus, ovaries, and tubes were normal. Bilateral kidneys and ureters were normal. Computed tomography (CT) abdomen revealed a large well-defined cystic lesion on the left side of the mesentery, close to the psoas muscle, with enhancing walls and peripheral, ill-defined, irregular, enhancing solid components. The lesion closely abutted the jejunal loop. Perilesional mesenteric fat stranding was also observed. No evidence of the obstruction of the bowel was noted. No lymphadenopathy or invasion of the adjacent organs was noted (figure 1A). On exploratory laparotomy, there was an encapsulated, bosselated, irregular mass, 15×13×12 cm in size and with restricted mobility. It was seen to be arising from the mesentery in the close vicinity of the jejunum. However, there was no adherence of the mass to the jejunal wall. The mass was excised *in toto* along with an 8-cm segment of the jejunum, and the specimen was sent for histopathology. On gross examination, the tumor measured 14×13×12 cm and weighed 1.2 kg. The cut surface of the mass showed a variegated appearance with solid, cystic areas and regions of hemorrhage and necrosis (figure 1B). The jejunum was grossly unremarkable.

On histopathological examination, the tumor comprised alternating fascicles of spindle cells exhibiting high mitotic activity, marked pleomorphism, and intranuclear inclusions (figure 2A). A large number of bizarre tumor cells and tumor giant cells were also seen. Perivascular accentuation of the tumor cells with areas of hemorrhage and necrosis was seen. Mitotic activity was high, with >10 mitoses/10 high power fields seen. Differential diagnosis included gastrointestinal smooth muscle tumor, leiomyosarcoma, fibrosarcoma, and malignant peripheral nerve sheath tumor. On immunohistochemistry, the tumor cells were positive for vimentin, smooth muscle actin (figure 2B), and desmin and negative for S100, CD117, and CD34. The jejunum and its resection margins were free from tumor.

Full body survey did not reveal any other tumor elsewhere in the body. Hence, a final diagnosis of a primary mesenteric leiomyosarcoma was rendered. The patient was discharged 4 days later and kept on follow-up.

Postoperatively, 1 month later, she reported discharge through port site and fever, suggesting a possible colocutaneous fistula in the anterior abdominal wall. CT scan revealed the narrowing of the bowel segment in the distal descending colon with severe inflammatory changes and an

irregular fistulous tract in the anterior abdominal wall, which appeared to communicate with the skin (figure 3).

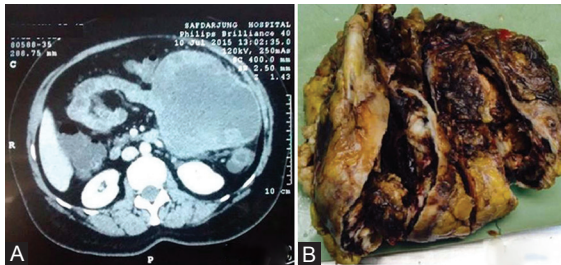
A mass lesion was also observed in the left paravertebral location, which was suspected to be a residual or recurrent tumor. The mass was excised along with the entire fistulous tract and sent for histopathology, which revealed only granulation tissue without any evidence of malignancy. At 6 months' follow-up, the patient is doing well. Written consent was obtained from the patient for reporting the case.

## Discussion

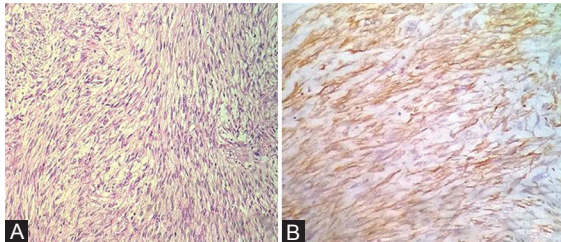
The mesentery presents a common site for the metastasis of gastrointestinal malignancies. However, primary tumors arising from the mesentery are relatively rare, lymphomas being the most common, followed by mesenchymal lesions.<sup>2</sup> The majority of the latter are histologically benign.<sup>3</sup> Malignancies include gastrointestinal stromal tumors (GISTs), leiomyosarcomas, liposarcomas, fibrosarcomas, pleomorphic undifferentiated sarcomas, and hemangiopericytomas.<sup>3</sup> Of these, leiomyosarcomas are the most common type, with a reported incidence of 1:350000, and were first described by Yannopoulos and Stout et al.<sup>3,4</sup>

These tumors primarily affect middle-aged persons and show a female predisposition. The proliferation of the smooth muscle occurring in response to estrogen has been suggested for this observation. Common presenting complaints include a palpable mass, abdominal distention, and pain.<sup>1,2</sup> Infrequently, abscess, acute intraperitoneal hemorrhage, or obstructive ileus may also be the presenting feature. Nonetheless, most of these tumors tend to be asymptomatic and grow to a large size by the time of diagnosis since the mobility and elasticity of the mesentery allow the tumor to occupy a large intraperitoneal space without causing any obstructive symptoms.<sup>2</sup>

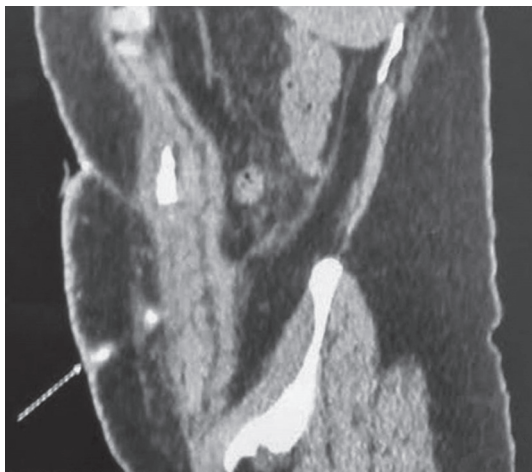Preoperative imaging is of paramount importance in the management of such patients. Both CT and ultrasound contribute toward detection, characterization, and potential surgical planning for mesenteric lesions. On CT, most of the solid masses are neoplastic in nature and cystic ones are typically benign.<sup>5</sup> Our case, however, was entirely cystic in nature, thus raising the differentials of mesenteric cyst, lymphangioma, enteric duplication cyst, and pancreatic pseudocyst. Nevertheless, these benign cystic masses usually have a thin wall and lack solid enhancing components, which



**Figure 1:** A) Computed tomography scan shows a well-defined large cystic lesion on the left side of the mesentery; B) Solid lesion with cystic necrosis.



**Figure 2:** A) Histopathology reveals intersecting fascicles of the tumor cells; B) Immunohistochemistry shows immunoreactivity for smooth muscle actin.



**Figure 3:** Computed tomography scan shows a fistulous tract in the anterior abdominal wall communicating with the skin.

can help discriminate them from GISTs and sarcomas. In the comparison of GISTs and sarcomas, the former tend to be less invasive in appearance.<sup>6</sup> Primary leiomyosarcomas constitute an extremely rare entity; therefore, only a handful of cases have been reported in the literature. Also, percutaneous biopsy is not preferred as it may induce skin metastasis and peritoneal dissemination.<sup>4</sup> A definitive diagnosis based only on preoperative clinico-radiological examination is, thus, difficult.

Gross examination in the present case showed a large, solid cystic, greyish-white tumor with variegated appearance. The morphological picture of a cellular and atypical spindle cell

tumor raised the differentials of GIST, smooth muscle tumor, desmoid tumor, fibrosarcoma, and inflammatory fibroid polyp. The absence of a collagenous and myxoid stroma ruled out a desmoid tumor. Lack of vasculature, inflammatory infiltrates, and the presence of marked atypia and mitoses ruled out inflammatory fibroid polyps.<sup>1</sup> Finally, immunoreactivity for smooth muscle actin and desmin and negativity for CD117 and CD 34 ruled out GISTs.<sup>6</sup> Though the tumor in the present report had numerous mitoses, the presence of even 1 mitosis is sufficient to label an intra-abdominal smooth muscle tumor as a leiomyosarcoma, unlike at other sites.<sup>1,7</sup> Ranchod and Kempson<sup>8</sup> showed the frequency of mitoses to be the most useful indicator of malignant potential. The establishment of an accurate and definite diagnosis of leiomyosarcomas requires histopathological examination, supplemented by immunohistochemistry and gene analysis.<sup>4</sup> The limitation of the present report is that the mutation analysis of c-Kit and PDGFRA could not be done to categorically rule out GISTs.

Site alone is one of the most important prognostic factors in assessing outcome in these tumors.<sup>1</sup> Leiomyosarcomas of the mesentery are associated with an aggressive clinical course. Other factors include size, grade, and mitoses. Our patient was suspected of recurrence due to the development of a colcutaneous fistula. Follow-up surgery, however, did not reveal any residual tumor. Overall, leiomyosarcomas of the bowel mesentery are associated with a poor prognosis. The overall 5-year survival rate for this tumor is only between 20% and 30%, and complete primary surgical resection with negative margins is critical for achieving the best outcome.<sup>4,5</sup> Good chemotherapeutic response is also known for these tumors unlike in GISTs, where targeted molecular therapy with imatinib is the treatment of choice.<sup>8</sup> Definitive guidelines are, however, still unclear, possibly because of the small number of cases reported. Patients should be kept on long-term follow-up.<sup>5</sup>

### Conclusion

Mesenteric masses often pose a diagnostic and therapeutic challenge. There is a paucity of reported cases of mesenteric leiomyosarcomas in the literature. The knowledge of the clinico-radiological and histopathological features of these tumors is, thus, limited and accurate preoperative diagnosis of mesenteric tumors is generally difficult. Our case demonstrates the diagnostic challenge posed by the atypical

clinical, imaging, site, and histological features of a common soft tissue tumor in an old woman.

**Conflict of Interest:** None declared.

## References

1. Weiss SW, Goldblum JR. Leiomyosarcoma. In: Weiss SW, Goldblum JR, editors. *Enzinger and Weiss's Soft Tissue Tumors*. 5th ed. Philadelphia: Mosby; 2008. p. 769-88.
2. Sharma R, Mahajan N, Vij A, Chaudhary UK, Sharma A. Mesenteric Leiomyosarcoma Mistaken as Subserosal Fibroid: A Rare Case Report. 2015;2:8-10.
3. Yannopoulos K, Stout AP. Primary Solid Tumors of the Mesentery. *Cancer*. 1963;16:914-27. PubMed PMID: 14043764.
4. Sidhic AK, Ranjith M, Ali KP, Tej PR. Leiomyosarcoma of the mesentery, a rare mesenteric tumour. *Int J Surg Case Rep*. 2015;7C:58-60. doi: 10.1016/j.ijscr.2014.11.082. PubMed PMID: 25576960; PubMed Central PMCID: PMC4336420.
5. Ezhapilli SR, Moreno CC, Small WC, Hanley K, Kitajima HD, Mittal PK. Mesenteric masses: approach to differential diagnosis at MRI with histopathologic correlation. *J Magn Reson Imaging*. 2014;40:753-69. doi: 10.1002/jmri.24690. PubMed PMID: 25066410.
6. Katz SC, DeMatteo RP. Gastrointestinal stromal tumors and leiomyosarcomas. *J Surg Oncol*. 2008;97:350-9. doi: 10.1002/jso.20970. PubMed PMID: 18286477.
7. Kalogiannidis I, Stavrakis T, Amplianitis I, Grammenou S, Mavromatidis G, Rousso D. Primary mesenteric smooth muscle tumor: an entity with unpredictable biologic behavior. *CaseRepObstetGynecol*. 2013;2013:483689. doi: 10.1155/2013/483689. PubMed PMID: 24062958; PubMed Central PMCID: PMC3766558.
8. Ranchod M, Kempson RL. Smooth muscle tumors of the gastrointestinal tract and retroperitoneum: a pathologic analysis of 100 cases. *Cancer*. 1977;39:255-62. PubMed PMID: 832238.