

Frequency and Distribution of Microscopic Findings in Patients with Chronic Non-Bloody Diarrhea and Normal Colonoscopy

H. Tabrizchie, M.J. Zahedie¹,
M. Hayatbakhsh Abasie¹, E. Jafari,
A. Haghdoost², S.H. Hosseini³

Abstract

Background: Chronic diarrhea is a common problem in patients with symptoms related to gastro-intestinal tract. Some of these patients present with chronic non-bloody, watery diarrhea and no specific clinical, laboratory, or endoscopic findings. The aim of the present study was to investigate the value of histological findings in patients with chronic diarrhea who have normal or non-specific endoscopic findings.

We also determined the frequency and distribution of histological changes related to different anatomical sites in the colon.

Methods: This study was performed in Kerman city on 90 patients with chronic watery diarrhea whose diseases had not been exactly diagnosed after extensive clinical, laboratory, and endoscopic studies.

Laboratory tests including complete blood count, erythrocyte sedimentation rate, C-reactive protein, stool examination, thyroid and liver function tests, and serologic study for celiac disease were all normal in this group of patients. Colonoscopy was performed and mucosal biopsies were taken from recto-sigmoid, descending, and transverse colon.

Results: The histologic findings were as follows: 39 (43.3%) patients showed normal histology, 25 (27.8%) patients showed microscopic colitis, not otherwise specified form. Ten (11.1%) patients had classic lymphocytic colitis, and 15 (16.7%) patients had paucicellular lymphocytic colitis. One (1.1%) patient showed focal active colitis. None of them had collagenous colitis.

Conclusion: Diagnostic histological findings were seen in 28.9% of biopsy samples in patients with chronic diarrhea and normal or near normal endoscopic findings.

We recommend multiple punch biopsy sampling in such patients from different sites of the colon to avoid missing some cases of microscopic colitis.

Iran J Med Sci 2008; 33(2): 101-105.

Keywords • Chronic diarrhea • colonoscopy • microscopic colitis • lymphocytic colitis

Introduction

Chronic diarrhea is one of the most common causes of admitting patients to a gastroenterology clinic.^{1,2} The reported prevalence of chronic diarrhea in a western

Department of Pathology,
¹Gastroenterology, ²Epidemiology and
Biostatistics, ³Clinical Research Center
of Afzalipoor Hospital,
Kerman University of Medical Sciences,
Kerman, Iran.

Correspondence:

Mohammad Javad Zahedie MD,
Department of Gastroenterology,
Afzalipoor Hospital,
Kerman University of Medical Sciences,
Kerman, Iran.

Tel: +98 341 2113025

Fax: +98 341 2113514

Email: Zahedimj@yahoo.com

Submitted: 5 January 2008

Revised: 18 March 2008

Accepted: 9 April 2008

country is 4-5% in the general population and 7-14% in the elderly people.^{2,3}

Chronic diarrhea may be defined as the abnormal passage of three or more loose or liquid stool per day for more than four weeks and/or a daily stool weight greater than 200 gr.^{1,2}

Although the presence of alarming symptoms such as anemia, blood per rectum, and weight loss indicates an organic disease, it is often impossible to make a reliable differentiation between organic and functional diarrhea based solely on history and physical examination.¹

Chronic diarrhea may result from various etiologies. The most common causes are: colonic neoplasia/inflammation, small bowel inflammation, small bowel malabsorption, maldigestion due to pancreatic insufficiency, or motility disorders.²

After taking a detailed history, initial investigation of patients with chronic watery diarrhea should include routine blood test, erythrocyte sedimentation rate (ESR), C-reactive protein (CRP), thyroid function test, liver function test (LFT), stool tests, and serologic tests for celiac disease. Most cases of chronic diarrhea are due to colonic disease, and in the absence of clinical evidence for malabsorption, investigation should focus on the lower gastrointestinal tract. By colonoscopy, direct inspection of mucosa is possible and biopsy samples can be obtained.

Although the importance of biopsy sampling is controversial, it seems to be unavoidable. Even a macroscopically normal mucosa on endoscopy can show abnormalities on biopsy.¹

Histological studies of macroscopically normal colonic mucosa can show specific findings such as Crohn's disease, microscopic colitis, eosinophilic colitis, intestinal spirochetosis, and colitis caused by cytomegalovirus.^{4,5}

Microscopic colitis (MC) is the most common cause of chronic non-bloody diarrhea in patients with a normal colonoscopic picture and an abnormal histopathological finding. MC is an umbrella term that refers to the following subtypes: Classic lymphocytic colitis, collagenous colitis, and atypical histopathological forms including: Paucicellular lymphocytic colitis, MC with giant cells, and MC not otherwise specified (NOS).⁶

The aim of this study was to establish the frequency and distribution of histological changes in different anatomical sites of colon in patients with chronic non-bloody diarrhea who have normal or nearly normal colonoscopic findings.

Patients and Methods

Patients Selection

For all patients admitted to Afzali hospital affiliated to Kerman University of Medical Sciences during September 2005-March 2007

with chronic watery diarrhea, physical examination and laboratory studies were performed to find the cause of diarrhea.

Laboratory studies included complete blood count (CBC), ESR, CRP, blood urea nitrogen, fasting blood sugar (FBS), serum albumin, calcium, triglyceride, cholesterol, three stool examinations, thyroid function tests, LFT, antigliadin IgG, and antiendomysial IgA.

All patients with no specific clinical and laboratory diagnostic findings underwent colonoscopy. After colonoscopic evaluation, 90 patients with normal or near normal endoscopic findings such as erythema and edema were selected for this study. All patients with an alternative explanation for their diarrhea (e.g., infection, hyperthyroidism, celiac sprue, etc.) were excluded.

Multiple tissue samplings from three different anatomical sites of colon; transverse, descending, and recto sigmoid regions were then performed on these 90 patients.

Histopathology

The biopsy samples were fixed in 10% formalin and embedded in paraffin. There after, 3µm sections were prepared from all samples and stained with haematoxylin and eosin, and Masson's trichrome. Immunohistochemical staining of the lymphocytes with CD₄₅ were used for 12 suspected cases to study the number of intraepithelial lymphocytes.

For all the patients, the degree of surface epithelial damage (according to the criteria proposed by Wang et al),⁷ the number of surface intraepithelial lymphocytes, the degree of lamina propria inflammation, the thickness of subepithelial collagen band, crypt architectural distortion, surface erosion, Paneth cell metaplasia, cryptitis, and crypt abscess were studied and recorded.

Measurement of the subepithelial collagen band was done with an optical micrometer and intraepithelial lymphocytes (IEL) were counted on well oriented biopsy samples (sections perpendicular to the normal surface).

The number of surface IEL was estimated by counting the number of lymphocytes per 100 intercryptal epithelial cells.

At least five non-contiguous intercryptal space, excluding areas over lymphoid follicles were examined and the mean number of IEL was expressed per 100 epithelial nuclei. Mucosal biopsies from all three segments of the colon mentioned above were examined and the patients were divided into five groups:

1. Patients with normal histology (according to McKenna's criteria).^{8,9}
2. Patients with classic lymphocytic colitis diagnosed based on:

a. Increased chronic inflammatory cells in lamina propria beyond what would be expected physiologically in the corresponding anatomical sites. The normal physiologic inflammatory infiltrate is characteristically most pronounced in the upper third of the mucosa, with the highest concentration beneath the surface epithelium. In general, a progressive decrease in lamina propria cellularity is noted as one moves from right to left colon.¹⁰

b. Increased number of intraepithelial lymphocytes (IEL>20/100).

c. Damage of the surface epithelium.

3. Patients with paucicellular lymphocytic colitis:

The distinctive histologic features that separated paucicellular lymphocytic colitis from classic lymphocytic colitis were patchiness and a lower density of surface IELs in paucicellular lymphocytic colitis (according to criteria proposed by Goldstein & Bhanot).¹¹

4. Patients with microscopic colitis, not otherwise specified (MC, NOS): characterized by increased chronic inflammatory infiltration in the lamina propria and minimal regenerating changes.¹¹

5. Patients with focal active colitis (FAC).

FAC is described as focal neutrophilic infiltration of colonic crypts. It may consist of one focus in a single biopsy or multiple foci.⁸

Statistical Analysis

Data were expressed as means, medians, and proportions. Results were compared by using the Student's *t* test, Mann-Whitney, Chi-Square, one way ANOVA, or Kruskal-Wallis tests. SPSS software version 15 was used for statistical analyses and 95% confidence intervals were computed.

Results

The age range of the 90 patients was 13 to 59 years, with a mean age of 31.57 ± 1.16 years. Of them, 38 (42.2%) patients were female and 52 (57.8%) patients were male.

The chief complaint of all 90 patients was chronic diarrhea, which in 80 (88.9%) patients it was intermittent.

Colonoscopy results were normal in 48 (53.3%) and were non-specific (erythema and edema) in 42 (46.7%) patients. The mean numbers of biopsy samples from rectosigmoid, descending, and transverse colon were 3 (range 1-6 tissue fragments), 3 (range 1-5 tissue fragments), and 2 (range 1-5 tissue fragments), respectively.

Of the 90 patients with chronic diarrhea, 39 (43.3%) presented normal histology. Of the remaining 51 (56.7%) patients with abnormal

histology, 10 (11.1%) presented typical histological features of lymphocytic colitis (figures 1,2), 15 (16.7%) showed features of paucicellular lymphocytic colitis, 25 (27.8%) patients showed microscopic colitis not otherwise specified and only one (1.1%) patient showed evidence of focal active colitis (table 1).

The mean age of 10 patients with classic lymphocytic colitis was 28.10 ± 10.84 years (range 18-55). The female to male ratio was 1/1. Clinically, all patients with classic lymphocytic colitis had intermittent diarrhea. Of these patients, nine patients had abdominal pain. Symptom duration in this group was 2 years.

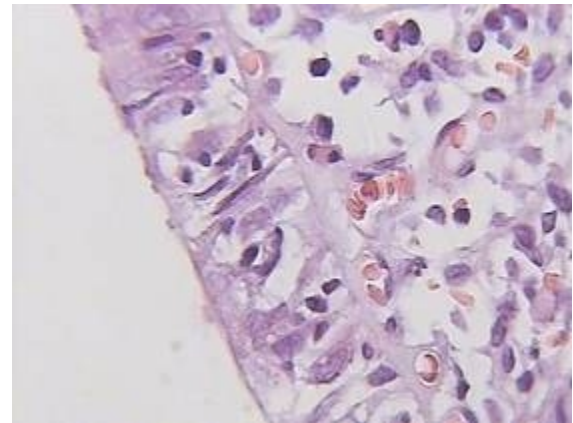


Figure 1: Lymphocytic colitis. Increased intraepithelial lymphocytes and mild surface epithelial damage as goblet cell depletion (grade 1). (H&E $\times 400$)

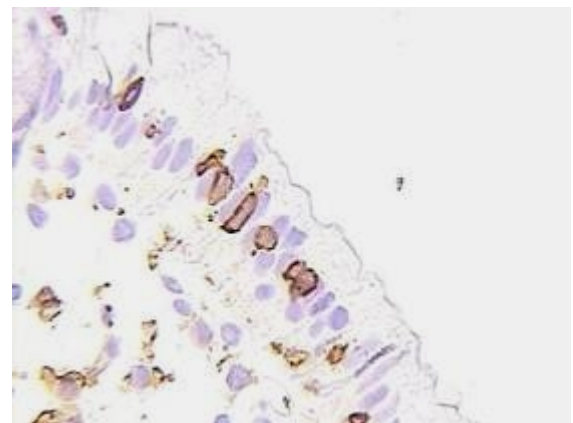


Figure 2: Lymphocytic colitis. Intraepithelial lymphocytes show positive membranous reaction while surface epithelial cells show negative reaction. (Immunohistochemical staining with CD₄₅, $\times 400$)

Histopathology

In classic lymphocytic colitis, the mean surface IEL scores in rectosigmoid, descending, and transverse colon were 18, 23, and 31, respectively. The corresponding values for paucicellular lymphocytic colitis were 9, 15, and 19, respectively.

The mean surface IEL scores for paucicellular and classic lymphocytic colitis groups

Table 1: Distribution and frequency of histopathological findings with demographic variation.

Histological finding	Frequency	Percent	Sex		Mean of Age	SD
			Male	Female		
Normal appearance	39	43.3	20	19	33.44	11.70
Microscopic colitis, NOS	25	27.8	18	7	31.40	10.80
Classic lymphocytic colitis	10	11.1	5	5	28.10	10.84
Paucicellular lymphocytic colitis	15	16.7	9	6	29.84	10.26
Focal active colitis	1	1.1	0	1	23	—
Total	90	100	38	52	31.57	1.16

SD: Standard deviation, NOS: not otherwise specified

showed significant decrease from transverse colon to rectosigmoid ($P < 0.05$).

As it is shown in table 2, the best anatomical site for evaluation of intraepithelial lymphocytes in this study was the transverse colon.

Discussion

Based on our results, histologic findings of possible diagnostic value were observed in 28.9% of patients with chronic diarrhea and normal colonoscopy. Histologic findings of unquestionable diagnostic importance were found in 11 (12.2%) patients.

In the literature, the percentage of patients with diarrhea in whom a histological diagnosis could be made despite a normal endoscopy ranges from 15 to 40%.¹

In our study, chronic inflammation in lamina propria without definite criteria for lymphocytic colitis and collagenous colitis was found in 25 patients. For this group, the term "microscopic colitis, not otherwise specified" was used.^{4,6,11} There is, however, controversy on the diagnostic significance of these patients.

In our study, we found that 11.1% of the patients had microscopic colitis. This rate in other studies was 12.5 % in Turkey,¹² 13% in Netherlands,¹³ and 9.5% in Spain.¹⁴

None of the patients in this study had collagenous colitis. This finding is similar to some other reports.^{12,15,16} In most articles, collagenous colitis was more common in women with a mean age ≥ 65 yr. In our study, the mean age of patients was 31.57 (range 13-59

years) and 57.8% of our patients were men. The incidence of collagenous colitis in Asia is unknown.³ In this study sampling from cecum and ascending colon was not done. This limitation of sampling can affect the frequency of collagenous colitis and lymphocytic colitis.

In our study, the mean of symptom duration in patients with lymphocytic colitis was 24 months, which is similar to the findings reported by Nobakht et al and Levent et al.^{12,16}

Fifteen (16.7%) patients in our study showed some histological features of lymphocytic colitis but did not fulfill the histological criteria of lymphocytic colitis. According to Goldstein and Bhanot, this condition was called "paucicellular" lymphocytic colitis.¹¹ They found the same clinicopathologic associations in patients with paucicellular lymphocytic colitis and classic lymphocytic colitis. So they suggested that paucicellular lymphocytic colitis should be included in the morphologic spectrum of lymphocytic colitis, although others do not agree with this concept.¹⁷

According to table 2, if only rectosigmoid and descending colon had been examined, the diagnosis would not have been made in 2 (20%) patients with classic lymphocytic colitis. This finding shows the importance of sampling from transverse colon. As mentioned previously, in this study biopsy from cecum and ascending colon were not performed.

Importance of colonoscopy or rectosigmoidoscopy with biopsies in patients with chronic non-bloody, watery diarrhea remain controversial.

We recommend multiple punch biopsy from

Table 2: Distribution of age, sex, histopathologic findings in 10 patients with classic lymphocytic colitis

Patient's No.	Age	sex	No. of lymphocytes in 100 surface epithelial cells			Grade of surface epithelial injury*		
			Rectosigmoid	Descending	Transverse	Rectosigmoid	Descending	Transverse
1	22	F	15	22	40	1	1	2
2	55	F	17	25	22	2	2	2
3	24	M	17	12	22	1	0	1
4	35	M	25	32	48	2	1	2
5	32	M	15	16	22	2	1	1
6	24	F	20	25	40	1	1	1
7	24	M	14	32	20	1	1	1
8	18	F	22	20	50	1	1	2
9	28	M	20	25	30	1	1	2
10	19	F	18	20	22	1	1	1

*Grading injury: 0= Normal epithelial, 1⁺= Mucous depletion only, 2⁺= Cuboidal epithelial (columnar cell-shape loss) & mucin depletion, 3⁺= Flattened epithelial plus mucin depletion.

different sites of colon in patients with chronic watery diarrhea and normal or near normal endoscopic findings to evaluate the possible microscopic colitis.

We also recommend transverse colon samples to be carefully studied quantitatively for intraepithelial lymphocytes and grading for surface epithelial damage is performed.

Also, in selected patients, immunostaining with CD₄₅ can help for reliable count of intraepithelial lymphocytes.

Conflict of Interest: None declared

References

- 1 Müller M, Willén R, Stotzer PO. Colonoscopy and SeHCAT for investigation of chronic diarrhea. *Digestion* 2004; 69: 211-8.
- 2 Thomas PD, Forbes A, Green J, et al. Guidelines for the investigation of chronic diarrhea, 2nd edition. *Gut* 2003; 52: V1-15.
- 3 Nyhlin N, Bohr J, Eriksson S, Tysk C. Systematic review: microscopic colitis. *Aliment Pharmacol Ther* 2006; 23: 1525-34.
- 4 da Silva JG, De Brito T, Cintra Damião AO, et al. Histologic study of colonic mucosa in patients with chronic diarrhea and normal colonoscopic findings. *J Clin Gastroenterology* 2006; 40: 44-8.
- 5 Shah RJ, Fenoglio-Preiser C, Bleau BL, Giannella RA. Usefulness of colonoscopy with biopsy in the evaluation of patients with chronic diarrhea. *Am J Gastroenterol* 2001; 96: 1091.
- 6 Liszka U, Woszczyk D, Pajak J. Histopathological diagnosis of microscopic colitis. *J Gastroenterology and Hepatology* 2006; 21: 792-7.
- 7 Wang N, Dumot JA, Achkar E, et al. Colonic epithelial lymphocytosis without a thickened subepithelial collagen table: a clinicopathologic study of 40 cases supporting a heterogeneous entity. *Am J Surg Pathol* 1999; 23: 1068-74.
- 8 McKenna BJ. Is it really colitis? Dealing with the nearly normal colonic biopsy and variations of microscopic colitis. *Pathol Case Rev* 2004; 9: 106-14.
- 9 Montgomery EA. Lippincott Williams & Wilkins, Biopsy interpretation of the gastrointestinal tract mucosa. 2006. p. 213-54.
- 10 Tsang P, Rotterdam H. Biopsy diagnosis of colitis: Possibilities and pitfalls. *Am J Surg Pathol* 1999; 23: 423-30.
- 11 Goldstein NS, Bhanot P. Paucicellular and asymptomatic lymphocytic colitis: expanding the clinicopathologic spectrum of lymphocytic colitis. *Am J Clin Pathol* 2004; 122: 405-11.
- 12 Levent E, Sadik Y, Onat A, et al. Proportion of lymphocytic colitis cases in patients with unexplained diarrhea: The result of a prospective study. *Turkish J Gastroenterology* 2000; 11.
- 13 Thijs WJ, van Baarlen J, Kleibeuker JH, Kolkman JJ. Microscopic colitis: Prevalence and distribution throughout the colon in patients with colonic diarrhoea. *Neth J Med* 2005; 63: 137-40.
- 14 Fernández-Bañares F, Salas A, Forné M, et al. Incidence of collagenous and lymphocytic colitis: a 5-year population-based. *Am J Gastroenterology* 1999; 94: 418-23.
- 15 Tunçer C, Cindoruk M, Dursun A, Karakan T. Prevalence of microscopic colitis in patients with symptoms suggesting irritable bowel syndrome. *Acta Gastroenterol Belg* 2003; 66: 133-6.
- 16 Nobakht H, Ansari R, Tavangar M, et al. Cause of nonbloody chronic diarrhea in patients with normal colonoscopy. *Scientific Journal Kurdistan University of Medical Sciences* 83; 31: 17-25.
- 17 Robert ME. Microscopic colitis, pathologic consideration, changing dogma. *J Clin Gastroenterol* 2004; 38: S18-26.