

# The Effectiveness of Modified Vertical Dome Division Technique in Reducing Nasal Tip Projection in Rhinoplasty

Behrooz Gandomi<sup>1</sup>,  
Mohammad Hossein Arzaghi<sup>1</sup>,  
Mohammad Rafatbakhsh<sup>2</sup>

## Abstract

**Background:** The technique of vertical dome division or tip defining, involves incising the lateral crura and vestibular skin at or lateral to the dome or tip defining point. The incision divides the lower lateral cartilage into a lateral segment and a medial segment, which are advanced anteriorly and sutured together to increase tip projection. The present study aimed at assessing a new vertical dome division, which is a modified version of vertical dome technique to decrease nasal tip projection, and increase or decrease nasal tip rotation and other tip deformities.

**Methods:** The medical files of patients undergone rhinoplasty from 2003 to 2008 were retrospectively analyzed. The files were selected from a computerized rhinoplasty database of patients, who had been operated using a modified vertical dome technique and followed-up for one year or more after the surgery.

**Results:** A total of 3756 patients were operated. Complications related to the nasal tip such as bossae, bifidity, persistent tip projection or tip asymmetry was seen in 81 patients (2.1%). Revisions for tip-related problems were performed in 42 patients (1.1%).

**Conclusions:** The findings suggest that the modified vertical dome technique is an effective method for nasal tip deprojection and narrowing via an open approach. The length of follow-up and the large sample size support effectiveness of the technique.

**Iran J Med Sci 2011; 36(3): 196-200.**

**Keywords** • Vertical dome division • rhinoplasty • nasal cartilage • modified technique

## Introduction

Successful surgical control of the nasal tip is considered the most difficult step in rhinoplasty. Nasal tip repositioning techniques are used to modify the existing alar cartilages, and to augment the nasal lobule with grafts or implants. The overprojected nasal tip, commonly called the Pinocchio- or Cyrano de Bergerac-type nose, is a relatively unusual deformity. Nasal tip projection is defined as the distance that the nasal tip extends anterior to the facial plane.<sup>1,2</sup> The degree of tip projection is important to exclude factors that may cause an illusion of overprojected nasal tip such as a deep naso-frontal angle, marked dorsal saddling, retrodisplaced chin, or short upper lip.<sup>1,3</sup> The next step in evaluating an overprojected nasal

<sup>1</sup>Departments of Otolaryngology, Shiraz University of Medical Sciences, Shiraz, Iran.

<sup>2</sup>English Language, Shiraz University of Medical Sciences, Shiraz, Iran.

### Correspondence:

Behrooz Gandomi MD,  
Department of Otolaryngology, Khalili  
Hospital, Khalili street, Shiraz, Iran.

**Tel/Fax:** +98 711 6471478

**Email:** gandomib@sums.ac.ir

Received: 20 June 2010

Revised: 27 February 2011

Accepted: 6 March 2011

tip is to properly analyze the anatomic factors that contribute to the development of such a deformity.<sup>4</sup>

The medial and lateral crura make up two cartilaginous arches, which anatomically support the nasal tip. This is achieved through the length and strength of the medial and lateral crura.<sup>2-5</sup> The ligamentous attachment of the medial crural footplates to the caudal end of the septal cartilage, the fibrous connections between the upper and lower lateral cartilages, and the interdomal ligament, which spans over the anterior septal angle, support the projection of the nasal tip.<sup>2-5</sup> Vertical division of the alar cartilage, which is mostly used for alteration of the nasal tip projection in cosmetic and reconstructive rhinoplasty, is a useful adjunctive procedure for nasal tip refinement. The classic Goldman procedure might give rise to tip irregularities including lower nasal third pinching, alar notching, and a characteristically-pointed, or "tent pole" nasal tip,<sup>6-9</sup> particularly in patients who are thin-skinned.

The classic Goldman technique, which is also called Vertical Dome, or Tip Defining, involves incising the lateral crura and vestibular skin at or lateral to the dome or tip defining point. This incision divides the lower lateral cartilage into medial and lateral segments. The medial segments are then advanced anteriorly and sutured together to increase tip projection. In this method no attempt is made to reconstruct the alar rim.<sup>9</sup> Lipsett,<sup>10</sup> advocated the division of the alar cartilage medially from the angle, with posterior advancement of the anterior segment to retrodisplace the nasal tip to avoid incision in the dome region. In some techniques the location of the vertical incision along the lower lateral cartilage is changed to alter nasal tip projection.<sup>10</sup>

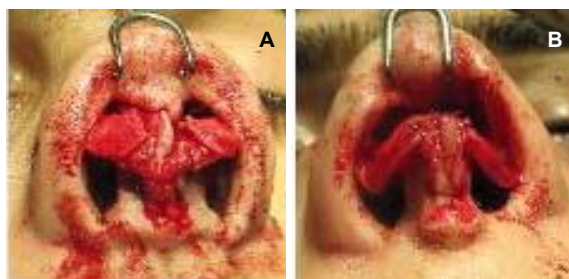
## Materials and Methods

The study is a retrospective analysis of the records of patients who underwent rhinoplasty in Dastgheib Hospital, Shiraz, Iran from 2003 to 2008. Patients were selected from a computerized rhinoplasty database of operated cases. The

database contains information regarding patients' demography, preoperative analyses, operative techniques, and postoperative outcomes and complications. The medical records of all patients had been entered into the database without previous intention to include them in this study. All patients had been operated using the new modified vertical dome division technique, and all had been followed-up for one year or more after surgery.

The employed technique is a new modification of previous techniques.<sup>3-10</sup> The technique employs an open approach in which a strong columellar strut is inserted and a portion of crura is removed near the dome (the cornerstone of our new technique of tip surgery). Depending on the deformity, this segment may involve intermediate, middle or lateral crura with or without removal of vestibular skin considering its thickness: thin skins are not resected, but thick skins are usually removed. Cut edges of cartilages are sutured with 6-0 or 5-0 nylon sutures (figures 1-A and 1-B).

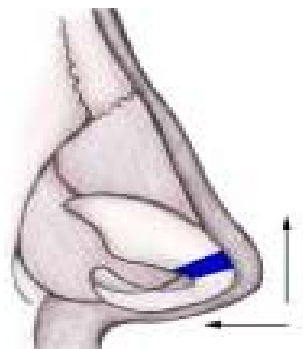
Our technique involves the overlapping of the incised edges of the medial and lateral segments, and suture approximation to restore the integrity of the alar cartilage. The technique allows a more stable configuration for the maintenance of nasal tip support. The overlapping and reapproximation of the medial and lateral units ensure the long-term stability of the newly-reconstructed nasal tip complex, and reduce the tendency towards postoperative cartilaginous abnormalities that may accompany scar fibrosis and contracture. Vertical dome division (VDD) technique includes tip retrodisplacement, alteration of tip rotation, correction of a hanging infratip lobule, narrowing a wide domal arch, correction of tip asymmetries, and correction of an elongated infratip lobule. Patients with marked over-projection can be eligible candidates for tip retrodisplacement, applying VDD. Conservative cut-back can also be used for retrodisplacement in the lateral crural hinge area and the medial crural feet in some patients. The medial and lateral components are overlapped to achieve the VDD retrodisplacement requirement. This method is not proper for increasing tip projection



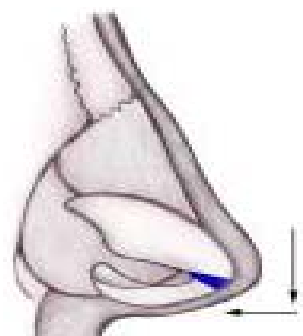
**Figure 1:** (A) Intraoperative view with cut ends of the lower lateral cartilage before suture (B) Intraoperative view with suturing of cut ends of the lower lateral cartilage.

as it involves shortening of medial crura and overlapping of components of the lower lateral cartilage, and hence reducing the anterior projection of the alar cartilage. Patients suffering from tip overprojection have elongated lobules comparing with their nostrils and columellar length on the basis of the analyses of their nasal bases. The length of the lobule should equal one-third of the nasal base, while the nostril and columellar portion should measure two-thirds of the nasal base. Shortening of the lobule as well as retrodisplacing the tip in these particular individuals can be made by vertical dome division medial to the dome with overlapping of the interior part of the medial crus.<sup>4,11</sup>

One of the applications of VDD is the alteration of nasal tip rotation. Another increasing rotation technique involves the resection of the cephalic edge of the lateral crura and cutting back of the lateral crural hinge area as well as the judicious trimming of the caudal septum. This manoeuvre increases the nasolabial angle, and consequently there will be an increase in nasal tip rotation (figure 2). When VDD procedure is applied to decrease nasal tip rotation, a portion of the medial crura of lower lateral cartilage is removed simultaneously resulting in an obvious decrease in nasal tip rotation due to a loss in tip projection (figure 3).

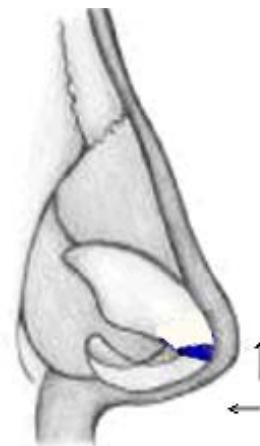


**Figure 2:** Removing a strip of cartilage from the lateral crura near the dome increases tip rotation and also decreases projection to a lesser degree.



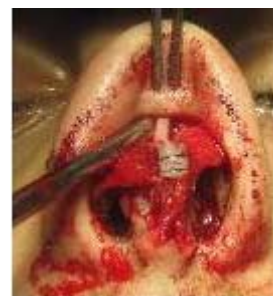**Figure 3:** Removing a strip of cartilage from the medial crura near the dome mostly decreases tip rotation and to a lesser degree decreases tip projection.

The appearance of a wide, amorphous nasal tip is characterized by a wide domal arch of the lower lateral cartilage. The domal arch is the angular configuration made by merging the medial and lateral crura between the area of the dome and angle. Therefore, it is named the intermediate crus. A wide arch moves the dome and angle of the lower alar cartilage far from each other and brings about the loss of the tip definition. Removing a strip of cartilage from the intermediate crura (dome) to a lesser degree increases tip rotation and decreases tip projection (figure 4).



**Figure 4:** Removing a strip of cartilage from the intermediate crura to a lesser degree increases tip rotation and decreases tip projection.

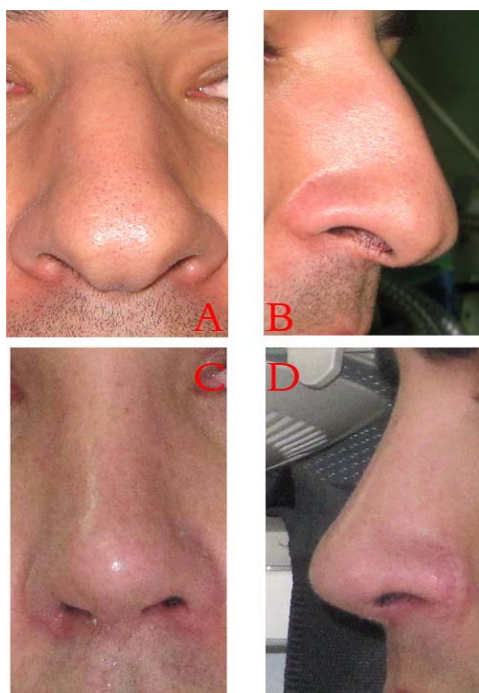We did narrow the new tip area as much as possible by removing cartilage from the cephalic part of LLC and inserted a tip graft in most patients (figure 5). Duration of our study was long enough to detect even delayed complications (figure 6).



**Figure 5:** Using the tip graft helps to minimize tip bifidity.

## Results

A retrospective review was carried out for all patients who underwent new modification VDD at lower lateral cartilage as part of a rhinoplasty procedure performed by the first author. The patients (n=3756) who underwent open rhinoplasty



**Figure 6:** A patient with tip deformities before (A&B) and after (C&D) correction, using new modification of vertical dome division.

were included in the study from Oct 2003 to Sep 2008. There were 2862 women and 894 men. The patients mean age was 24.9 years (range: 16-58 years). The mean clinical follow up duration was 3.8 years (range: 1-7 years). Forty two cases (1.1%) underwent revision.

Outcome measures consisted of blind assessment of postoperative photographs by two of the authors. The postoperative photographs were examined for specific factors including overall nasal tip projection and rotation, tip symmetry, columellar position and length, and the assessment of the presence of bossae or alar retraction.

Fifty two patients had widening of tip (tip bifidity). Tip bifidity was the result of removal of the narrowest segment of lower lateral cartilage (LLC) and reconstruction of and the dome with a wider segment. The extent of deformity in 30 patients was mild and thus acceptable to patients, therefore, they did not volunteer for revision surgery, but the remaining 22 patients asked for revision surgery to correct the deformity. Bossa formation was noted in three patients and revisions were performed for all of them.

Inefficient correction of tip projection was detected in five cases; all of whom underwent revision surgery for further correction. Asymmetry of tip was found in 21 patients, and the most underlying causes were deficiency of tip sutures and inaccuracy in achieving symmetrical shaping of the two lower lateral cartilages. From

these patients, 12 needed revision surgery due to severity of the deformity.

## Discussion

The overdeveloped LLCs can be surgically altered in the overprojected nose to improve nasal balance and to deproject the nose. Various surgical maneuvers to modify the LLCs can be categorized into techniques that alter the lateral or medial crura, or the ones that involve dome division. Tip rotation results from nose deprojection which is, in turn, caused by shortening of the lateral crus. The procedure to effectively control the retrodisplacement of the tip is the lateral crural flap technique, which is also supported by Webster.<sup>12</sup> Instead of completely removing the cephalic portion of the lateral crus delineated by a rim strip incision, Webster preserved a portion of the cartilage as a lateral crural flap to provide better stability for the rim strip. Either telescoping the rim strip with flap or excising a small portion of the flap to create a void into which the LLC would telescope can affect retrodisplacement. Kridel and Konior,<sup>13</sup> later introduced a lateral crural overlay technique. In this technique the lateral crus was cut vertically at its middle portion. Then the cut ends were overlapped and sutured to shorten the total length of the lateral crus.<sup>11</sup>

Other procedures such as medial crura shortening techniques have also been employed for deprojection. Lipsett,<sup>10</sup> advocated splitting the LLC medial to the dome, resecting a length of the cartilage just lateral to the incision, and reshaping the lateral crus remnant, using multiple scoring incisions on the cartilage to recreate a new dome. This was performed using a rim incision and a cartilage delivery technique. Other experts have made some modifications in the Lipsett's technique. For example, they preserved the underlying vestibular skin, delivered the cartilage with a marginal incision and morselized the cartilage. The excision of medial crura foot pods to deproject the nasal tip was also suggested by Guyuron and colleagues.<sup>6</sup>

The lateral and medial crura need to be equally shortened in order to deproject the nasal tip without altering tip rotation. Joseph and Safian,<sup>15</sup> favored excising the lateral and medial crura elements to achieve deprojection. Close, et al,<sup>16</sup> removed a calculated length of the medial and lateral crura. The remnants would be sutured together end to end. Later, medial and lateral crura overlay and suturing techniques were combined by Foda et al,<sup>17</sup> for deprojection.

Vertical Dome Division is a versatile mean of nasal tip alteration. The hockey-stick,<sup>11</sup> approach is a technique among the vertical division techniques, which includes the Goldman procedure and the Simon's modification. We believe our technique is suitable for three main objectives: (1) nasal tip deprojection, (2) increasing tip rotation, and (3) decreasing tip rotation especially in revision cases with over-rotated tips. In fact, by changing the site of cartilage removal, we can achieve different goals depending on the deformity.

The most frequent complication of our technique is widening of the tip since the dome area is the narrowest part of the lower lateral cartilage removed in this technique. This area, in fact, is replaced by a much wider part of LLC. Reasonably, this causes widening of tip area. To avoid this, we did narrow the new tip area as much as possible by removing cartilage from the cephalic part of LLC and inserted a tip graft in most patients. Using the tip graft helps to minimize this complication, define the tip area, and camouflage suture knots and visible cartilage cut ends, which are the second most common complications of this technique especially in thin-skinned patients. No other major complications were observed in our patients.

## Conclusion

Overprojected and broad nasal tips require deprojecting maneuvers to reestablish proportional harmony to the nose. Our technique is suitable to reduce the excessively-long components of the LLC while reshaping the tip appropriately.

**Conflict of Interest:** None declared

## References

- 1 Crumley RL, Lanser M. Quantitative analysis of nasal tip projection. *Laryngoscope* 1988; 98: 202-8.
- 2 Anderson JR. A reasoned approach to nasal base surgery. *Arch Otolaryngol* 1984; 110: 349-58.
- 3 Kridel RW, Konior RJ. Dome truncation for management of the overprojected nasal tip. *Ann Plast Surg* 1990; 24: 385-96.
- 4 Foda HM. Alar setback technique: a controlled method of nasal tip deprojection. *Arch Otolaryngol Head Neck Surg* 2001; 127: 1341-6.
- 5 Janeke JB, Wright WK. Studies on the support of the nasal tip. *Arch Otolaryngol* 1971; 93: 458-64.
- 6 Guyvron B. Footplates of the medial crura. *Plast Reconstr Surg* 1998; 101: 1359-63.
- 7 McCurdy JA Jr. Surgery of the nasal tip: current concepts. *Ear Nose Throat J* 1977; 56: 238-48.
- 8 McCollough EG. Surgery of nasal tip. *Otolaryngol clin north Am* 1987; 20: 769-84.
- 9 Adamson PA, McGraw-Wall BL, Morrow TA, Constantinides MS. Vertical Dome Division in Open Rhinoplasty, An update on indications, techniques, and results. *Arch Otolaryngol Head Neck Surg* 1994; 120: 373-80.
- 10 Lipsett EM. A new approach to surgery of the lower cartilaginous vault. *AMA Arch Otolaryngol* 1959; 70: 42-7.
- 11 Chang CW, Simons RL. Hockey-Stick Vertical Dome Division Technique for Overprojected and Broad Nasal Tips. *Arch Facial Plast Surg* 2008; 10: 88-92.
- 12 Webster RC, Smith RC. Lateral crural retrodisplacement for superior rotation of the tip in rhinoplasty. *Aesthetic Plast Surg* 1979; 3: 65-78.
- 13 Kridel RW, Konior RJ. Controlled nasal tip rotation via the lateral crural overlay technique. *Arch Otolaryngol Head Neck Surg* 1991; 117: 411-5.
- 14 Tobias GW. Modified universal tiplasty: closed structure rhinoplasty as it pertains to the overprojected and the broad tip. *Facial Plast Surg* 1994; 10: 389-98.
- 15 Safian J. The split-cartilage tip technique of rhinoplasty. *Plast Reconstr Surg* 1970; 45: 217-20.
- 16 Close LG, Schaefer SD, Schultz BA. The over-projecting nasal tip: precise reduction without rotation. *Laryngoscope* 1987; 97: 931-6.
- 17 Foda HMT, Kridel RW. Lateral crural steal and lateral crural overlay: an objective evaluation. *Arch Otolaryngol Head Neck Surg* 1999; 125: 1365-70.