

Experimental Treatment of a Suspected Case of Mycetoma Based on Dot-in-Circle Sign

Dear Editor,

Mycetoma is a chronic indolent, slowly progressive granulomatous infection which eventually causes bone destruction.¹ Its diagnosis is difficult until the advanced stage, which is characterized by sinus formation, discharge of dark-colored grains, extensive soft tissue, and bone damage with deformity often necessitating amputation. Although biopsy and microbiological culture provide definitive diagnosis, these are difficult to achieve consistently.² Early diagnosis and prompt treatment can significantly limit disability and avoid amputation. MRI (magnetic resonance imaging) features of mycetoma are characteristic, especially the dot-in-circle sign, which allow early and confident diagnosis when typical clinical features such as sinuses and grains are not manifested or histopathological diagnosis and aspiration cytology are negative or indeterminate.

A 30-year-old man from India visited the orthopedic clinic in Doha (Qatar) complaining of painless, progressive soft tissue swelling of the great toe since 2 years. He had been treated with multiple courses of oral and broad-spectrum intravenous antibiotics over 9 months before being referred to our hospital. Histopathological evaluation done prior to his visit to the clinic demonstrated inflammatory process with chronic abscess formation without growth of any organism, which had been treated for osteomyelitis. X-ray of the left foot demonstrated peripheral cortical erosions, periosteal thickening, sclerosis, and multiple lytic lesions involving the proximal phalanx of the great toe. MRI of the foot with contrast was performed which revealed soft tissue thickening of the left great toe, mainly around the proximal phalanx. The proximal phalanx showed abnormal marrow, which was heterogeneous low signal on T1-weighted images and heterogeneous bright signal on T2-weighted images. Mild edema was noted in adjacent first metatarsal and distal phalanx of the great toe. The classic dot-in-circle sign was seen, which is a specific appearance on T2-weighted images showing small rounded hyperintensity surrounded by a low signal intensity rim with a hypointense dot in the center (figure 1). The post-contrast MRI study with

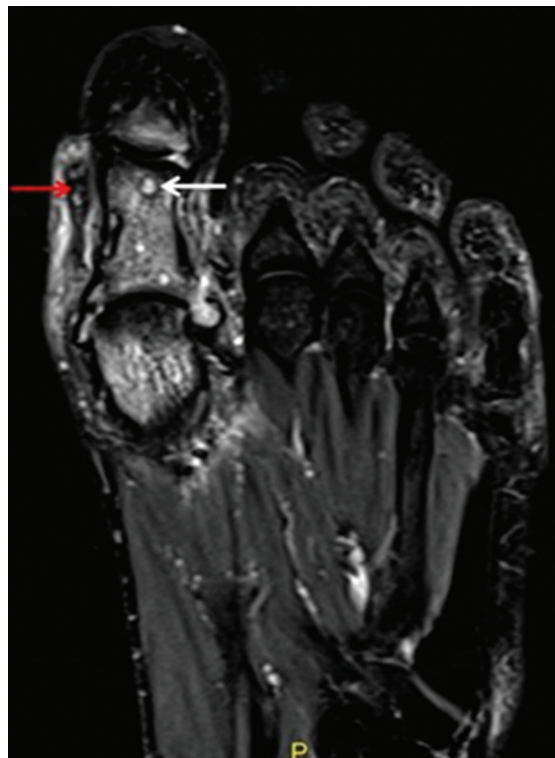


Figure 1: Non-contrast fat-saturated T2-weighted coronal MRI of the foot showing discrete as well as conglomerate small rounded lesions in intraosseous marrow. It also shows soft tissue with peripheral hypointense rim (white arrow) and central hypointense focus (red arrow), which suggests dot-in-circle sign. Also, note the marrow edema involving the phalanges of the great toe and head of the first metatarsal.

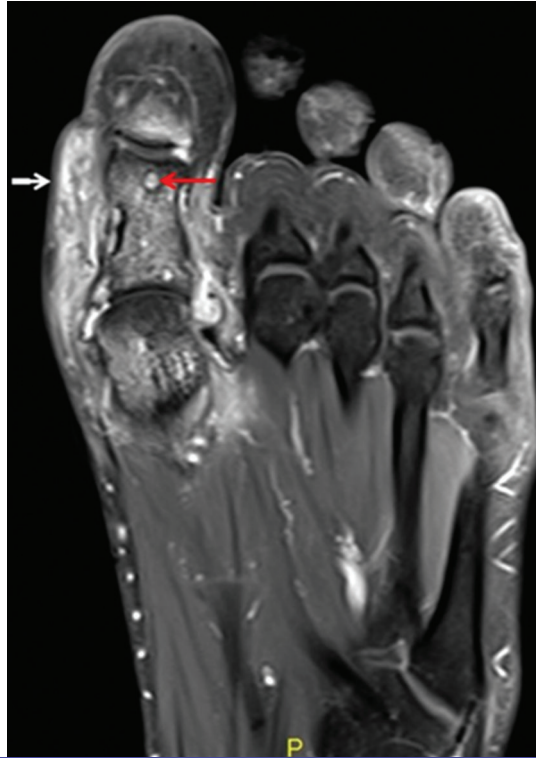


Figure 2: The post-contrast T1-weighted fat-saturated coronal image of the foot showing significant enhancement of soft tissue (white arrow) and mycetoma grains (red arrow).

gadolinium injection showed enhancement of the soft tissue with multiple discrete and conglomerate enhancing ring lesions in subcutaneous tissue and intraosseous location (figure 2). Treatment was started with two cycles of intravenous amikacin 15 mg/kg for 3 weeks in combination with trimethoprim-sulfamethoxazole (7 and 35 mg/kg/day) for a period of 6 months. Follow-up of the patient was done until one year with significant improvement. Written informed consent was obtained for the publication of this interesting case.

The dot-in-circle sign is described as a classic appearance on T2-weighted MRI, which shows small rounded hyperintensity due to the inflammatory granuloma surrounded by low signal intensity represented by fibrous matrix and central hypodense dot due to fungal elements.²⁻⁴ The central low signal on T2-weighted images is assumed to be due to susceptibility artefacts from the fungal elements.⁵ Based on our experience, characteristic MRI features are more important in case presentation like ours where there are no discharging grains.

Conflict of Interest: None declared.

Please cite this article as: Nepal P, Alam SI, Adhikari N, Ghimire N, Ojili V, Yousefi A. Experimental Treatment of a Suspected Case of Mycetoma Based on Dot-in-Circle Sign. *Iran J Med Sci.* 2018;43(5):564-566.

Pankaj Nepal¹, MD; Saeed Intakhab Alam², MD; Narendra Adhikari², MBBS; Neeta Ghimire³, MDS; Vijayanadh Ojili⁴, MD; Arash Yousefi¹, MD

¹Metropolitan hospital Center, NY, USA; ²Hamad Medical Corporation, Doha, Qatar; ³Parco HealthCare, Doha, Qatar; ⁴University of Texas Health, San-Antonio, Texas, USA

Correspondence:

Pankaj Nepal, MD;
Metropolitan Hospital Center, 10029, NY, USA
Tel: +1 21 55843245
Email: pankaj-123@live.com
Received: 27 December 2017
Revised: 25 February 2018
Accepted: 11 March 2018

References

- 1) Fahal AH, Hassan MA. Mycetoma. Br J Surg. 1992;79:1138-41. PubMed PMID: 1467883.
- 2) Neelakantan S, Babu AA, Anandarajan R. 'Dot in circle sign': a characteristic finding in ultrasound and MR imaging of soft tissue mycetomas. BMJ Case Rep. 2016;2016. doi: 10.1136/bcr-2016-216502. PubMed PMID: 27702932; PubMed Central PMCID: PMC5073639.
- 3) Sarris I, Berendt AR, Athanasous N, Ostlere SJ, group Ocs. MRI of mycetoma of the foot: two cases demonstrating the dot-in-circle sign. Skeletal Radiol. 2003;32:179-83. doi: 10.1007/s00256-002-0600-2. PubMed PMID: 12605286.
- 4) Cherian RS, Betty M, Manipadam MT, Cherian VM, Poonnoose PM, Oommen AT, et al. The "dot-in-circle" sign -- a characteristic MRI finding in mycetoma foot: a report of three cases. Br J Radiol. 2009;82:662-5. doi: 10.1259/bjr/62386689. PubMed PMID: 19221181.
- 5) Sen A, Pillay RS. Case report: Dot-in-circle sign - An MRI and USG sign for "Madura foot". Indian J Radiol Imaging. 2011;21:264-6. doi: 10.4103/0971-3026.90684. PubMed PMID: 22223936; PubMed Central PMCID: PMC3249939.