

# Disseminated Abdominal Cystic Echinococcosis After Blunt Abdominal Trauma: A Case Report

Bolatbek Bimendeevich Baimakhanov<sup>1,2</sup>, PhD; Majid Fasihi Harandi<sup>3,4</sup>, PhD; Shokan Akhmetbekovich Kaniyev<sup>5</sup>, PhD; Gulziya Nurtazayevna Ismailova<sup>5,6</sup>, PhD candidate; Erik Kumarbekovich Nurlanbayev<sup>7</sup>, PhD candidate; Chingiz Takhirovich Sadykov<sup>5</sup>, MD; Gulziba Muratkyzy<sup>8</sup>, MD

<sup>1</sup>Chairman of the Board of JSC Syzganov National Scientific Center of Surgery, Almaty, Kazakhstan;

<sup>2</sup>Academician of the National Academy of Sciences, Almaty, Kazakhstan;

<sup>3</sup>Research Center for Hydatid Disease in Iran, Kerman University of Medical Sciences, Kerman, Iran;

<sup>4</sup>Department of Medical Parasitology, School of Medicine, Kerman University of Medical Sciences, Kerman, Iran;

<sup>5</sup>Department of JSC Syzganov National Scientific Center of Surgery, Almaty, Kazakhstan;

<sup>6</sup>Al-Farabi Kazakh National University, Almaty, Kazakhstan;

<sup>7</sup>Department of General Surgery of JSC Syzganov National Scientific Center of Surgery, Almaty, Kazakhstan;

<sup>8</sup>Kazakh National Medical University named after S.D. Asfendiyrov, Almaty, Kazakhstan

## Correspondence:

Gulziya Nurtazayevna Ismailova, PhD candidate;  
Department of JSC Syzganov National Scientific Center of Surgery, Zheltoksan str. 51, Postal code: 050000, Almaty, Kazakhstan  
Tel: +7 72 72792240  
Email: dr.ismailova@mail.ru  
Received: 03 May 2024  
Revised: 20 June 2024  
Accepted: 12 July 2024

## What's Known

- Anaphylactic shock occurs when a hydatid cyst ruptures intra-abdominally, as a reaction to a massive release of allergens from the cyst into the abdominal cavity and/or bile ducts.

## What's New

- The first reported clinical case of intra-abdominal rupture of a hydatid cyst was in an athlete during intensive sports training as a consequence of sports injury, which was not accompanied by anaphylactic shock. Diagnosis of disseminated intra-abdominal echinococcosis in the long-term period following sports injuries must be differentiated from tuberculosis of the mesenteric lymph nodes and acute appendicitis.

## Abstract

Rupture of a hydatid cyst can lead to the development of a disseminated form of intra-abdominal cystic echinococcosis if not diagnosed and treated promptly. Anaphylactic shock is a definite indication of cyst rupture.

The presented clinical case was a young athlete with a disseminated form of cystic echinococcosis, which was investigated in 2023 at the Syzganov National Scientific Center for Surgery of Kazakhstan. The disease developed gradually following a sports injury to the abdomen during sports training and was accompanied by blurred signs of anaphylactic shock. In the next 2 years, echinococcosis of the abdominal cavity was asymptomatic. The clinical manifestation of cystic echinococcosis developed gradually over the last 10-12 weeks, in the form of dull, painful abdominal pain, malaise, weakness, sweating, nausea, poor appetite, and weight loss. Subacute manifestations of the disease resembled those of acute appendicitis.

A diagnostic laparotomy revealed an abundance of cystic formations in the abdominal cavity, necessitating a differential diagnosis between a disseminated form of abdominal tuberculosis with damage to the mesenteric lymph nodes. However, instrumental verification of the parasite, together with the morphological exclusion of the extrapulmonary form of tuberculosis, made it possible to establish a disseminated form of cystic echinococcosis. The patient underwent a cystectomy, was discharged in satisfactory condition, and was informed about the possibility of disease recurrence. In conclusion, in hyperendemic zones, it is recommended to carry out immunological testing for echinococcosis on all abdominal sports injuries, independent of the presence of anaphylactic shock symptoms.

Please cite this article as: Baimakhanov BB, Harandi MF, Kaniyev SA, Ismailova GN, Nurlanbayev EK, Sadykov CT, Muratkyzy G. Disseminated Abdominal Cystic Echinococcosis After Blunt Abdominal Trauma: A Case Report. Iran J Med Sci. 2024;49(11):741-747. doi: 10.30476/ijms.2024.102545.3553.

**Keywords** • Echinococcosis • Hepatic hydatid cyst • Mesenteric cyst • Rupture • Abdomen

## Introduction

Cystic echinococcosis (CE), caused by the larval tapeworm *Echinococcus granulosus*, is a zoonotic infection that affects both humans and livestock. Echinococcosis is endemic in Central Asian countries with extensive livestock farming systems. Clinical symptoms of hepatic CE include abdominal pain caused by hepatomegaly and tension of the fibrous capsule of the liver due to expansion, or suppuration of the hydatid cyst. Ultrasound and immunological tests are used to diagnose CE. However, rupture

of liver hydatid cysts is one of the most prevalent complications leading to the dissemination of the disease.<sup>1-3</sup>

The rupture of the hepatic hydatid cyst might be spontaneous or caused by trauma. As it is known, in case of the cyst rupture, the contents of a viable hydatid cyst are highly transmissible, and there will be seeding with tens of thousands of protoscoleces, leading to disseminated hydatid cysts in the abdominal cavity.<sup>4-6</sup> The present study described a patient with disseminated abdominal CE following blunt abdominal trauma after sports exercise.

## Case Presentation

A 17-year-old boy was admitted to the emergency room of the Syzganov National Scientific Center for Surgery, with complaints of dull aching pain in the abdomen, enlarged abdominal volume, increased body temperature, nausea, lack of appetite, and weight loss. According to the patient, complaints began to bother him 6 months ago. The patient, as a college student for the last 4 years, has been trained in freestyle wrestling at a youth school. He was from Arys City (Turkestan), formerly South Kazakhstan region, which is a highly endemic region for cystic echinococcosis in southern Kazakhstan. He received a blunt abdominal injury during a sports sparring match around 2 years ago; as his sports partner fell on him, he experienced pain in the abdomen, combined with dizziness, weakness, and malaise. The symptoms of the injury to the abdomen were relieved by taking painkillers, and anti-inflammatory medications. There was no full medical examination, and after a week, the patient's health condition improved, and he resumed his usual sports activities.

The patient's condition began to deteriorate about 10-12 weeks ago, with complaints of weakness, malaise, sweating, lack of appetite, nausea, and weight loss. Following abdominal pain, he went to the emergency room of a local hospital in Arys City. He was suspected of having acute appendicitis. A diagnostic laparotomy was conducted, and an examination of the abdominal cavity revealed multiple lesions in the abdominal cavity with cysts of various sizes, turbid contents, and total mesenteric lymphadenitis. An intraoperative collection of histopathological samples was performed, suspected of having tuberculous lesions of the mesenteric lymph nodes.

The patient underwent anti-inflammatory and detoxification therapy. He received intramuscular (IM) gentamicin sulfate 4%-80 mg (Solution, Santo Plant, Kazakhstan) every

12 hours, for 7 days. In addition, intravenous (IV) metronidazole 5%-100 mL (Solution, Kelun-Kazpharm, Kazakhstan) was administered three times a day, for 7 days. The following medications were also administered three times per day for 7 days; IV administration of NaCl 0.9%-300 mL (Solution, Kelun-Kazpharm, Kazakhstan), IV administration of dextrose 5%-200 mL (Solution, Biosintez, Russia), and oral administration of Ibuprofen 400 mg (Tablet, Viva Pharm, Kazakhstan).

After antibacterial therapy, the patient was admitted to the Adolescent and Children's Department of the Children's Tuberculosis Clinic due to a suspected case of extrapulmonary tuberculosis, even though a recombinant tuberculosis allergen test (immunological skin test Diaskintest®, JSC Lecco, Russia) was negative.

As a patient with the diagnosis of active-stage, drug-sensitive tuberculosis of the mesenteric lymph nodes and peritoneum, the patient began receiving specific chemotherapy: isoniazid (H), (Pavlodar Pharmaceutical Plant LLP, Kazakhstan); rifampicin (R), (Pharmasyntez Group of Companies, Russia); pyrazinamide (Z), (Pharm Company ROMAT LLP, Kazakhstan); ethambutol (E), (Pharmasyntez Group of Companies, Russia), for abdominal tuberculosis. However, the patient's condition rapidly deteriorated. The results of imaging studies were contradictory. Ultrasound did not reliably visualize the organs of the abdominal cavity and small pelvis, due to multiple anechoic cavity formations from 0.6 cm to 3.0 cm.

However, computed tomography (CT) of the abdominal cavity and pelvis revealed large two-chamber cystic formations with band-like inclusions (parasitic etiology), as well as polycystic changes in the abdominal cavity, and pelvis with multiple areas of effusion accumulation, which were restricted by adhesive changes. Multiple cavitory changes in the form of polycystic lesions were observed from the level of the diaphragm to the pelvic floor with the largest size of two adjacent cysts of the abdominal cavity with the probability of communication 16.8×13.0×19.6 cm with a density of (+9 Hounsfield [HU]), and at the bottom (+34.5 HU) with the presence of a ribbon-like inclusion. Subdiaphragmatic dimensions were 10.8×10.4×12.3 cm, density: +7.4 HU. Several other cysts were observed, measuring 1.5-1.4 cm with a density of (+3.5 HU)–(+6.2 HU). The liver, spleen, pancreas, and kidneys had irregular contours due to the adjacent polycystic tissues around their perimeter. A CT scan revealed that the abdominal parenchyma was intact. The liver density was (+52.5 HU)–(+56.3 HU). A chest CT scan revealed no hydatid cyst in the chest.

Following a consultation with a surgeon and a review of the glass slides and pathology blocks, histomorphology cystic echinococcosis of the abdominal cavity was identified in our center. Abdominal tuberculosis was ruled out in favor of disseminated echinococcosis of the abdominal cavity. The patient was admitted to the surgery ward because the patient's condition was extremely grave, exhausted, large flat stomach, and constant, non-stop dull aching pain in the abdomen.

#### Diagnostic Tests

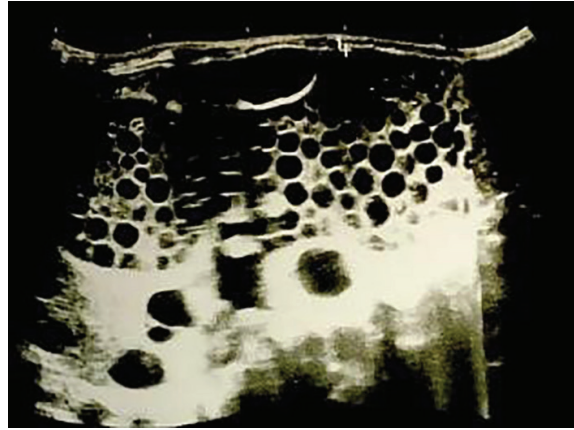
A physical examination of the patient revealed pale skin, sweating, delayed responsiveness, confusion and bloating, acute abdominal discomfort, particularly in the right hypochondrium, and positive indications of peritoneal irritation.

Serological qualitative and quantitative tests for echinococcosis were positive. The level of IgG was 7.62 index positive rates (reference means 0–0.849) indicating the enzyme-linked immunosorbent assays method.

Repeated ultrasonography of the abdominal organs to evaluate the surgical intervention strategies revealed extensive cystic lesions in the liver and abdominal cavity (figure 1). Multiple cysts were discovered in the structure of the liver, as well as around the liver, in the abdominal cavity, in the small pelvis, around the spleen, and within the spleen itself. The cyst size was around 30.0×12.0 cm with the presence of a lumen with many anechoic small cysts ranging in diameter from 0.5 to 2.0 cm. The exfoliated mother cyst membrane was located in the lumen of the cavity. Complete abdominal and pelvis ultrasonography revealed multiple echinococcosis of the abdominal cavity, liver, and spleen, classified as CE1 and CE3b.

The patient underwent open surgery under endotracheal anesthesia. Endocystectomy of the liver, spleen, abdominal cavity, and pelvis, as well as cholecystectomy, drainage of the abdominal cavity, and the common bile duct according to the Pikovsky type drainage, which included two ring-skeletons that allow its distal end to be securely fixed in the bile duct, were performed. The operation lasted 5 hours and 20 minutes.

After opening, the abdominal cavity was washed five times with a solution of povidone-iodine 10%-500 mL (Pharm Company Medoptik, Kazakhstan), and three times with a solution that was a combination of povidone-iodine 10%-250 mL and sodium chloride 0.9%-250 mL, (Kelun-Kazpharm, Kazakhstan), in a ratio of 1:1. During an examination of the abdominal cavity, multiple living echinococcal cysts ranging



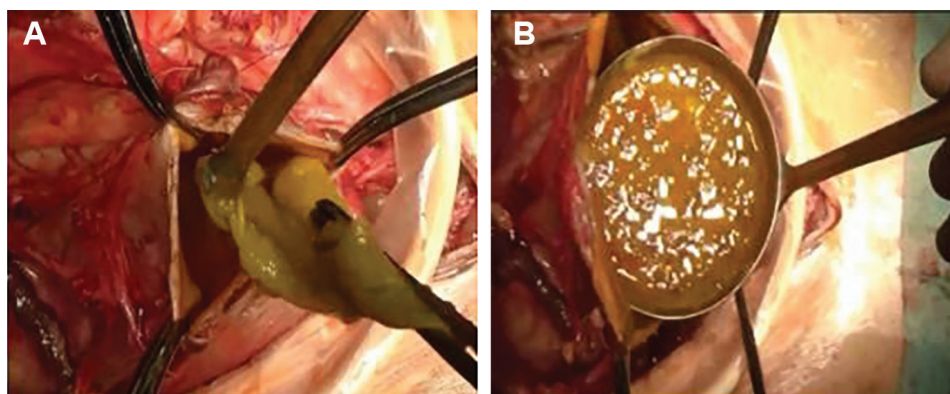
**Figure 1:** The echo sonography image shows an Echinococcal cyst of the abdominal cavity in stage CE2. The cavity has an irregular shape, and is massive in size, with the presence of daughter cysts in the lumen. The cysts have a diameter of 0.8-1.1 cm with echogenic capsules.

in size from 1.0 to 6.0 cm were found along the surface of the greater omentum, which was fused with the parietal peritoneum to the small pelvis. In connection with this, an omentectomy with ligation and division of the vessels was performed. A massive cystic formation measuring 20.0×18.0 cm was detected in the right lobe of the liver, along the lower contour, compressing the hepatoduodenal ligament and resulting in portal hypertension. There was significant expansion and swelling of the short gastric and omental veins. When mobilizing this cyst, a conglomerate of the gallbladder and hydatid cysts was revealed. A cholecystectomy and hemostasis of the liver tissue was performed. Further exploration of the abdominal cavity revealed several hydatid cysts ranging in size from 4.0 to 6.0 cm in the spleen, which were aspirated and opened. Five echinococcal cysts were found in the bursa and along the lesser curvature of the stomach, adjacent to the anterior wall of the pancreas, which were aspirated and opened (figures 2A and B). The abdominal cavity was washed three times with povidone solution. Subsequent inspection of the abdominal cavity revealed no more hydatid cysts. Hemostasis and layer-by-layer suturing of the wound, as well as drainage of the right subhepatic and subdiaphragmatic spaces, the pelvic cavity, and the left lateral canal of the abdominal cavity were conducted. The total blood loss was 200 mL.

The surgical material of echinococcal cysts was studied pathomorphologically (figure 3). Table 1 shows the patient's clinical laboratory test results before and after treatment.

The patient was discharged on the 15<sup>th</sup> day after surgery in satisfactory condition for outpatient observation with recommendations.





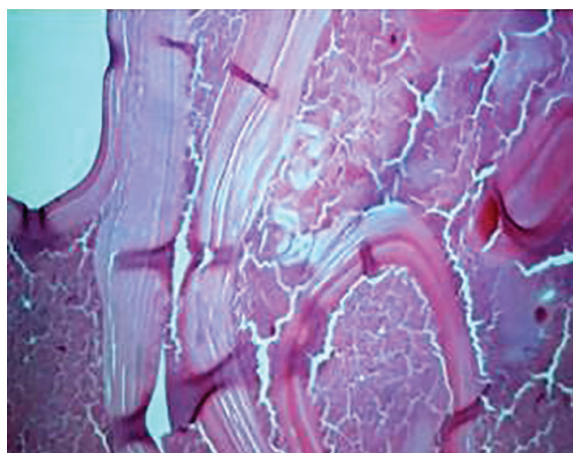
**Figure 2:** A) A large cystic mass was opened and aspirated. B) Multiple living hydatid cysts, ranging in size from 1.0 to 6.0 cm, were found in the abdominal cavity and removed. Then, the cavity was washed.

The development of the disseminated form of cystic echinococcosis from the moment of sports injury to the cystectomy and albendazole therapy is presented in figure 4.

The patient was warned about the high risk of recurring CE relapses in the abdominal cavity and other organs. Therefore, the patient was

administered with long-term use of albendazole, monthly consultations with a surgeon, and ultrasound of the abdominal organs during the first year, followed by every three months for the next 5 years.

The study was conducted in compliance with the Helsinki Declaration and was approved by the Local Ethics Commission of the Syzganov National Scientific Center of Surgery (IRB-005 dated 22/12/23). The patient's parents were informed about their right to discontinue their participation in the study at any time with no consequences. Anonymity and confidentiality were confirmed. Written informed consent was obtained from the patient's parents.



**Figure 3:** Microscopic examination of pathomorphological material shows a laminated layer of hydatid cyst with areas of the germinal layer (H&E stain).

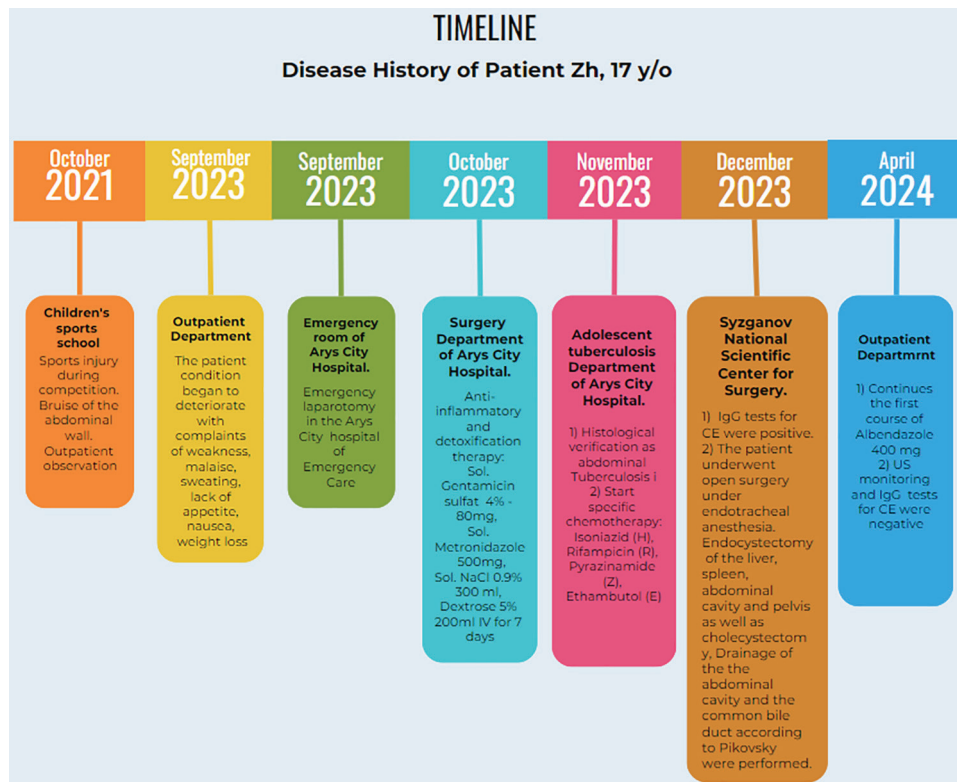
### Discussion

According to the existing literature, hydatid cyst rupture can be spontaneous or traumatic, and is frequently accompanied by anaphylactic shock.<sup>1,4</sup> In endemic areas, spontaneous rupture should serve as a warning.<sup>1, 4, 5</sup> The present patient had a rare case of hydatid cyst rupture associated with a sports injury, which led to

**Table 1:** The patient's clinical laboratory test results before and after treatment

Clinical laboratory tests	Before treatment mean±SD	After treatment mean±SD
Hb (g/L)	86.13±4.09	92.9±3.76
RBC (10 <sup>12</sup> /L)	3.36±0.49	4.30±0.17
ESR mm/h	52.70±4.04	19.30±1.0
WBC (10 <sup>9</sup> /L)	25.97±0.59	19.13±3.45
NEUT (10 <sup>9</sup> /L)	22.63±0.99	13.63±1.50
LPH (10 <sup>9</sup> /L)	1.99±0.17	3.37±0.51
NLR	11.40±0.60	4.16±1.14
ALT (U/L)	17.13±1.60	15.37±0.90
AST (U/L)	26.30±0.50	24.76±1.38
TB (µmol/L)	18.10±0.36	16.60±1.22
DB (µmol/L)	11.93±0.51	7.40±0.98
TCH (mmol/L)	1.29±0.16	1.19±0.28

Hb: Hemoglobin; RBC: Red blood cell; ESR: Erythrocyte sedimentation rate; WBC: White blood cell; NEUT: Neutrophile; LPH: Lymphocyte; NLR: Neutrophil-to-lymphocyte ratio; ALT: Alanine aminotransferase; AST: Aspartate aminotransferase; DB: Direct Bilirubin; TB: Total Bilirubin; TCH: Total cholesterol



**Figure 4:** The figure shows the timeline of patient diagnosis and treatment.

blurred manifestations of anaphylactic shock, a late diagnosis of echinococcosis, and untreated intra-abdominal dissemination.

Intra-abdominal tuberculosis is typically seen in the ileocecal region of the gastrointestinal tract. Clinical manifestations are more frequently manifested by the simultaneous presence of intra-abdominal lymphadenopathy, ascites, mesenteric thickening, ileocecal thickening, and splenic microabscesses. The clinical presentation can be varied. Therefore, it must be differentiated from an acute abdomen, acute appendicitis, adhesive disease, or even peritonitis with ascites. In many cases, the diagnosis is only confirmed intraoperatively. In the present case, the diagnosis was clarified by the method of exclusion, only after a three-fold pathomorphological examination of the intraoperative material.<sup>7</sup>

The preferred method for diagnosing liver CE is ultrasound, which allows the classification of the cyst. Multivesicular is a complex type of liver echinococcosis, which appears sonographically as fluid accumulations in the form of a honeycomb with clear outlines and numerous septa that serve as the walls of daughter cysts. The presence of daughter cysts or the membranes within a cyst is an essential differential diagnostic criterion.<sup>6</sup> In the present case, the first ultrasound diagnosis did not reveal a total disseminated echinococcosis of the abdominal cavity.

In addition to ultrasound, accurate serological tests can help with the differential diagnosis of echinococcosis. Despite the limitations of the serological tests, patients with multiple cysts have a seropositive result, the same as in the present case.<sup>7-9</sup>

According to the literature, the first step in the treatment of anaphylactic shock is to administer adrenaline as soon as possible to prevent severe fatal anaphylaxis.<sup>10, 11</sup>

The effect of physical activity on adrenaline levels was shown in an experimental study on rats that involved forced daily swimming for 60-90 min. Their findings indicated that 14 days of intense physical activity significantly increased adrenaline levels, compared with 21 days of activity or 14 days of rest,  $P=0.435$  and  $0.231$ , respectively.<sup>12</sup> Therefore, we might hypothesize that short-term training with intense physical activity could increase the level of adrenaline in the blood, thereby reducing the risk of developing anaphylactic shock.<sup>12</sup>

According to Lewall and colleagues, ruptured hydatid cysts can be classified into three types: limited, communicating, and direct. In cases of limited rupture, only the parasitic endocyst ruptures with the contents of the cyst are isolated by the host's pericyst. In a communicating rupture, the cyst's contents through the bile or bronchial ducts communicating to the pericyst. In direct rupture, both the endocyst and pericyst

are ruptured, and the contents of the cyst spill out directly into the abdominal or pleural cavity, and sometimes into other structures.<sup>13</sup> In this patient, the cause of the rupture was a sports injury, in the form of heavy pressure on the abdominal wall with the weight of a partner, which resulted in a direct rupture of the hydatid cyst of at least one of the parenchymal organs (liver or spleen).

Any type of ruptured hydatid cyst requires immediate surgical intervention. The ruptures with the greatest risk are direct and communicating types. Direct CE rupture is more likely to cause an anaphylactic reaction. CE rupture should be treated with surgery and long-term albendazole to reduce the risk of metastatic CE.<sup>13, 14</sup>

The literature discussed complicated forms of internal ruptures into hollow organs, with the formation of cystobiliary, broncho-biliary, and bronchopleural fistulas, as well as exterior cysto-cutaneous fistulas. More frequent complications include bacterial infection, anaphylactic reaction, compression from small hepatic veins to the hepatic and cava veins, known as secondary Budd-Chiari syndrome, as well as bile structures and compression of surrounding organs. In our case, intra-abdominal cyst compression of the hepatoduodenal ligament and hepatic vein was revealed. Moreover, significant expansion and swelling of the short gastric and omental veins resulted in presinus portal hypertension and hyperbilirubinemia, due to the high level of direct bilirubin, which indicated a violation of the bile outflow in the ducts without manifestations of liver cirrhosis.

According to the literature, administering albendazole for several months after surgery might not always prevent the development of CE relapse. There are known cases of relapse lasting 25-80 months in the postoperative period while taking albendazole.<sup>14, 15</sup> Disseminated abdominal CE requires medical treatment immediately after rupture.<sup>1</sup> However, in our case, when a huge number of daughter cysts were formed, surgical treatment of metastatic CE followed by long-term treatment with albendazole was required.

## Conclusion

The present study reported a case of a ruptured hydatid cyst in an athlete with no obvious signs of anaphylactic shock, which resulted in massive dissemination of echinococcosis throughout the entire abdominal cavity and pelvic regions. In regions endemic to echinococcosis, the need for high vigilance and mandatory imaging and immunological verification of all cases of abdominal wall injuries is recommended. Undoubtedly, all patients with disseminated

abdominal cystic echinococcosis should carefully be evaluated for tuberculosis of the mesenteric lymph nodes and acute appendicitis.

## Acknowledgment

We express our gratitude to Evgene Yenin for providing the histological material of this patient. This study was written as part of a research funded by the Committee of Science of the Ministry of Science and Higher Education of the Republic of Kazakhstan (Grant no. AP19676676).

## Authors' Contribution

B. B. and Sh. K.: Design, surgical intervention, writing of the manuscript especially discussion section; G. I. and M.F. H.: Study conception, design, data analysis, and interpretation, writing the manuscript and revising discussion section; E.N and Ch. S.: Data acquisition, analysis, and interpretation, writing the manuscript and revising the case presentation section; G. M: Data collection, drafting the manuscript, revising the case presentation section. All authors reviewed the final version and have read and approved the final manuscript and agree to be accountable for all aspects of the work in ensuring that questions related to the accuracy or integrity of any part of the work are appropriately investigated and resolved.

**Conflict of Interest:** None declared.

## References

- 1 Hanalioglu D, Terzi K, Ozkan S, Sivri M, Kurt F, Misirlioglu ED. Anaphylactic shock following minor abdominal trauma as the initial presentation of Echinococcus cyst: a case report. *BMC Pediatr.* 2022;22:89. doi: 10.1186/s12887-022-03154-z. PubMed PMID: 35151297; PubMed Central PMCID: PMC8840551.
- 2 Kaniyev S, Baimakhanov Z, Doskhanov M, Kausova G, Baimakhanov B. Recent Treatment Results of Liver Echinococcosis by Pair Method (Puncture, Aspiration, Injection, Reaspiration). *Georgian Med News.* 2020;11-4. PubMed PMID: 33395633.
- 3 Bakhytzhana S, Mukhtar S, Ruslan K, Denis V, Gulziya I. Single-center experience in the surgical treatment of combined lung Echinococcosis. *Saudi Med J.* 2018;39:31-7. doi: 10.15537/smj.2018.1.21169. PubMed PMID: 29332106; PubMed Central PMCID: PMC885118.
- 4 Daldoul S. Severe anaphylactic choc

- revealing vascular rupture of a liver hydatid cyst observed in an emergency unit in Tunis (Tunisia). *Bull Soc Pathol Exot.* 2014;107:302-5. doi: 10.1007/s13149-014-0384-3. PubMed PMID: 25158840.
- 5 Adhikari S, Bhattarai M, Gyawali S, Subedi S, Bhattarai A, Awale L, et al. Acute abdomen due to rupture of a hydatid cyst of the liver: a rare complication - a case report. *Ann Med Surg (Lond).* 2023;85:1172-6. doi: 10.1097/MS9.000000000000383. PubMed PMID: 37113932; PubMed Central PMCID: PMCPMC10129216.
  - 6 Marrone G, Crino F, Caruso S, Mamone G, Carollo V, Milazzo M, et al. Multidisciplinary imaging of liver hydatidosis. *World J Gastroenterol.* 2012;18:1438-47. doi: 10.3748/wjg.v18.i13.1438. PubMed PMID: 22509075; PubMed Central PMCID: PMCPMC3319939.
  - 7 James V, Samuel J, Ong GY. Pediatric Abdominal Tuberculosis With Calcified Intra-abdominal Lymph Nodes Identified by Point-of-Care Ultrasound. *Pediatr Emerg Care.* 2021;37:226-9. doi: 10.1097/PEC.0000000000002320. PubMed PMID: 33780407.
  - 8 Manterola C, Cuadra A, Munoz S, Sanhueza A, Bustos L, Vial M, et al. In a diagnostic test study the validity of three serodiagnostic test was compared in patients with liver echinococcosis. *J Clin Epidemiol.* 2005;58:401-6. doi: 10.1016/j.jclinepi.2004.10.009. PubMed PMID: 15862726.
  - 9 Strohaker J, Nadalin S. [Diagnostics and management of intra-abdominal Echinococcus manifestation]. *Chirurg.* 2019;90:823-32. doi: 10.1007/s00104-019-1001-6. PubMed PMID: 31312861.
  - 10 Bilo MB, Martini M, Tontini C, Corsi A, Antonicelli L. Anaphylaxis. *Eur Ann Allergy Clin Immunol.* 2021;53:4-17. doi: 10.23822/EurAnnACI.1764-1489.158. PubMed PMID: 32550734.
  - 11 Navalpakam A, Thanaputkaiporn N, Poowuttikul P. Management of Anaphylaxis. *Immunol Allergy Clin North Am.* 2022;42:65-76. doi: 10.1016/j.iac.2021.09.005. PubMed PMID: 34823751.
  - 12 Gashi AI, Gontarev S, Zivkovic V, Gjorgovski I, Azemi A. The Effect of Aerobic Physical Activity in Adrenaline Level in White Laboratory Rats. *Med Arch.* 2020;74:84-9. doi: 10.5455/medarh.2020.74.84-89. PubMed PMID: 32577046; PubMed Central PMCID: PMCPMC7296409.
  - 13 Lewall DB, McCorkell SJ. Rupture of echinococcal cysts: diagnosis, classification, and clinical implications. *AJR Am J Roentgenol.* 1986;146:391-4. doi: 10.2214/ajr.146.2.391. PubMed PMID: 3510519.
  - 14 Buscemi C, Randazzo C, Buscemi P, Caldarella R, Lombardo M, Buscemi S. Very Prolonged Treatment with Albendazole of a Case of Disseminated Abdominal Cystic Echinococcosis. *Trop Med Infect Dis.* 2023;8. doi: 10.3390/tropicalmed8090449. PubMed PMID: 37755910; PubMed Central PMCID: PMCPMC10534633.
  - 15 Obeid M, Mansour S, Damouny M, Farah A, Halloun K, Marjiyeh R, et al. A Conservative Management of Spontaneously Ruptured Liver Hydatid Cyst. *Gastroenterology Res.* 2021;14:125-8. doi: 10.14740/gr1373. PubMed PMID: 34007355; PubMed Central PMCID: PMCPMC8110234.