

# Implantation Metastasis of Synovial Cell Sarcoma: Lessons Learned from a Mistake

Seyed Mokhtar Esmailnejad-Ganji, MD<sup>1</sup>  
Behnam Baghianimoghadam, MD<sup>1</sup>

Department of Orthopedic Surgery,  
Babol University of Medical Sciences,  
Babol, Iran

## Correspondence:

Behnam Baghianimoghadam, MD;  
Orthopedic surgeon, Shahid Behesti  
Hospital, Department of Orthopedic  
Surgery, Babol University of Medical  
Sciences, P.O. Box: 47166-81451,  
Babol, Iran

**Tel:** +98 913 3530594

**Fax:** +98 11 32251664

**Email:** behnam.baghian@gmail.com

Received: 01 November 2017

Revised: 10 December 2017

Accepted: 07 January 2018

## Abstract

Implantation metastasis occurs when tumor seeds into a wound or tissue by a significant amount of viable tumor cells. Here we describe the case of a 30-year-old man suffering from pain and swelling of the foot, which was misdiagnosed as a bone cyst. Surgery was performed involving curettage followed by bone grafting. After surgical pathology, the exact diagnosis was revealed as the synovial sarcoma (SS) of the foot. Implantation metastasis of SS in the iliac region, the grafting site, occurred 9 months post-surgery. Although there are a few reports on implantation metastasis of other types of tumoral lesions, to the best of our knowledge, we describe seeding of this type of tumor for the first time. Similar to other studies, we recommend that tumor surgeries should be carried out in a special setting to prevent any spread to or contamination of other sites by the tumor.

Please cite this article as: Esmailnejad-Ganji SM, Baghianimoghadam B. Implantation Metastasis of Synovial Cell Sarcoma: Lessons Learned from a Mistake. *Iran J Med Sci.* 2019;44(6):515-518. doi: 10.30476/ijms.2019.45424.

**Keywords** • Sarcoma • Synovial • Neoplasm seeding • Medical errors

## What's Known

- The seeding of tumor cells from a tumor site in a graft donor site during surgery is a known complication.
- Although implantation metastasis has been reported for various tumors, there are no reports on synovial cell sarcoma as a tumor susceptible for seeding.

## What's New

- For the first time, a case of implantation metastasis of synovial cell sarcoma is reported.
- Precautionary measures against implantation metastasis are proposed.

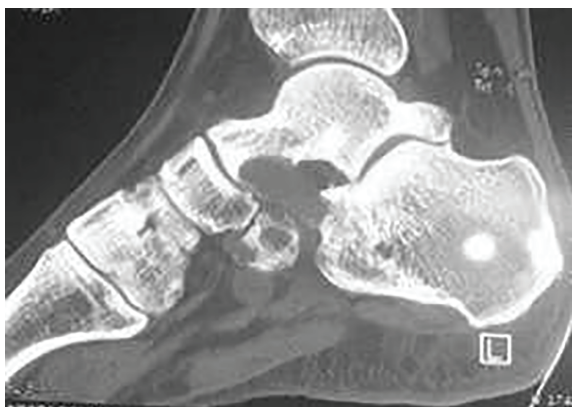## Introduction

Synovial sarcoma (SS) is a malignant mesenchymal neoplasm, which has a partial epithelial differentiation and mostly occurs in young adults. It was common belief that it originated from synovial cells since it frequently occurred in the soft tissue of body joints. However, it is shown that SS does not arise from synovial cells nor it is specific to joints. Consequently, the term synovial sarcoma is now viewed as an oversight.<sup>1</sup>

Seeding or implantation metastasis is defined as seeding and subsequent growth of a significant number of viable tumor cells into the tissue.<sup>2</sup> There are only a limited number of reports on various tumors responsible for the contamination of the graft donor site during autograft harvesting. However, to the best of our knowledge, there are no reports on implantation metastasis of SS. Here we report a case of SS, which was misjudged as a simple bone cyst. The cancer was treated with curettage followed by autograft, which resulted in implantation metastasis.

## Case Presentation

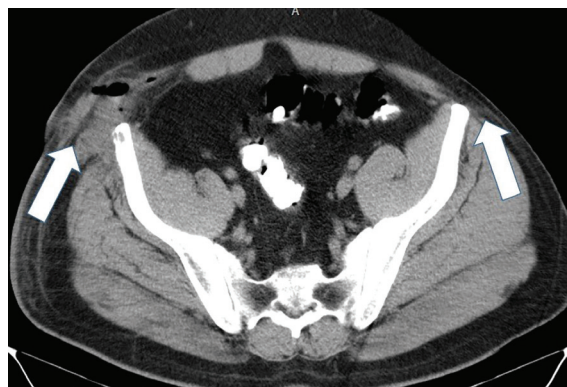
A 30-year-old man was primarily presented with a simple spontaneous swelling and pain on the dorsum of the foot. Initially, the internist treated the problem as gout. However, the problem persisted and thus radiography and magnetic resonance imaging (MRI) evaluations were carried out. A unicameral bone cyst (talocalcaneal and talonavicular joints) was suggested (figure 1)



**Figure 1:** Sagittal plane of the CT-scan shows a soft tissue mass involving talonavicular and talocalcaneal joints that caused bone resorption.

and the patient underwent surgical curettage followed by harvesting autologous bone graft from the iliac crest. As the surgery was carried out at another center, we had no information on the surgical setting, preoperative planning, or the surgeon's decision on the differential diagnoses of the disease. The pathology report indicated synovial cell sarcoma and subsequently the patient underwent chemoradiotherapy.

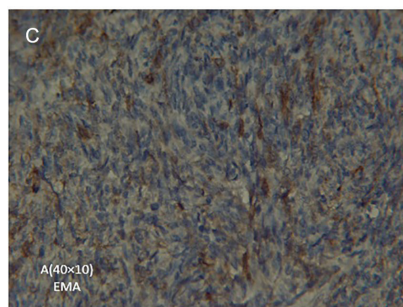
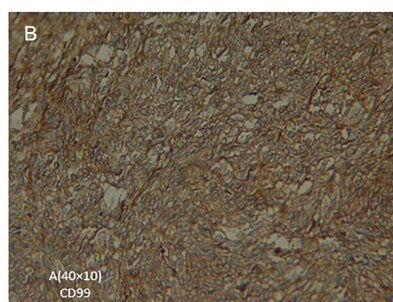
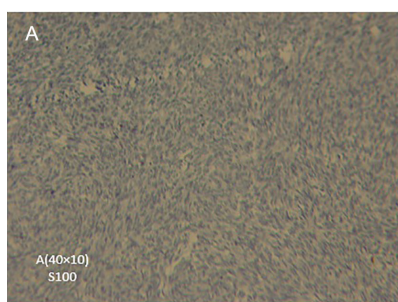
Due to postoperative tumor recurrence, the patient was referred to our center. At this stage, knee amputation was suggested. However, the patient rejected this option and requested another tumor excision attempt. We accepted the request conditioned to amputation if a margin-free tumor excision was not possible. Two weeks later, regrettably, we had to perform another operation for a below-the-knee amputation. After



**Figure 2:** Axial plane of a CT-scan after implantation metastasis of synovial cell sarcoma in the iliac region. Note the soft tissue mass which caused swelling contrasting with the contralateral side (arrows).

9 months, during a follow-up visit, a bulge in the pelvis around the previous site of donor graft was observed. Sonography, MRI, and CT-scan evaluations revealed a mass on the ilium at the graft harvesting site of the first surgery (figure 2). Another surgery was performed and the mass was excised. Surprisingly, the pathologic study revealed synovial sarcoma (figure 3). Immunohistochemistry studies (with CD99, EMA and S100 markers staining) revealed monophasic sarcoma composed of only spindle cell sarcomatous component characterized by a high degree of cellularity, nuclear atypia, and mitotic activity. Spindle cells had distinct lobulation and were arranged in fascicles.

Based on the above course of events, we deduced the implantation of the primary tumor cells of the foot to the graft harvesting site. We



**Figure 3:** Biopsy of the iliac crest specimen (A, B, and C). Sections show monophasic sarcoma composed of only spindle cell sarcomatous component characterized by a high degree of cellularity, nuclear atypia, and mitotic activity. Spindle cells are arranged in fascicles with distinct lobulation.

believe that the first surgeon did not consider the possibility of a malignant tumor and used the same surgical devices for both the tumor excision and the graft harvesting. Written informed consent was obtained from the patient for the publication of this case report, including accompanying images.

## Discussion

The present case report described a case of SS with iatrogenic seeding of a tumor in the iliac region, which was at the bone graft donor site. To the best of our knowledge, there are no published reports on the iatrogenic implantation of this type of tumor. Previous studies have reported cases related to the implantation of giant cell tumor,<sup>3-5</sup> chondroblastoma,<sup>6</sup> or osteosarcoma.<sup>7</sup>

The implantation in our case occurred at the ipsilateral iliac crest (bone graft donor site) probably due to the contamination of the donor site by tumor cells from the primary lesion site. The evaluation of a CT-scan revealed a lesion in the subcutaneous tissue beneath the scar of the iliac crest harvesting site. There are some theories about the cause of this; the most probable cause is direct contamination of the donor site with tumor cells from instruments or gloves.<sup>6</sup> Some authors suggest that graft harvest causes a vascular endothelial injury to the bone, which makes the environment susceptible to circulating tumor cells to implant and grow.<sup>6</sup> Malignant tumors have a higher seeding ability, however, there are some reports on the implantation of benign tumors.<sup>8-11</sup>

In the present case, we were dealing with a malignant tumor. As in many other studies on seeding, the case was misdiagnosed as a benign unicameral bone cyst. Consequently, the surgical procedure was in accordance with the benign tumor treatment protocol, rather than the recommended surgical management for malignant tumors. Interesting enough, there are no reports on the implantation of SS. The apparent misdiagnosis presumably originated from a radiographic misinterpretation. In about 50% of SS cases, the radiography appears normal, particularly in small lesions. Some could appear as non-specific juxta-articular lesions. In addition, eccentric calcifications maybe identified. The important point is that in 11-20% of the SS cases, extrinsic erosion of the bone or a periosteal reaction could be a possibility, which could result in the misinterpretation of this tumor as benign.

MRI is the best modality to assess the extent as well as the intrinsic nature of SS (like other soft tissue tumors). On a T1-weighted MRI image,

SS appears as a multilobulated heterogeneous mass in soft tissue; its signal is similar or slightly higher than the surrounding muscle. However, on a T2-weighted MRI image, there is a high signal intensity with apparent heterogeneity. CT-scan is also suitable to detect calcification and bone erosion.<sup>12</sup>

In regard to our patient, the initial surgery was not performed in our center, there was no primary biopsy performed before surgery, curettage followed by bone grafting was done, and the exact diagnosis of SS was only revealed after the surgery and the subsequent pathologic study. Tumor surgery requires experience and a special setting to comply with the procedures. The tumor site and graft site must be prepared separately. In addition, each surgical site must be covered by separate drapes from different packs. Harvesting of the graft should only start after the completion of curettage of the primary tumor site and the graft donor site must not be exposed during curettage. Harvesting must be done with a different set of gloves and instruments and in new gowns. Nonconformity may cause serious complications.<sup>4</sup>

## Conclusion

Implantation metastasis is mainly due to medical errors and is undoubtedly avoidable. Tumor surgery should be carried out in a special setting to prevent any spread or contamination of other sites by the tumor.

**Conflict of Interest:** None declared.

## References

- 1 Thway K, Fisher C. Synovial sarcoma: defining features and diagnostic evolution. *Ann Diagn Pathol.* 2014;18:369-80. doi: 10.1016/j.anndiagpath.2014.09.002. PubMed PMID: 25438927.
- 2 Singh C, Ibrahim S, Pang KS, Shanti S. Implantation metastasis in a 13-year-old girl: a case report. *J Orthop Surg (Hong Kong).* 2003;11:94-6. doi: 10.1177/230949900301100118. PubMed PMID: 12810979.
- 3 Gulia A, Puri A, Salunke A, Desai S, Jambhekar NA. Iatrogenic implantation of giant cell tumor at bone graft donor site and clinical recommendations to prevent "a rare avoidable complication". *Eur J Orthop Surg Traumatol.* 2013;23:715-8. doi: 10.1007/s00590-012-1055-3. PubMed PMID: 23412188.
- 4 Joynt GH, Ortvad WE. The Accidental Operative Transplantation of Benign Giant

- Cell Tumor. *Ann Surg.* 1948;127:1232-9. doi: 10.1097/00000658-194806000-00013. PubMed PMID: 17859164; PubMed Central PMCID: PMCPMC1513700.
- 5 Ofluoglu O, Donthineni R. Iatrogenic seeding of a giant cell tumor of the patella to the proximal tibia. *Clin Orthop Relat Res.* 2007;465:260-4. doi: 10.1097/BLO.0b013e31813ffbd8. PubMed PMID: 17589357.
  - 6 Zafatayeff-Hasbani S, Ducou Le Pointe H, Josset P, Damsin JP, Montagne JP. Intra-articular recurrence of benign chondroblastoma with articular involvement at initial presentation--a case report. *Eur J Pediatr Surg.* 2006;16:291-3. doi: 10.1055/s-2005-873074. PubMed PMID: 16981100.
  - 7 Cole GW, Jr., Sindelar WF. Iatrogenic transplantation of osteosarcoma. *South Med J.* 1995;88:485-8. doi: 10.1097/00007611-199504000-00023. PubMed PMID: 7716608.
  - 8 Dias RG, Abudu A, Carter SR, Grimer RJ, Tillman RM. Tumour transfer to bone graft donor site: a case report and review of the literature of the mechanism of seeding. *Sarcoma.* 2000;4:57-9. doi: 10.1155/S1357714X00000098. PubMed PMID: 18521435; PubMed Central PMCID: PMCPMC2408361.
  - 9 Ferguson PC, Sommerville S, Grimer RJ. Possible metastasis of osteosarcoma to a remote biopsy site: a case report. *Clin Orthop Relat Res.* 2004;424:216-20. doi: 10.1097/01.blo.0000128289.43825.cc. PubMed PMID: 15241168.
  - 10 Enneking WF, Maale GE. The effect of inadvertent tumor contamination of wounds during the surgical resection of musculoskeletal neoplasms. *Cancer.* 1988;62:1251-6. doi: 10.1002/1097-0142(19881001)62:7<1251::aid-cnrcr2820620702>3.0.co;2-4. PubMed PMID: 3416267.
  - 11 Yip KM, Lin J, Kumta SM. A pelvic osteosarcoma with metastasis to the donor site of the bone graft. A case report. *Int Orthop.* 1996;20:389-91. doi: 10.1007/s002640050105. PubMed PMID: 9049772.
  - 12 Murphey MD, Gibson MS, Jennings BT, Crespo-Rodriguez AM, Fanburg-Smith J, Gajewski DA. From the archives of the AFIP: Imaging of synovial sarcoma with radiologic-pathologic correlation. *Radiographics.* 2006;26:1543-65. doi: 10.1148/rg.265065084. PubMed PMID: 16973781.