

Isolated Sternal Tuberculosis Presenting as a Chest Wall Abscess: A Case Report

Priyanka Anand, MD;
Namrata Sarin, MD

Department of Pathology; North Delhi
Municipal Corporation Medical College
and Hindu Rao hospital, Delhi, India

Correspondence:

Priyanka Anand, MD;
Department of Pathology, NDMC
and Hindurao Hospital, Malka ganj,
New Delhi-110007, India
Tel: +91 99 90331813
Email: priyankaanand19@yahoo.com
Received: 20 May 2017
Revised: 03 June 2017
Accepted: 02 July 2017

Abstract

In India, pulmonary tuberculosis accounts for 85% of cases and extrapulmonary tuberculosis accounts for 15% of cases with bone and joint involvement is seen in 1 to 3% of cases. Primary tuberculous osteomyelitis of the sternum is a rare form of extrapulmonary tuberculosis. A 51-year-old male presented with 10 years history of swelling over the anterior chest wall and pain for past 6 months. Fine-needle aspiration cytology (FNAC) revealed a markedly granular necrotic background. Ziehl-Neelsen staining was positive for acid-fast bacilli and a diagnosis of the tubercular abscess was made. Chest X-ray was normal. Contrast-enhanced computed tomography was done, which gave an evidence of the erosion of the anterior surface of the sternum. Tuberculosis of the sternum is a rare form of flat bone tuberculosis. The possibility of sternal tuberculosis should be kept in mind in any patient with a mass, non-healing ulcer, or abscess in the sternal region.

Please cite this article as: Anand P, Sarin N. Isolated Sternal Tuberculosis Presenting as a Chest Wall Abscess: A Case Report. *Iran J Med Sci.* Iran J Med Sci. 2018;43(4):440-443.

Keywords • Thoracic wall • Sternum • Tuberculosis • Abscess

What's Known

- Extrapulmonary tuberculosis accounts for 15% of cases with bone and joint involvement is seen in only 1 to 3% of cases with tuberculous sternal involvement in approximately 1% of all skeletal tuberculosis cases.

What's New

- An unusual case of primary manubrio-sternal joint tuberculosis in a completely asymptomatic patient presenting as a vague anterior chest wall swelling is reported.
- Fine-needle aspiration cytology (FNAC) is a simple non-invasive procedure, which can help to attain early diagnosis and prompt treatment.

Introduction

In India, pulmonary tuberculosis accounts for 85% of cases and extrapulmonary tuberculosis accounts for 15% of cases with bone and joint involvement is seen in 1 to 3% of cases.¹ Primary tuberculous osteomyelitis of the sternum is a rare form of extrapulmonary tuberculosis in which tuberculosis primarily affects the sternum. Sternal tuberculosis was first reported in 1918 and until 2007, less than 35 cases were documented in the literature. Tuberculous sternal involvement is seen in approximately 1% of all skeletal tuberculosis cases² and approximately 0.3% of all types of tuberculosis cases.

According to the WHO global tuberculosis report 2013, 20% of all freshly diagnosed cases in India are extrapulmonary. The report also highlights that from the 300,000 cases of multidrug-resistant (MDR) in the world, India alone has a burden of 64,000 cases.^{3,4} Sternum remains the most common site to be involved, though rib shafts, costochondral junctions, and vertebral bodies can also be involved. A painless cold abscess may be the only presenting clinical feature for a prolonged period.⁵

The main purpose of the present report is to spread awareness regarding primary sternal tuberculosis, which can present as a vague anterior chest wall swelling of a very long duration and can remain unnoticed due to the lack of any signs and symptoms. Therefore, inexpensive and relatively less invasive procedure like

fine-needle aspiration cytology and further by radiological investigations can play an important role in clinching the diagnosis and a timely and proper management of the patient.

Case Presentation

A 51-year-old male from the northern part of India presented with 10 years history of swelling over the anterior chest wall (Figure 1) and pain for past 6 months. The pain was insidious in onset. It was localized and used to subside by taking analgesics. There was no history of fever, cough, weight loss, or any respiratory complaints. Past history and family history of tuberculosis were not contributory. The patient gave a history of trauma at the same site of the swelling, but denied any history of joint pains in the past. On examination, the patient was average built and weighed 68 kg. He was afebrile with normal pulse and blood pressure. Local examination revealed a large solitary lesion over the sternum of about 2.5×2.5 cm. The lesion was soft, fluctuating, tender, warm, and mobile with well-defined margins. There was no involvement of the regional lymph nodes.

Investigations revealed hemoglobin 9.8%, total leucocyte count of $20 \times 10^9/l$ with 84% neutrophils and an elevated ESR of 60 mm/hour. All other biochemical investigations were within normal limits. Sputum for acid-fast bacilli was negative. Mantoux tuberculin skin test was positive (20 mm induration) after 48 hours. HIV serology was done which was negative. Fine-needle aspiration cytology was performed from the swelling, which revealed occasionally scattered lymphocytes on a markedly granular necrotic background (figure 2). Ziehl-Neelsen staining was positive for acid-fast bacilli (figure 3) and a diagnosis of a tubercular

abscess was made. Pus culture was also done which turned out to be positive for acid-fast bacilli. Mycobacterium tuberculosis grew in cultures 5 weeks later (figure 4) and was susceptible to all tested antitubercular drugs. Chest X-ray was normal. Ultrasonography was done in which there was an evidence of relatively well-defined heterogeneous hypoechoic lesion of size 34×25 mm at the site of swelling in the superficial plane. Internal calcific foci were also seen. The lesion showed deeper extension via a small tract and involving underlying sternum; a diagnosis suggestive of chronic osteomyelitis or a neoplastic etiology was given. There was no involvement of other bones.

Contrast-enhanced computed tomography of the thorax showed a hypodense collection in the anterior chest wall with peripheral enhancement, suggestive of an abscess overlying the manubrium sterni with the evidence of the erosion of the anterior surface of the sternum communicating with the collection (figure 5). In the CT scan, no pathological findings in the

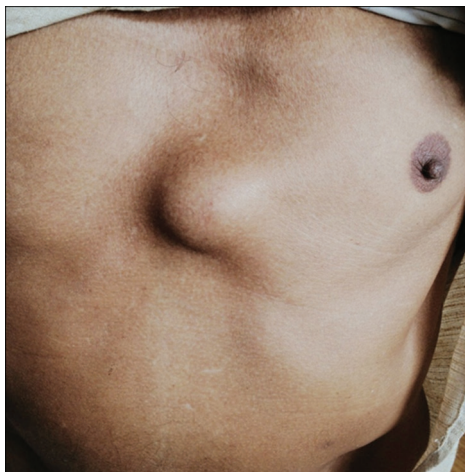

Figure 1: Anterior chest wall swelling.

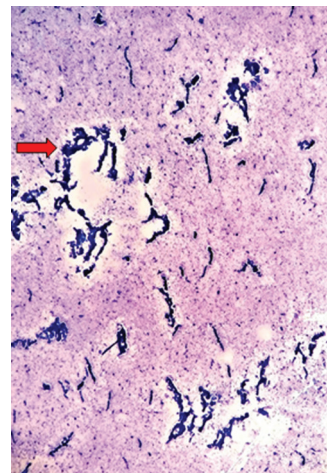


Figure 2: FNAC smears showing markedly necrotic background as shown by arrows (MGG, 10 \times).

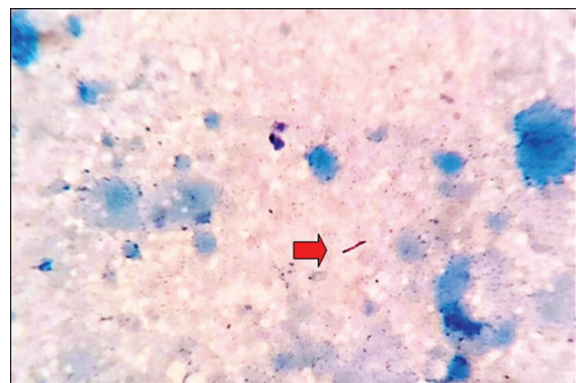


Figure 3: Ziehl-Neelsen stained smear (100 \times). The arrow shows acid-fast bacilli.

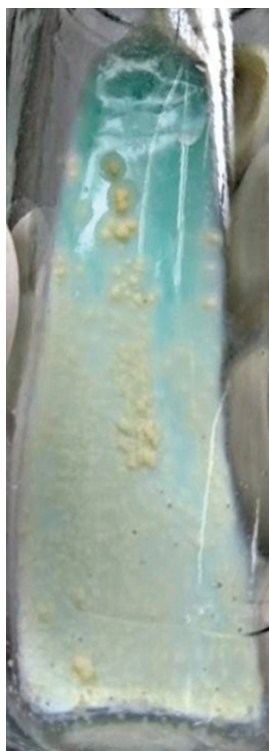

Figure 4: Lowenstein-Jensen medium that shows small raised, rough, and buff colored mycobacterium tuberculosis colonies.

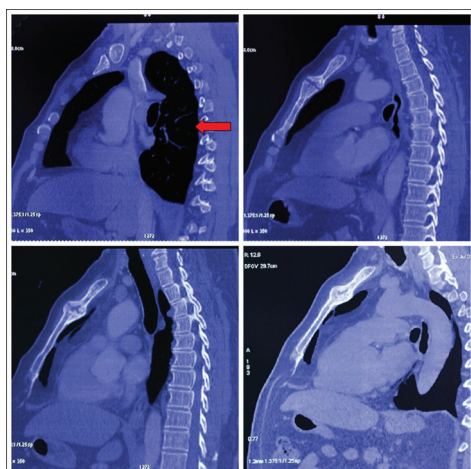


Figure 5: CT-thorax showing the erosion of the anterior surface of the sternum and lung parenchyma is normal as shown by an arrow.

pulmonary parenchyma, pleura, and lymph nodes were detected. Biopsy of the lesion was not advised and the patient was commenced on anti-tubercular therapy for 12 months. The patient is currently under follow-up in the continuation phase of treatment and is presently symptom-free.

A written informed consent was obtained from the patient for the publication of this case report and accompanying images.

Discussion

The sternum is an infrequent site for localization in extrapulmonary tuberculosis (TB). A high index of suspicion is required to overcome the diagnostic dilemma, especially if pulmonary tuberculosis is not associated.⁵ Mathlouthi et al. concluded that the thoracic wall is an uncommon site for tuberculosis, accounting for 1-5% of all cases of bone and joint tuberculosis, which itself accounts for 15% of all extrapulmonary localizations.⁶ Tuli and Sinha reported 14 (1.5%) cases of sternal TB out of 980 osteoarticular tuberculosis cases.⁷

Chest wall abscess usually occurs as a solitary lesion, most frequently involving the margins of the sternum and in the shafts of ribs. In our case, the abscess was present in the upper part of the chest in the sternal region. Acid-fast bacilli in the aspirated pus indicated tubercular etiology of the lesion. Chest X-ray was normal without any hilar adenopathy. Computed tomography (CT) scan confirmed that lesion involved the underlying sternum. Sternal TB has also been reported in two exceptional conditions following BCG vaccination in infants and after sternotomy for cardiac surgeries. Clinically, a patient can present as an anterior chest wall swelling, pre-retrosternal dull aching pain or in long-standing cases, ulcers with discharging sinuses over the anterior chest wall, and sternal fracture. Differential diagnosis of chest wall swellings with or without discharging sinuses includes diseases such as granulomatous diseases (sarcoidosis), chronic infections (fungal, parasitic), and malignancies (lymphomas and metastasis). Pyogenic infections of the sternum are more fulminant as they can cause destruction of the cartilage due to the release of proteolytic enzymes and they often present with prominent constitutional symptoms. In contrast, in tuberculosis, cartilage is first peripherally destroyed with preservation of joint space for a long period of time. Thus, sternal tuberculosis can present with an indolent course without any constitutional symptoms as in our case.⁸

The serologic markers of inflammation like ESR, CRP, and TLC are neither specific nor entirely reliable. It is difficult to appreciate sternal affection on chest X-ray. Moreover, radiological signs appear much later than the clinical features and abscesses or sinuses are present much before the focus is found.⁹ In our patient, chest radiograph was normal. CT scan defines the extent of bony destruction but does not confirm the diagnosis and only biopsy is the gold standard. Radiological findings cannot

differentiate the cause of osteomyelitis and can appear neoplastic as in our case where ultrasonography findings were suggestive of a neoplastic etiology. It is possible to establish the diagnosis by fine-needle aspiration cytology or marginal biopsy from the sinus tract.

Possible complications of sternal tuberculosis include secondary infection, fistula formation, spontaneous fractures of the sternum, compression or erosion of the large blood vessels, compression of trachea and migration of tubercular abscess into the mediastinum, and pleural cavity or subcutaneous tissues.⁹ Many authors have reported surgical debridement is essential for preventing recurrences or sinus formation.¹⁰ They proposed that the mainstay of treatment should be early drainage and complete debridement of necrotic tissue, which may include sternectomy and concomitant with antitubercular treatment (ATT). A structured regimen of four anti-tubercular drugs, initially for two months in the intensive phase, followed by two drugs (INH and Rifampicin) for 10-18 months in the maintenance phase is recommended. However, in a study of 14 patients, Khan et al.⁸ found that surgical intervention and biopsy was only necessary if needle aspiration is inconclusive, draining sinuses, debridement to promote early healing for extensively damaged bones or joint, secondary infections or mediastinitis, or when a patient not responding to ATT.

Conclusion

Tuberculosis of the sternum is a rare form of flat bone tuberculosis. It is usually a part of disseminated tuberculosis. Anterior chest pain and swelling are early manifestations, which must be properly evaluated to avoid serious complications. The possibility of sternal TB should be kept in mind in any patient with a mass, non-healing ulcer, or abscess in the sternal region. Therefore, a proper history and physical examination are of utmost importance and are the main keys in forming differential diagnoses.

FNAC serves as an essential inexpensive and relatively less invasive procedure, which helps attain diagnosis. Antitubercular therapy is the mainstay of treatment. A periodic follow-up is necessary to monitor response to treatment, drug resistance, and to avoid complications.

Conflict of Interest: None declared.

References

1. Shanmugasundaram T. Bone and joint tuberculosis-Guidelines for management. *Indian J Orthop.* 2005;39:195-8. doi: 10.4103/0019-5413.36743.
2. Gupta M, Mittal MK, Agarwal AK, Thukral BB. Primary Tubercular Osteomyelitis of Manubrio Sternal Joint: A Case Report. *Mycobact Dis.* 2015;5:188. doi: 10.4172/2161-1068.1000188.
3. India TB. Revised National Tuberculosis Control Programme Annual Status Report. Central TB Division, Directorate General of Health Services, Ministry of Health and Family Welfare. New Delhi: Central TB Division. 2014.
4. World Health Organisation. Multidrug resistant tuberculosis (MDR-TB). Geneva: World Health Organisation; 2013.
5. Rajput AK, Rajan KE, Gupta RK, Muttagikar MP. Tuberculosis of Sternum. *Med J Armed Forces India.* 2001;57:330-2. doi: 10.1016/S0377-1237(01)80017-4. PubMed PMID: 27365635; PubMed Central PMCID: PMC4924226.
6. Mathlouthi A, Ben M'Rad S, Merai S, Friaa T, Mestiri I, Ben Miled K, et al. Tuberculosis of the thoracic wall. Presentation of 4 personal cases and review of the literature. *Rev Pneumol Clin.* 1998;54:182-6. PubMed PMID: 9805747.
7. Tuli S, Sinha G. Skeletal tuberculosis" Unusual" lesions. *Indian J Orthop.* 1969;3:5-18.
8. Khan SA, Varshney MK, Hasan AS, Kumar A, Trikha V. Tuberculosis of the sternum: a clinical study. *J Bone Joint Surg Br.* 2007;89:817-20. doi: 10.1302/0301-620X.89B6.18777. PubMed PMID: 17613511.
9. Sharma S, Juneja M, Garg A. Primary tubercular osteomyelitis of the sternum. *Indian J Pediatr.* 2005;72:709-10. PubMed PMID: 16131781.
10. O'Brien DP, Athan E, Hughes A, Johnson PD. Successful treatment of Mycobacterium ulcerans osteomyelitis with minor surgical debridement and prolonged rifampicin and ciprofloxacin therapy: a case report. *J Med Case Rep.* 2008;2:123. doi: 10.1186/1752-1947-2-123. PubMed PMID: 18439310; PubMed Central PMCID: PMC2396654.