

Large Sphenoethmoidal Encephalocele Associated with Agenesis of Corpus Callosum and Cleft Palate

Basir Hashemi, Tayebe Kazemei,
Akbar Bayat

Abstract

Basal encephalocele is a rare craniofacial anomaly. In the present paper we report a 10-year-old boy presented with cleft palate, congenital nystagmus, and hypertelorism. During pre-operative evaluation for cleft palate repair, a pulsatile mass was detected in the pharynx. Magnetic resonance imaging showed sphenoethmoidal type of basal encephalocele and agenesis of corpus callosum. Neurosurgical consultation was performed for further evaluation and management.

Iran J Med Sci 2010; 35(2): 154-156.

Keywords • Encephalocele • cleft palate • nystagmus • corpus callosum

Introduction

Basal encephaloceles are uncommon congenital malformations, with an estimated frequency of 1 per 100,000 live births.¹ Encephaloceles are commonly classified into four groups based on the anatomical site of the defect in cranium including trans-sphenoidal, sphenoethmoidal, spheno-orbital, and transethmoidal.¹

Trans-sphenoidal encephalocele is the rarest form, comprising of only 5% of basal encephaloceles. Basal encephaloceles may be associated with upper airway obstruction especially in infants.² Trans-sphenoidal basal encephaloceles are associated with hypothalamic – pituitary dysfunction, congenital optic disc anomaly, mid-facial anomaly and agenesis of corpus callosum.¹

In patients with cleft palate and without cleft lip, there are higher rates of encephalocele, microcephaly and syndactyly. In patients with cleft lip (with or without cleft palate), there are higher rates of anophthalmia, microphthalmia, single ventricle and reduction deformity of upper and lower limbs.³

In the case reported by Lewin the encephaloceles had prolapsed into nose and nasopharynx and protruded into the mouth.⁴

Case Report

The patient was a 10-year-old boy, who was born full term by normal vaginal delivery. His birth weight was 3500 grams. He had cleft palate, hypertelorism and nystagmus. The patient had negative history of meningitis, CSF rhinorrhea, or cyanosis, however he had a history of intermittent snoring.

Physical examination showed complete secondary cleft palate and a 25×30 mm epipharyngeal mass that was soft,

Department of Otolaryngology,
Khalili Hospital,
Shiraz University of Medical Sciences,
Shiraz, Iran.

Correspondence:

Tayebe Kazemei MD,
Department of Otolaryngology,
Khalili Hospital,
Shiraz University of Medical Sciences,
Shiraz, Iran.

Tel: +98 917 3030863

Fax: +98 711 6471478

Email: kazemei@sums.ac.ir

Received: 18 January 2009

Accepted: 3 May 2009

compressible, and pulsatile. Figure 1 shows complete secondary cleft palate and an epipharyngeal mass.

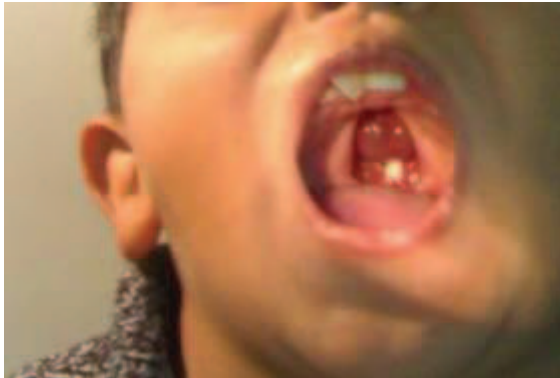

Figure 1: Cleft palate and a pulsatile epipharyngeal mass can be seen.

Brain magnetic resonance imaging (MRI),

demonstrated large sphenoethmoidal encephalocele extending to posterior nasal cavity. A mixed cystic and solid structure was seen in the site of pituitary gland, which could be a dysplastic tissue or complete agenesis of corpus callosum. Other MRI findings included large high riding third ventricle, staghorn frontal horn of lateral ventricle, and colpocephaly (enlarged occipital horn of lateral ventricle). The fourth ventricle, cerebellum, and brain stem appeared normal.

Figures 2, 3, and 4 show axial, coronal and sagittal view of the MRI of this patient, respectively.

Discussion

Trans-sphenoidal subtype is the rarest type of encephalocele and is often associated with hypothalamic-pituitary dysfunction, congenital optic disc anomaly, mid facial anomaly, cerebral

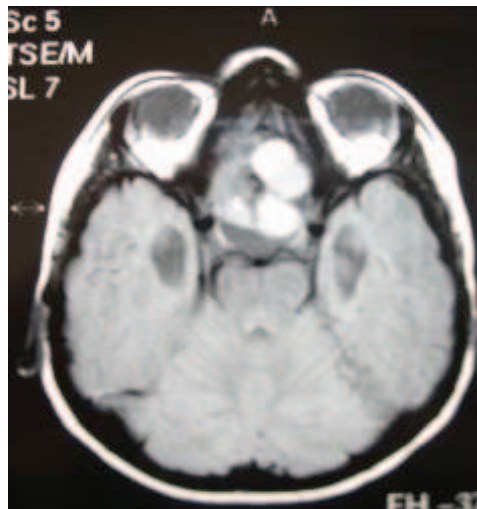


Figure 2: Axial MRI shows a lesion in nasopharynx.

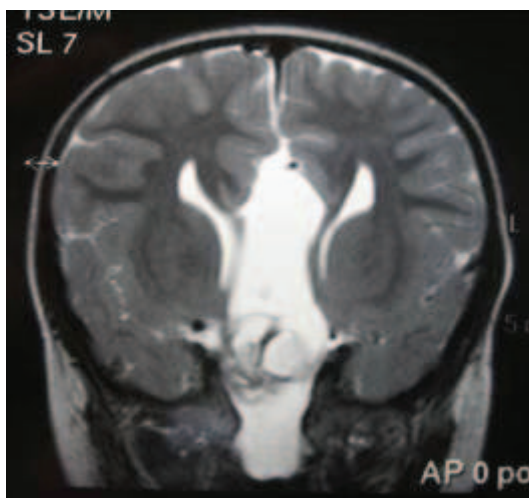


Figure 3: Coronal MRI shows an intracranial lesion with extension to nasopharynx.

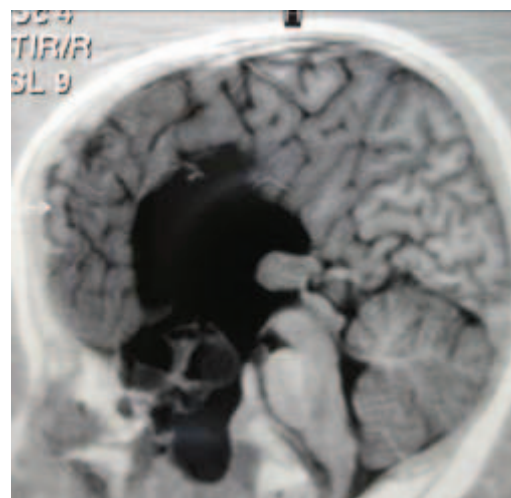


Figure 4: Sagittal MRI shows a large sphenoethmoidal encephalocele.

anomaly, CSF rhinorrhea and meningitis.¹

Association of agenesis of corpus callosum and median cleft lip and cleft palate was also reported.⁵

The combination of cleft lip and cleft palate, anophthalmos, congenital nystagmus, absent vomer bone and mental-motor retardation (Fryns' anophthalmia-plus syndrome) has been described.⁶

The most widely accepted theory to explain basal encephalocele lies in defective ossification of the body of the sphenoid bone with persistence of the craniofacial canal. Herniation through the floor of the sella turcica occurs before the 10th week of gestation.¹

Upper airway obstruction caused by a mass in the nasal cavity should be differentiated from a nasal polyp. Encephalocele is a pulsatile mass located medially to the nasal septum and widens the nasal bridge. A nasal polyp does not pulsate, is located laterally, emanates from the turbinate, and does not widen the nasal bridge.²

Encephalocele is definitively diagnosed by imaging examination. Computed tomography (CT), including three dimensional reconstruction, or MRI provide precise information about the position of cranial bony defect and the content of the cystic mass. They are valuable in determining the need for, and planning the extent of craniofacial reconstruction.²

After thorough evaluation, the definite management of encephalocele is surgical intervention. Most authors agree that encephalocele should be managed in the first few months of life. This makes the identification of the intracranial connection technically easier and allows more complete repair of dural defect.⁷

When there is a cleft palate, it is possible to repair the encephalocele through a transoral, transpalatal approach, preserving and repositioning of the content of the sac.⁴

Conclusion

Basal encephalocele is a rare disease. It is associated with facial midline deformities such

as oral cleft. When it protrudes into the nasal cavity, it can lead to upper airway obstruction. Maltreatment of the nasal mass may result in meningitis. We suggest that a basal encephalocele should be considered in the differential diagnoses of nasopharyngeal masses in children with facial midline deformity and upper airway obstruction. Unnecessary manipulation of such masses should be avoided because of increased risk of meningitis.

Conflict of Interest: None declared

References

- 1 Teng E, Heller J, Lazareff J, et al. Caution in treating transsphenoidal encephalocele with concomitant moyamoya disease. *J Craniofac Surg* 2006; 17: 1004-9.
- 2 Shimizu T, Kitamura S, Kinouchi K, Fukumitsu K. A rare case of upper airway obstruction in an infant caused by basal encephalocele complicating facial midline deformity. *Paediatr Anaesth* 1999; 9: 73-6.
- 3 Forrester MB, Merz RD. Structural birth defects associated with oral cleft in Hawaii, 1986 to 2001. *Cleft Palate Craniofac J* 2006; 43: 356-62.
- 4 Lewin ML. Sphenoethmoidal cephalocele with cleft palate: transpalatal versus transcranial repair. Report of two cases. *J Neurosurg* 1983; 58: 924-31.
- 5 Sakoda K, Ishikawa S, Uozumi T, et al. Sphenoethmoidal meningoencephalocele associated with agenesis of corpus callosum and median cleft lip and palate. Case report. *J Neurosurg* 1979; 51: 397-401.
- 6 Ozçelik D, Sağlam I, Sılan F, et al. Anophthalmia, cleft lip/palate, absent vomer bone, nystagmus, and mental-motor retardation: a new syndrome or Fryns "anophthalmia-plus" syndrome? *Cleft Palate Craniofac J* 2008; 45: 256-60.
- 7 Charles WC. Congenital malformation of nose. In Flint P, editor: Cummings otolaryngology Head and Neck Surgery. vol 4. 2005. p. 4099-109.