

Nasal Septal Abscess as a Complication of COVID-19 Nasal Swab Test: A Case Report

Reza Pourmohammadi¹, MD; Leila Asadpour², MD

¹Department of Ophthalmology, Darab Hospital, Shiraz University of Medical Sciences, Shiraz, Iran;

²Department of Otorhinolaryngology, Darab Hospital, Shiraz University of Medical Sciences, Shiraz, Iran

Correspondence:

Leila Asadpour, MD;
No.7, Zohreh Alley, 22-Bahman St., Postal code: 74819-14965, Darab, Iran
Tel/Fax: +98 31 37294005
Email: Leilaasadpour35@gmail.com
Received: 06 April 2021
Revised: 08 July 2021
Accepted: 28 September 2021

Abstract

Nasal swab tests are widely used to screen for coronavirus disease 2019 (COVID-19). Pain, discomfort, and the urge to sneeze are the most common complications of this screening method. We report a case of a 55-year-old female patient with beta-thalassemia major suffering from a nasal septal abscess (NSA) as a complication of a COVID-19 nasal swab test. Following the test, the patient only had mild nasal congestion. However, three days later, her clinical condition deteriorated, and she developed fever, and her level of consciousness decreased to lethargy and drowsiness. Physical examinations revealed a bilateral nasal abscess. She underwent surgical intervention, and the abscess was removed. For the first time in Iran, a case of NSA after a COVID-19 nasal swab test is reported. It is strongly recommended to exercise caution while performing nasal swab tests, especially in the elderly and patients at risk of bleeding or hemoglobinopathy.

Please cite this article as: Pourmohammadi R, Asadpour L. Nasal Septal Abscess as a Complication of COVID-19 Nasal Swab Test: A Case Report. Iran J Med Sci. 2023;48(1):102-105. doi: 10.30476/ijms.2021.90473.2143.

Keywords • COVID-19 • Abscess • Thalassemia

Introduction

Coronaviruses are a large family of viruses that range from the common cold virus to infectious agents such as severe acute respiratory syndrome (SARS).¹ In late 2019, a novel SARS coronavirus 2 (SARS-CoV-2) was identified in Wuhan (Hubei, China), which triggered a global health crisis.² In early 2020, after the death toll from SARS-CoV-2 infection exceeded 1,000 people, the World Health Organization (WHO) officially labeled the associated disease as coronavirus disease 2019 (COVID-19).³ The virus is believed to infect both humans and animals. The most common clinical manifestations of COVID-19 are fever, fatigue, dry cough, myalgia, shortness of breath, and gastrointestinal complications such as diarrhea and vomiting.⁴

Various methods have been used to diagnose COVID-19. Chest computed tomography (CT) has been used to identify affected patients with pulmonary involvement, and more recently, to identify lung lesions related to COVID-19. Laboratory techniques have been widely used to diagnose asymptomatic COVID-19 patients or carriers. Antibody testing and direct sampling from the nasopharyngeal mucosa, to obtain a specimen from nasal mucosa, are the most common COVID-19 screening techniques.⁵ Pain, discomfort, and the urge to sneeze or cough are the most common complications of nasal swabs. To date, no serious complications related to the COVID-19 sampling nasal swab test have been recorded.⁶ We herein report a female patient

What's Known

- Nasal swab tests are widely used to screen for coronavirus disease 2019.
- To date, no major complications after a nasal swab test have been reported.

What's New

- For the first time in Iran, a case of nasal septal abscess after a nasal swab test is reported.
- It is strongly recommended to exercise caution while performing nasal swab tests, especially in the elderly and patients at risk of bleeding or hemoglobinopathy.

with the diagnosis of a nasal septal abscess (NSA) after nasal swab testing for COVID-19.

Case Presentation

In 2020, a 55-year-old Iranian woman was referred to our medical center at Darab Hospital (Darab, Iran) with complaints of malaise, body aches, and dry cough. The patient was single, worked as a housekeeper, and had a middle socio-economic status. In terms of medical history, she had chronic anemia and was treated for thalassemia major; otherwise, she had no other specific health issues. Her medication history included weekly blood transfusion and maintenance treatment with desferrioxamine (Ronak Daru, Iran). In terms of family history, her brother died of thalassemia major about 50 years ago at the age of five. Initial physical examinations showed that the patient was pale, and her vital signs were abnormal. Her heart rate was 115 beats/min, respiratory rate 22 breaths/min, blood pressure 135/88 mmHg, oral body temperature 37.6 °C, and capillary oxygen saturation 95%. Physical examination findings of the neck, heart, lungs, abdomen, and limbs were unremarkable. A chest CT scan was performed indicating bilateral diffused patchy infiltration suggesting SARS-CoV-2 infection. Laboratory results showed anemia (hemoglobin: 6.5 mg/dL) and leukocytosis (white blood cell: 15,300 mg/dL). The result of the COVID-19 nasal swab test upon admission was negative. However, due to high suspicion of COVID-19 and the presence of anemia and hemoglobinopathy, she was transferred to an isolation room in the COVID-19 section of the emergency department. Ceftriaxone 250 mg (Exir Pharmaceutical Co., Iran) and interferon 250 mg (CinnaGen Co., Iran) were administered subcutaneously every other day. After five days of isolation, she was transferred to an internal ward. Following the COVID-19 test, she had mild nasal congestion but otherwise, there were no complications. However, after three days in the internal ward, her clinical condition worsened, fever was detected (oral temperature: 38.1 °C), and her level of consciousness decreased to lethargy and drowsiness. Physical examination did not reveal any signs of an infection. It should be noted that no physical examination was performed on her face and nasal area, and she wore face masks during hospitalization. Combination therapy with vancomycin and meropenem (both from Exir Pharmaceutical Co., Iran) was initiated, and her clinical condition improved within four days. After two weeks of hospitalization, the patient was discharged. At the time of discharge, her vital signs were stable, capillary oxygen saturation was 95%, and physical examination findings were normal.

Five days after hospital discharge, she was referred to our otolaryngology clinic following two episodes of epistaxis. Physical examination of the nasal cavity revealed bilateral NSA (figure 1) for which immediate surgical intervention was initiated. Lidocaine 1% (Aburaihan Pharmaceutical Co., Iran) and epinephrine 1/100,000 (Iran Hormone Pharmaceutical Co., Iran) were injected at the site of the abscess under general anesthesia. A 1.5 cm incision was made on the caudal septum and almost 10 cc of purulent material was removed. Necrosis of nasal cartilages was observed requiring the removal of necrotized tissue and cartilage. The abscess site was then washed carefully using normal saline 0.9%. A small penrose drain was inserted and fixed with a single nylon suture. Quilting sutures were performed using Vicryl 4-0. Bilateral internal splits and tetracycline mesh was inserted. The patient was then discharged from our medical center and clindamycin 300 mg tablets (every eight hours), normal saline serum for a nasal wash, and tetracycline topical ointment were prescribed. The mesh was removed after 48 hours, the drain after 72 hours, and the splits after seven days. After two weeks, no abscesses or complications were observed (figure 2). The patient was followed up for two months during which no further issues were reported. Written informed consent was obtained from the patient for the publication of this case report.

Discussion

A patient with thalassemia major who developed NSA after a COVID-19 nasal swab test is presented. Nowadays, nasal swab testing is commonly used to detect SARS-CoV-2, and

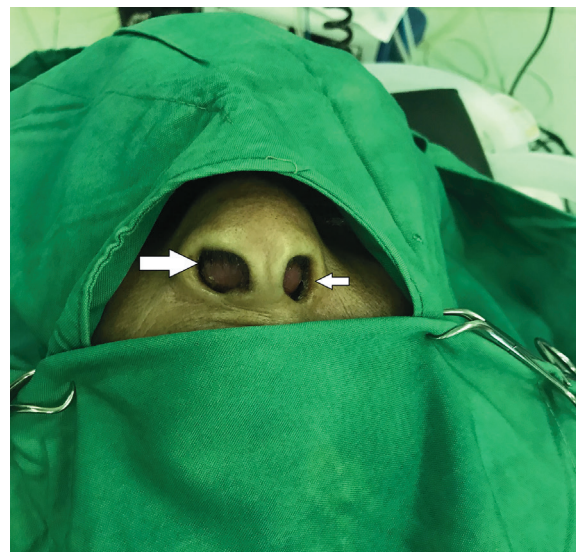


Figure 1: Bilateral nasal septal abscess was observed before the surgical intervention.

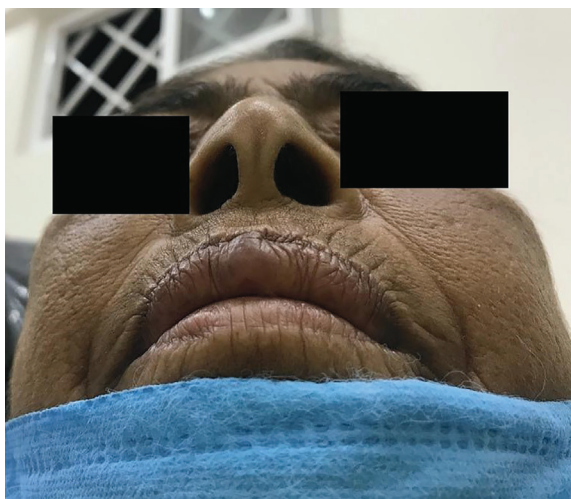

Figure 2: Significant improvement was observed two weeks after the removal of nasal abscesses.

complications are not common. However, the procedure is relatively safe, there are some reports of complications.

In a retrospective study of 4,876 cases, Fabbris and colleagues evaluated complications from oral or nasal swab testing for SARS-CoV-2 screening. They reported that 0.16% of all cases undergone nasal swab testing required otolaryngologic assessment for complications. Moderate anterior epistaxis (n=3), broken and impacted swabs in the nasal cavity (n=2), NSA (n=1), and severe anterior and posterior bleeding from an arterial point of the olfactory area (n=1) were observed among the study population.⁷ In another study, as a rare complication, Mughal and colleagues reported a case of premature engagement of a viral swab breakpoint, resulting in impaction in the nasal cavity.⁸ Föh and colleagues conducted a systematic review of 11,476 swab procedures and reported only three (0.026%) adverse events, namely the break of a nasal swab by triggering the swab's breakpoint mechanism, severe epistaxis needing medical help, and cerebrospinal fluid leak requiring endoscopic surgical repair.⁹ Koskinen and others retrospectively screened 643,284 cases for complications after COVID-19 nasal swab testing. They reported eight cases with complications immediately after sampling, namely nasal bleeds (n=4) and broken swabs (n=4). They reported the frequency of complications requiring treatment was 1.24 per 100,000 performed COVID-19 tests. Despite the low number, they emphasized the importance of the correct implementation of sampling techniques to avoid complications.¹⁰

As a rare complication of the nasal swab test, we report a case of NSA in a patient with thalassemia major. We believe that this is a rare

but highly possible complication in cases with baseline hematologic diseases, and the insertion of a nasal swab was associated with injuries to the nasal mucosa. Some previous studies have reported intracranial hemorrhage and hematoma in patients with beta-thalassemia major. Some cases of splenic and liver abscesses in patients with thalassemia major, as a secondary infection, have also been reported.¹¹⁻¹⁴ Abshirini and colleagues also reported a case of a patient with thalassemia major diagnosed with idiopathic NSA without any history of trauma.¹⁵ They recommended further research on a possible association between NSA and thalassemia major.

Conclusion

For the first time in Iran, a case of NSA as a complication of a COVID-19 nasal swab test is reported. NSA is treated as an emergency in otolaryngology, and intracranial infections are life-threatening. It is strongly recommended to exercise caution while performing nasal swab tests, especially in the case of the elderly and patients at risk of bleeding or hemoglobinopathy.

Acknowledgment

We would like to thank the Medical Records Department of Darab Hospital and Dr. A. Rafiee-Zadeh for providing the patient information. We also express our gratitude to the patient for her cooperation.

Conflict of Interest: None declared.

Author's Contribution

R.P: Contributed to the conception and design of the work, drafting the work; L.A: Contributed to design of the work, revising the work critically for important intellectual content. All authors have read and approved the final manuscript and agree to be accountable for all aspects of the work in ensuring that questions related to the accuracy or integrity of any part of the work are appropriately investigated and resolved.

References

- 1 The Novel Coronavirus Pneumonia Emergency Response Epidemiology T. The Epidemiological Characteristics of an Outbreak of 2019 Novel Coronavirus Diseases (COVID-19) - China, 2020. *China CDC Wkly.* 2020;2:113-22. PubMed PMID: 34594836; PubMed Central PMCID: PMCPCMC8392929.
- 2 Cao J, Tu WJ, Cheng W, Yu L, Liu YK, Hu X,

- et al. Clinical Features and Short-term Outcomes of 102 Patients with Coronavirus Disease 2019 in Wuhan, China. *Clin Infect Dis*. 2020;71:748-55. doi: 10.1093/cid/ciaa243. PubMed PMID: 32239127; PubMed Central PMCID: PMC7184479.
- 3 Andersen KG, Rambaut A, Lipkin WI, Holmes EC, Garry RF. The proximal origin of SARS-CoV-2. *Nat Med*. 2020;26:450-2. doi: 10.1038/s41591-020-0820-9. PubMed PMID: 32284615; PubMed Central PMCID: PMC7095063.
 - 4 Cascella M, Rajnik M, Aleem A, Dulebohn SC, Di Napoli R. Features, Evaluation, and Treatment of Coronavirus (COVID-19). *StatPearls*. Treasure Island (FL). 2022.
 - 5 Patel MR, Carroll D, Ussery E, Whitham H, Elkins CA, Noble-Wang J, et al. Performance of Oropharyngeal Swab Testing Compared With Nasopharyngeal Swab Testing for Diagnosis of Coronavirus Disease 2019-United States, January 2020-February 2020. *Clin Infect Dis*. 2021;72:403-10. doi: 10.1093/cid/ciaa759. PubMed PMID: 33527126; PubMed Central PMCID: PMC7337670.
 - 6 Tang YW, Schmitz JE, Persing DH, Stratton CW. Laboratory Diagnosis of COVID-19: Current Issues and Challenges. *J Clin Microbiol*. 2020;58. doi: 10.1128/JCM.00512-20. PubMed PMID: 32245835; PubMed Central PMCID: PMC7269383.
 - 7 Fabbris C, Cestaro W, Menegaldo A, Spinato G, Frezza D, Vijendren A, et al. Is oro/nasopharyngeal swab for SARS-CoV-2 detection a safe procedure? Complications observed among a case series of 4876 consecutive swabs. *Am J Otolaryngol*. 2021;42:102758. doi: 10.1016/j.amjoto.2020.102758. PubMed PMID: 33125901; PubMed Central PMCID: PMC7553130.
 - 8 Mughal Z, Luff E, Okonkwo O, Hall CEJ. Test, test, test - a complication of testing for coronavirus disease 2019 with nasal swabs. *J Laryngol Otol*. 2020;134:646-9. doi: 10.1017/S0022215120001425. PubMed PMID: 32641170; PubMed Central PMCID: PMC7387789.
 - 9 Foh B, Borsche M, Balck A, Taube S, Rupp J, Klein C, et al. Complications of nasal and pharyngeal swabs: a relevant challenge of the COVID-19 pandemic? *Eur Respir J*. 2021;57. doi: 10.1183/13993003.04004-2020. PubMed PMID: 33303542; PubMed Central PMCID: PMC7736753
 - 10 Koskinen A, Tolvi M, Jauhainen M, Kekalainen E, Laulajainen-Hongisto A, Lamminmaki S. Complications of COVID-19 Nasopharyngeal Swab Test. *JAMA Otolaryngol Head Neck Surg*. 2021;147:672-4. doi: 10.1001/jamaoto.2021.0715. PubMed PMID: 33914064; PubMed Central PMCID: PMC8085764.
 - 11 Al-Hawsawi ZM, Hummida TI. Splenic abscess in childhood B-Thalassemia Major. *Saudi Med J*. 2002;23:345-7. PubMed PMID: 11938432.
 - 12 Nnaoma C, Ruberwa J, Chika-Nwosuh OZ, Pal C, Quintilliani SB. 3197 Pyogenic Liver Abscess in B-Thalassemia: A Case Report. *Official journal of the American College of Gastroenterology| ACG*. 2019;114:S1708. doi: 10.14309/01.ajg.0000602320.08625.dc.
 - 13 Haidar R, Mhaidli H, Taher AT. Paraspinal extramedullary hematopoiesis in patients with thalassemia intermedia. *Eur Spine J*. 2010;19:871-8. doi: 10.1007/s00586-010-1357-2. PubMed PMID: 20204423; PubMed Central PMCID: PMC2899982.
 - 14 Aessopos A, Politou M, Farmakis D, Sideris P, Grapsa A, Eopoulos AA, et al. Staphylococcus aureus Abscess of the Spleen in a β -Thalassemia Patient. *Scandinavian Journal of Infectious Diseases*. 2002;34:466-8. doi: 10.1080/00365540110076949.
 - 15 Abshirini H, Lotfinia M, Namazi MJ, Reza-soltani M, Mohammad A, Mofrad E. Idiopathic Nasal Septal Abscess in Patient with Thalassemia Major: A Case Report. *Indian Journal of Forensic Medicine & Toxicology*. 2019;13:415. doi: 10.5958/0973-9130.2019.00233.0.