

Effect of Selenium on Quantitative Structural Changes in Dexamethasone-Induced Immunodeficiency Rat Models

Farzaneh Dehghani^{1,2}, PhD;^{ORCID}
Seyed-Abdolreza Hossieni², MSc;
Ali Noorafshan^{1,2}, PhD; Mohammad
Reza Panjehshahin³, PhD; Tahereh
Esmailpour², PhD^{ORCID}

¹Histomorphometry and Stereology
Research Center, Shiraz University of
Medical Sciences, Shiraz, Iran;

²Department of Anatomical Sciences,
School of Medicine, Shiraz University of
Medical Sciences, Shiraz, Iran;

³Department of Pharmacology, School of
Medicine, Shiraz University of Medical
Sciences, Shiraz, Iran

Correspondence:

Tahereh Esmailpour, PhD;
Department of Anatomical Sciences,
School of Medicine, Zand Blvd., Postal
code: 71348-45794, Shiraz, Iran.

Tel/Fax: +98 71 32084277

Email: esmaeil@sums.ac.ir

Received: 03 May 2019

Revised: 02 July 2019

Accepted: 21 July 2019

What's Known

- Dexamethasone is an anti-inflammatory synthetic glucocorticoid, which induces lymphoid organ atrophy. Selenium has been proved to have immunomodulatory effects and prevent immunodeficiency induced by dexamethasone.
- Measuring the structural properties of lymphoid organs can be effective in assessing the rate of disease recovery or progression.

What's New

- We are the first to estimate quantitative structural changes in lymphoid organs by using dexamethasone as immunodeficiency and selenium as immunomodulatory agents.
- Lymphoid structures containing B lymphocytes are affected more than lymphoid structures containing T lymphocytes in both immunodeficiency and immunomodulatory states.

Abstract

Background: One of the major indices of immunodeficiency is lymphoid organ atrophy. Some trace elements are candidates for the treatment of this defect. These conditions may induce structural changes in the sub-components of lymphoid organs. Therefore, this study evaluated the effect of selenium on volumetric changes in dexamethasone (DEX)-induced lymphoid organ atrophy in an animal model.

Methods: This study was conducted at Histomorphometry and Stereology Research Centre, Shiraz University of Medical Sciences, Shiraz, Iran, in September 2016 to September 2017. Thirty-two male rats were divided into four groups: Group I; control (normal saline, 0.5 mL/kg, intraperitoneally), Group II; DEX (0.4 mg/kg; intraperitoneally), Group III; selenium plus DEX (similar to Group II and Group IV), and Group IV; selenium (0.1 mg/kg; orally). At the end of the experiment, the rats' thymus, spleen, and lymph nodes were removed, processed, and stained by hematoxylin and eosin (H&E). The volume and volume density of these organs were estimated by stereology. The results were analyzed using the Mann–Whitney *U*-test and the Kruskal–Wallis test.

Results: The volume of the thymus as well as its cortex and medulla; the volume of the spleen as well as the volume density of its white pulp, periarterial lymphatic sheath zone, and follicles; and the volume of the lymph nodes as well as their inner ($P=0.001$) and outer ($P=0.007$) cortices showed a significant reduction in the DEX-treated animals in comparison with the controls. In the DEX plus selenium-treated animals, maximum effects were observed on the increment in the thymic cortex ($P=0.001$), the outer cortex of the lymph nodes ($P=0.012$), and the splenic follicles ($P=0.018$) in comparison with the DEX group. There was no significant difference between the animals receiving selenium treatment and the controls in terms of lymphoid organs.

Conclusion: Selenium may improve lymphoid organ structures in an immunodeficiency rat model but has no effect on normal lymphoid tissues.

Please cite this article as: Dehghani F, Hossieni SA, Noorafshan A, Panjehshahin MR, Esmailpour T. Effect of Selenium on Quantitative Structural Changes in Dexamethasone-Induced Immunodeficiency Rat Models. *Iran J Med Sci.* 2021;46(2):128-135. doi: 10.30476/ijms.2020.81137.0.

Keywords • Dexamethasone • Selenium • Lymphoid tissue

Introduction

The structural features of lymphoid organs indicate the efficient functioning of the immune system.¹ Lymphoid organ

atrophy and lymphocyte apoptosis should be considered during such conditions as stress, disease, chemotherapy, and the long-term use of drugs such as glucocorticoids. These factors may induce lymphocyte apoptosis and lymphoid organ atrophy^{2, 3} and probably lead to immunodeficiency.⁴ Thus, lymphoid organs undergo prominent structural changes after exposure to these factors.⁵ Dexamethasone (DEX) is an anti-inflammatory synthetic glucocorticoid that induces lymphoid organ atrophy.^{2, 3} DEX has been shown to reduce the structural components of the spleen, especially the white pulp and the periarterial lymphatic sheath (PALS) zone.^{3, 6} Histo-morphometric studies of lymphoid tissues demonstrated that DEX also caused not only a reduction in the thymic cortex-medulla ratio but also atrophy in lymph nodes, particularly in the paracortical zone.^{3, 7} The thymus, spleen, and lymph nodes have various components that play roles in specific immune functions. These components include the cortex and medulla of the thymus; the cortex (outer and inner zones) and medulla of the lymph node; and the red pulp (composed of the splenic cord and the *sinusoids*), white pulp (composed of the PALS zone and follicles), capsule, and *trabeculae* of the spleen.⁸⁻¹⁰ Many herbs, bacterial toxins, and chemical elements such as selenium are immunomodulators and are suggested to prevent immunodeficiency.¹¹⁻¹³

Selenium is an essential element that induces lymphocyte proliferation and antibody response.¹⁴ It plays an important role in alleviating lymphoid organ injury.¹⁶ Dimensional variations in the thymus, spleen, and lymph nodes reflect the efficient functioning of these organs.

Quantitative evaluations of the volume of these components can provide comparable and reliable data. Stereological methods can be used to evaluate and record quantitative structural changes in the lymphoid sub-components.¹⁷ Briefly, the present study was conducted to quantitatively estimate the volume of the thymus, spleen, and lymph nodes and their sub-components after exposure to DEX and selenium in a rat model.

Materials and Methods

This study was conducted at Histo-morphometry and Stereology Research Centre, Shiraz University of Medical Sciences, Shiraz, Iran, in September 2016 to September 2017. The present animal experiment was carried out under the supervision of the Ethics Committee of Shiraz University of Medical Sciences (Approval No: IR.SUMS.REC.1388.S4559).

Sprague-Dawley rats, weighing 230–250 g, were obtained from the Laboratory Animal Center of Shiraz University of Medical Sciences. The rats were maintained under standard conditions and given ad libitum access to food and water.¹⁸

Drug Preparation

DEX was purchased from Osvah Pharmaceutical Company (Tehran, Iran), and selenium was prepared from Merck Company (Darmstadt, Germany).

Animals

Thirty-two male rats were randomly assigned to four groups of eight. Group I (control) was given 0.5 mL/kg of normal saline intraperitoneally for three days and then orally for 30 days; Group II was administered 0.4 mg/kg/d of DEX intraperitoneally for three days; Group III was given 0.1 mg/kg/0.5 mL/d of selenium orally for 30 days plus 0.4 mg/kg/d of DEX intraperitoneally for three days; and Group IV was administered 0.1 mg/kg/0.5 mL/d of selenium orally for 30 days.^{19, 20}

At the end of the experiment, the animals were sacrificed under deep anesthesia with ether. Then, their thymus, spleen, and superficial inguinal lymph nodes were removed. The tissues were weighed on a microbalance sensitive to 0.01 g (Scaltec, Heiligenstadt, Germany). The primary volumes of the thymus, spleen, and lymph nodes were estimated by the immersion method.²¹ Afterwards, the tissues were fixed in 10% buffer formaldehyde (Sigma-Aldrich, St. Louis, MO, USA) at room temperature for 72 hours.

Stereological Study

The orientator method was used to obtain isotropic uniform random sections.²² To this end, the thymus, spleen, and lymph nodes were placed on a circle divided into 10 equal distances. A random number between 0 and 10 was selected, and the tissue was sectioned into two halves, with a blade in that direction. The cut surface of each half of the tissue was placed on the 0-0 direction of the second circle with 10 unequal cosine-weighted divisions, and the second cuts were made. A total of 8–10 slabs were collected from each organ, and one circle was punched from each slab using a trocar (thickness 2). The diameters and areas of the circular pieces were measured (figure 1). The cut surfaces of the slabs and circular pieces were embedded in soft paraffin and 5- μ m sections were prepared. The sections were stained by hematoxylin and eosin (H&E). In the post fixing, the area of the circular piece was measured again. This method was suitable for the prevention of shrinkage.

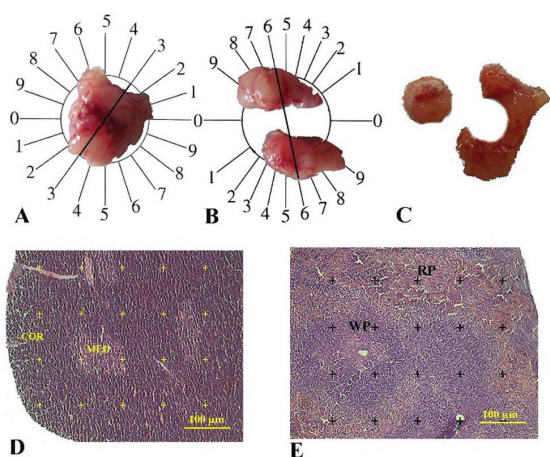


Figure 1: The photomicrograph of the rat spleen stained by hematoxylin and eosin (H&E) and sectioned by the orientator method to obtain isotropic uniform random (IUR) sections is displayed. A) The spleen was placed at the center of the circle divided into equal distances. Each part of the sectioned tissue was placed on a second circle with unequal divisions. B) In this section, another number was selected and the tissue was sectioned into slabs. C) In this part, the remaining portion of the tissue was vertically placed on the same circle and sectioned into slabs in a new direction. D and E) The volumes of the different components of the thymus and spleen were estimated respectively, by the point-counting method.

The volume shrinkage was calculated via the following formula:²³

$$\text{volume shrinkage} = 1 - (AA/AB)^{1.5}$$

where AA and AB are the areas of the circular piece after and before processing by sectioning and staining, respectively. The final volume of the tissue was estimated via the following formula:²⁴

$$V_{\text{final}} = V_{\text{primary}} \times (1 - \text{volume shrinkage})$$

Each sample section was analyzed using a video-microscopy system that consisted of a microscope (E-200, Nikon, Tokyo, Japan) linked to a video camera (SSC, Sony, Tokyo, Japan), a computer, and a flat-screen monitor (LG, South Korea). Each parameter was estimated by examining 10–14 microscopic fields per each thymus, spleen, and lymph node by point-counting method (figures 1 and 2). Microscopic fields were selected by systematic random sampling method in which the slide at equal intervals along the X and Y axes were moved, using a stage micrometer. By means of a stereology software tool designed by our university, relevant grids (point grid) were overlaid on the monitor. The volume density of the different components per unit volume of the reference tissue $Vv_{\text{component/final}}$ was estimated via the point-counting method and the following formula:²⁴

$$Vv_{\text{component/final}} = \frac{P_{\text{component}}}{P_{\text{final}}}$$

where $P_{\text{component}}$ and P_{final} are the points

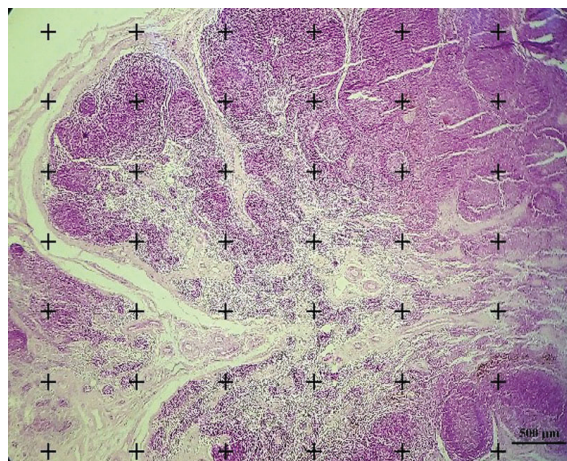


Figure 2: The total volume of the lymph nodes and the volumes of their cortex and medulla were estimated by the point-counting method (500×, hematoxylin and eosin [H&E]).

hitting the favored component and the whole tissue, respectively.

The total volume of the components was obtained by multiplying the volume density by $V_{\text{final}}^{\text{24}}$

$$V_{\text{component}} = Vv_{\text{component/reference}} \cdot V_{\text{final}}$$

Statistical Analysis

The results were analyzed using the Kruskal–Wallis test and the Dunn test. A P value of less than 0.05 was considered statistically significant. The data were analyzed using SPSS statistical software, version 15, (SPSS, Chicago, IL, USA).

Results

Volumes of the Thymus and Its Cortex and Medulla

The volumes of the thymus, thymic cortex, and thymic medulla in the DEX-treated rats were decreased by 55%, 64%, and 37%, correspondingly, on average in comparison with the control animals (P=0.001) (table 1), indicating that the reduction in the thymic volume was associated more with the volume of the thymic cortex.

The administration of selenium to the DEX-treated rats increased in the total volume of the thymus (37.6%) and its cortex (80.5%) by comparison with the DEX group (P=0.001); however, the volume of the thymic medulla remained unchanged. The volumes of the thymic cortex and medulla were not affected by the administration of selenium alone to the normal rats (table 1).

Volumes of the Spleen and its Histological Sub-components

The total volume of the spleen, as well as the

Table 1: Effects of DEX and selenium on the total volume of the thymus as well as the volumes of its cortex and medulla in the control and experimental groups (mean±SD, n=8)

Volume	Groups Control	DEX	P value ^a	DEX+Se	P value ^b	Se	P value ^c
Total (mm ³)	292.00±0.05	131.50±0.03	0.001 [*]	180.90±0.02	0.001 [*]	290.00±3.0	0.080
Cortex (mm ³)	201.10±0.05	74.30±0.01	0.001 [*]	134.10±0.02	0.001 [*]	200.00±1.53	0.085
Medulla (mm ³)	91.30±0.01	57.10±0.02	0.001 [*]	46.70±0.01	0.001 [*]	92.00±1.2	0.121

^a Comparison between the normal control group and the DEX group; ^b Comparison between the DEX+ Se group and the DEX group; ^c Comparison between the Se group and the normal control group; * A P value<0.05 was considered statistically significant. Kruskal–Wallis test and Dunn test were used to determine statistically significant differences between the groups. DEX: Dexamethasone; Se: Selenium

Table 2: Effects of DEX and selenium on the total volume of the spleen and its components in the control and experimental groups (mean±SD, n=8)

Volume	Groups Control	DEX	P value ^a	DEX+Se	P value ^b	Se	P value ^c
Total (mm ³)	825.00±0.13	547.30±0.10	0.001 [*]	551.00±6.10	0.084	823.00±4.10	0.189
Red pulp (mm ³)	689.00±0.14	684.00±7.40	0.076	687.00±0.02	0.27	687.00±2.79	0.062
White pulp (mm ³)	100.00±0.02	29.00±0.02	0.001 [*]	52.00±0.01	0.001 [*]	96.00±8.10	0.184
PALS (mm ³)	3.50±0.45	1.20±0.60	0.001 [*]	1.50±5.00	0.295	3.40±0.22	0.581
(mm ³)	12.50±4.80	3.30±1.20	0.001 [*]	5.50±2.00	0.018 [*]	10.00±0.50	0.162
Chord (mm ³)	27.00±0.15	26.00±1.40	0.064	26.01±0.07	0.984	26.30±1.00	0.07
Sinusoid (mm ³)	57.00±1.10	55.80±1.30	0.066	55.30±0.14	0.297	55.90±1.20	0.076

^a Comparison between the normal control group and the DEX group; ^b Comparison between the DEX+ Se group and the DEX group; ^c Comparison between the Se group and the normal control group; * A P value<0.05 was considered statistically significant. Kruskal–Wallis test and Dunn test were used to determine statistically significant differences between the groups. DEX: Dexamethasone; Se: Selenium; PALS: Periaarterial lymphatic sheaths

volumes of its white pulp, follicles, and PALS region, showed a reduction in the DEX-treated rats in comparison with the control animals (P=0.001). DEX had maximum side effects on the white pulp and follicles compared with the PALS region. There were no significant changes in the red pulp, chord, and sinusoids (table 2). No changes were observed in the DEX-treated rats that were given selenium in terms of the volume of all splenic components except the white pulp (P=0.001) and its follicles (P=0.018) in comparison with the DEX-administrated animals (table 2). The administration of the selenium alone did not affect the volume of the sub-components of the spleen compared to the

control rats (table 2).

Volumes of the Lymph Nodes and Their Cortex and Medulla

The total volume of the lymph nodes (24.52%), as well as the volumes of their outer (P=0.007) and inner (P=0.001) cortices, showed a decrease in the DEX-treated rats in comparison with the controls. However, the volume of the medulla and its sub-components remained unchanged (table 3).

The administration of selenium to the DEX-treated rats increased the volume of the outer cortex (P=0.012) but failed to exert any effect on the volume of the inner cortex and the different

Table 3: Effects of DEX and Selenium on the total volume of the lymph nodes and the volumes of their sub-components in the control and experimental groups (mean±SD, n=8)

Volume	Groups Control	DEX	P value ^a	DEX+Se	P value ^b	Se	P value ^c
Total (mm ³)	8.93± 0.28	6.74±0.34	0.001 [*]	7.89±0.43	0.001 [*]	9.11±0.35	0.275
Cortex (mm ³)	6.30±0.33	4.27±0.37	0.001 [*]	5.83±0.49	0.001 [*]	6.50±0.39	0.286
Outer cortex (mm ³)	2.49±0.66	1.69±0.30	0.007 [*]	2.16±0.35	0.012 [*]	2.23±0.46	0.376
Inner cortex (mm ³)	3.90±0.35	2.64±0.45	0.001 [*]	2.95±0.45	0.189	4.24±0.57	0.179
Medulla (mm ³)	2.16±0.25	2.27±0.35	0.481	1.97±0.34	0.104	2.49±0.33	0.140
Medullary cord (mm ³)	2.18±0.43	1.98±0.29	0.293	2.08±0.26	0.479	2.35±0.37	0.410
Medullary sinus (mm ³)	0.28±0.04	0.29±0.02	0.537	0.28±0.02	0.334	0.30±0.02	0.226

^a Comparison between the normal control group and the DEX group; ^b Comparison between the DEX+ Se group and the DEX group; ^c Comparison between the Se group and the normal control group; * A P value < 0.05 was considered statistically significant. Kruskal–Wallis test and Dunn test were used to determine statistically significant differences between the groups. DEX: Dexamethasone; Se: Selenium

zones of the medulla. No significant changes were detected when selenium alone was administered to the normal rats concerning the volume of the lymph nodes and the structures of their sub-components.

Discussion

The findings of the present study showed that DEX lowered the volumes of all areas associated with the thymus, spleen, and lymph nodes, except for the red pulp, cords, and sinusoids of the spleen as well as the inner cortex and medulla of the lymph nodes. Selenium, as an immunomodulator, improved changes only in the cortex of the thymus, the white pulp of the spleen, and the outer cortex of the lymph nodes.

Lymphoid organs are highly organized structures that could be exposed to many intrinsic and extrinsic factors.^{4, 25} Lymphoid organ atrophy and lymphocyte apoptosis should be considered during long-term glucocorticoid therapy.^{26, 27} Our results showed that DEX reduced the total volume of the thymus in rats. The volume reduction was more prominent in the thymic cortex than was in the medulla. The cortex and medulla contain immature and mature T-cells, respectively.²⁸ Hussar and colleagues found that DEX induced immature T-cell apoptosis in the cortex of the thymus, while the change in the number of lymphocytes in the medulla was less significant.²⁰ It is estimated that approximately 90% of immature T-cells are eliminated by intrinsic factors normally, but DEX plays a major role in the expansion of the apoptosis pathway.⁴ Sensitivity to the excess of glucocorticoids on immature T-cell apoptosis was accompanied by markers of oxidative stress and mitochondrial dysfunction in a previous study.²⁹ It is thought that immature T-cells in the cortex are more sensitive to oxidative stress than are lymphocytes in the medulla.³⁰

We also found that DEX induced a reduction in the total volume of the spleen as well as the volumes of the splenic white pulp, follicles, and PALS zone, whereas it did not affect the splenic red pulp, cords, and sinusoids. The white pulp plays an important role in immune responses. It is divided into the PALS zone (numerous T-cells) and follicles (large numbers of B cells).³¹ Our results revealed a more pronounced impact by DEX on the follicles than on the PALS region. Some investigations have shown that DEX inhibits the proliferation of lymphocytes, induces focal necrosis, and reduces the size of lymphoid follicles.³² DEX appears to have more side effects on B lymphocytes than on T lymphocytes.

Among the rats in the current study, DEX

diminished the total volume of the lymph nodes as well as the volume of their cortex; nonetheless, the maximum effect was detected in the outer cortex compared with the control group. In this group, DEX had no effect on the volume of the medullary sub-components. The outer cortex contains a great number of B cells arranged in the follicles, while the inner cortex contains more diffuse mature T-cells. It appears that DEX induces its most negative effect on B cells.

The thymus atrophy in our DEX-treated rats may have been due to a reduction in the number of immature T-cells in the cortex; nevertheless, the change in the number of mature T-cells in the medulla was not significant.^{4, 20} In the spleen, follicular B cells are perhaps more sensitive to the excess of glucocorticoids than are the PALS T lymphocytes. Lymph node atrophy appears to be more in consequence of a reduced number of B cells in the outer cortex than a diminished number of T-cells in the inner cortex.³²

Among the animals in the current investigation, selenium had positive effects on the cortex of the thymus, the outer cortex of the lymph nodes, and the volumes of the white pulp and follicles of the spleen in the DEX-treated rats, whereas it did not affect the thymic medulla and the lymph nodes. In the DEX-administered animals, DEX also failed to impact on the splenic red pulp, cord, and sinusoids.

The atrophy in the lymphoid organs in the DEX-treated rats was likely secondary to a reduction in the number of lymphocytes. A reduction in the number of immature T-cells in the thymic cortex may reduce the volume of the thymus.^{4, 20} Follicular B cells were more sensitive to the excess of glucocorticoids than were mature T lymphocytes in the PALS region of the spleen and the inner cortex of the lymph nodes; still, the changes in the mature T-cells in the thymic medulla and the mature T-cells in the splenic PALS zone and the lymph node inner cortex were not significant.

Selenium may exert its effect through a mechanism involving free thiols, reduced conditions of oxidative stress, and enhanced proliferation of lymphocytes.³³ Hawkes and colleagues showed that selenium induced the proliferation of B lymphocytes and perhaps T-cells.³⁴ Kiremidjian-Schumacher and others also reported that selenium induced the proliferation of cytotoxic precursor cells.³⁵ Cheng and others reported that selenium increases the number of both B and T-cells.³⁶ It appears that the antioxidant properties of selenium induces immature T-cell proliferation in the cortex but has no effect on mature T-cells in the thymic medulla. We found that selenium stimulated

B-cell proliferation more than mature T-cell enhancement in the spleen and lymph nodes. In this investigation, the administration of selenium alone had no effect on the different structures of the lymphoid organs in normal rats. It is likely that selenium inhibits lymphoid organ atrophy in immunodeficiency conditions but has no effect on the normal structures of these tissues.

Our results suggest that selenium is an important element that prevents lymphoid organ atrophy in an immunodeficiency model. Additionally, it may increase the number of precursor T-cells in the thymic cortex and B lymphocytes in the white pulp of the spleen and the outer cortex of the lymph nodes.

In this study, it was not possible for us to measure all lymph nodes in the body of the animals. Therefore, we considered the average size of all the lymph nodes.

Conclusion

In light of the results of the present study, it may be concluded that the cortex of the thymus, the outer cortex of the lymph node, and the white pulp of the spleen are more sensitive to DEX than are the other sub-components of these lymphoid organs. Selenium may prevent the reducing effects of DEX on the cortex of the thymus, the outer cortex of the lymph node, and the follicles of the splenic white pulp. The application of antibodies for T and B cells is recommended for their identification and counting.

Acknowledgment

The authors would like to thank the Vice-Chancellorship, the Laboratory Animal Center, and the Histomorphometry and Stereology Research Center of Shiraz University of Medical Sciences. This study was supported by a grant (No. 88-4559) from Shiraz University of Medical Sciences. This manuscript is a part of a thesis by Mr. SA Hossieni.

Conflict of Interest: None declared.

References

- 1 Chaplin DD. Overview of the immune response. *J Allergy Clin Immunol.* 2010;125:S3-23. doi: 10.1016/j.jaci.2009.12.980. PubMed PMID: 20176265; PubMed Central PMCID: PMC3342028.
- 2 Jiang W, Li Y, Sun J, Li L, Li JW, Zhang C, et al. Spleen contributes to restraint stress induced changes in blood leukocytes distribution. *Sci Rep.* 2017;7:6501. doi: 10.1038/s41598-017-06956-9. PubMed PMID: 28747688; PubMed Central PMCID: PMC5529540.
- 3 Hussar P, Tokin I, Filimonova G, Hussar Ü. Dexamethasone-induced T-lymphocyte apoptosis in different lymphoid organs. *Papers on Anthropology.* 2011;20:117-27. doi: 10.12697/poa.2011.20.13.
- 4 Krüger K, Mooren FC. Exercise-induced leukocyte apoptosis. *Exercise immunology review.* 2014;20:117-34.
- 5 Goya RG, Console GM, Spinelli OM, Carino MH, Riccillo F, Corrons FJ. Glucocorticoid-induced apoptosis in lymphoid organs is associated with a delayed increase in circulating deoxyribonucleic acid. *Apoptosis.* 2003;8:171-7. doi: 10.1023/a:1022922726418. PubMed PMID: 12766477.
- 6 Mitevska E, Kostadinova-Petrova I, Kostovska N. Changes of Spleen in Wistar Rats Exposed to Therapeutic Doses of Dexamethasone and Medroxyprogesterone Acetate Evaluated by Stereological Parameters. *Pril (Makedon Akad Nauk Umet Odd Med Nauki).* 2015;36:13-25. doi: 10.1515/prilozi-2015-0074. PubMed PMID: 27442392.
- 7 van Vliet E, Melis M, van Ewijk W. The influence of dexamethasone treatment on the lymphoid and stromal composition of the mouse thymus: a flowcytometric and immunohistological analysis. *Cell Immunol.* 1986;103:229-40. doi: 10.1016/0008-8749(86)90086-9. PubMed PMID: 2879639.
- 8 Parker GA. *Immunopathology in toxicology and drug development.* New York: Springer; 2017.
- 9 Zdrojewicz Z, Pachura E, Pachura P. The Thymus: A Forgotten, But Very Important Organ. *Adv Clin Exp Med.* 2016;25:369-75. doi: 10.17219/acem/58802. PubMed PMID: 27627572.
- 10 Burrell BE, Ding Y, Nakayama Y, Park KS, Xu J, Yin N, et al. Tolerance and lymphoid organ structure and function. *Front Immunol.* 2011;2:64. doi: 10.3389/fimmu.2011.00064. PubMed PMID: 22566853; PubMed Central PMCID: PMC3342028.
- 11 Ataei N. Selenium can reduce the side effects of cisplatin as a chemotherapy drug. *Research in Pharmaceutical Sciences.* 2012;7:94.
- 12 Chauhan PS, Satti NK, Suri KA, Amina M, Bani S. Stimulatory effects of Cuminum cyminum and flavonoid glycoside on Cyclosporine-A and restraint stress induced immune-suppression in Swiss albino mice. *Chem Biol Interact.* 2010;185:66-72. doi: 10.1016/j.cbi.2009.12.010.

- 10.1016/j.cbi.2010.02.016. PubMed PMID: 20156427.
- 13 Donaldson DS, Williams NA. Bacterial toxins as immunomodulators. *Adv Exp Med Biol.* 2009;666:1-18. doi: 10.1007/978-1-4419-1601-3_1. PubMed PMID: 20054971.
 - 14 Pagmantidis V, Meplan C, van Schothorst EM, Keijer J, Hesketh JE. Supplementation of healthy volunteers with nutritionally relevant amounts of selenium increases the expression of lymphocyte protein biosynthesis genes. *Am J Clin Nutr.* 2008;87:181-9. doi: 10.1093/ajcn/87.1.181. PubMed PMID: 18175754.
 - 15 Avery JC, Hoffmann PR. Selenium, Selenoproteins, and Immunity. *Nutrients.* 2018;10. doi: 10.3390/nu10091203. PubMed PMID: 30200430; PubMed Central PMCID: PMC6163284.
 - 16 Chen K, Peng X, Fang J, Cui H, Zuo Z, Deng J, et al. Effects of dietary selenium on histopathological changes and T-cells of spleen in broilers exposed to aflatoxin B1. *Int J Environ Res Public Health.* 2014;11:1904-13. doi: 10.3390/ijerph110201904. PubMed PMID: 24518648; PubMed Central PMCID: PMC3945576.
 - 17 Vojdani Z, Dehghani F, Noorafshan A, Seyedi F, Bahaedini F. Stereological study of the morphine on the spleen. *Toxicology Letters.* 2006:S110. doi: 10.1016/j.toxlet.2006.06.232.
 - 18 Olfert ED, Cross BM, McWilliam AA. Guide to the care and use of experimental animals. Ottawa: Canadian Council on Animal Care; 1993.
 - 19 El-Shenawy SM, Hassan NS. Comparative evaluation of the protective effect of selenium and garlic against liver and kidney damage induced by mercury chloride in the rats. *Pharmacological reports.* 2008;60:199.
 - 20 Hussar P, Tokin I, Hussar U, Filimonova G, Suuroja T. Application of Photoshop-based image analysis and TUNEL for the distribution and quantification of dexamethasone-induced apoptotic cells in rat thymus. *Medicina (Kaunas).* 2006;42:504-12. PubMed PMID: 16816546.
 - 21 Scherle W. A simple method for volumetry of organs in quantitative stereology. *Mikroskopie.* 1970;26:57-60. PubMed PMID: 5530651.
 - 22 Mattfeldt T, Mall G, Gharehbaghi H, Moller P. Estimation of surface area and length with the orientator. *J Microsc.* 1990;159:301-17. doi: 10.1111/j.1365-2818.1990.tb03036.x. PubMed PMID: 2243364.
 - 23 Nyengaard JR. Stereologic methods and their application in kidney research. *J Am Soc Nephrol.* 1999;10:1100-23. PubMed PMID: 10232698.
 - 24 Gundersen HJ, Bendtsen TF, Korbo L, Marcussen N, Moller A, Nielsen K, et al. Some new, simple and efficient stereological methods and their use in pathological research and diagnosis. *APMIS.* 1988;96:379-94. doi: 10.1111/j.1699-0463.1988.tb05320.x. PubMed PMID: 3288247.
 - 25 Badowski M, Shultz CL, Eason Y, Ahmad N, Harris DT. The influence of intrinsic and extrinsic factors on immune system aging. *Immunobiology.* 2014;219:482-5. doi: 10.1016/j.imbio.2014.02.008. PubMed PMID: 24661721; PubMed Central PMCID: PMC4004698.
 - 26 Jeklova E, Leva L, Jaglic Z, Faldyna M. Dexamethasone-induced immunosuppression: a rabbit model. *Vet Immunol Immunopathol.* 2008;122:231-40. doi: 10.1016/j.vetimm.2007.11.011. PubMed PMID: 18199487.
 - 27 Haldar C, Rai S, Singh R. Melatonin blocks dexamethasone-induced immunosuppression in a seasonally breeding rodent Indian palm squirrel, *Funambulus pennanti*. *Steroids.* 2004;69:367-77. doi: 10.1016/j.steroids.2004.03.006. PubMed PMID: 15219786.
 - 28 Pearse G. Normal structure, function and histology of the thymus. *Toxicol Pathol.* 2006;34:504-14. doi: 10.1080/01926230600865549. PubMed PMID: 17067941.
 - 29 Tonomura N, McLaughlin K, Grimm L, Goldsby RA, Osborne BA. Glucocorticoid-induced apoptosis of thymocytes: requirement of proteasome-dependent mitochondrial activity. *J Immunol.* 2003;170:2469-78. doi: 10.4049/jimmunol.170.5.2469. PubMed PMID: 12594272.
 - 30 Safaeian L, Ghannadi A, Javanmard SH, Vahidian MH. The effect of hydroalcoholic extract of *Ferula foetida* stems on blood pressure and oxidative stress in dexamethasone-induced hypertensive rats. *Res Pharm Sci.* 2015;10:326-34. PubMed PMID: 26600859; PubMed Central PMCID: PMC4623621.
 - 31 Cesta MF. Normal structure, function, and histology of the spleen. *Toxicol Pathol.* 2006;34:455-65. doi: 10.1080/01926230600867743. PubMed PMID: 17067939.
 - 32 Garrido E, Gomariz RP, Leceta J, Zapata A. Effects of dexamethasone on the lymphoid organs of *Rana perezi*. *Dev Comp Immunol.* 1987;11:375-84. doi: 10.1016/0145-305x(87)90081-4. PubMed PMID: 3622888.
 - 33 Hoffmann FW, Hashimoto AC, Shafer LA,

- Dow S, Berry MJ, Hoffmann PR. Dietary selenium modulates activation and differentiation of CD4+ T-cells in mice through a mechanism involving cellular free thiols. *J Nutr.* 2010;140:1155-61. doi: 10.3945/jn.109.120725. PubMed PMID: 20375261; PubMed Central PMCID: PMC2869499.
- 34 Hawkes WC, Kelley DS, Taylor PC. The effects of dietary selenium on the immune system in healthy men. *Biol Trace Elem Res.* 2001;81:189-213. doi: 10.1385/BTER:81:3:189. PubMed PMID: 11575678.
- 35 Kiremidjian-Schumacher L, Roy M. Effect of selenium on the immunocompetence of patients with head and neck cancer and on adoptive immunotherapy of early and established lesions. *Biofactors.* 2001;14:161-8. doi: 10.1002/biof.5520140121. PubMed PMID: 11568453.
- 36 Cheng WH, Holmstrom A, Li X, Wu RT, Zeng H, Xiao Z. Effect of dietary selenium and cancer cell xenograft on peripheral T and B lymphocytes in adult nude mice. *Biol Trace Elem Res.* 2012;146:230-5. doi: 10.1007/s12011-011-9235-2. PubMed PMID: 22020772.