

Treatment of the Mirror Foot with Central Ray Resection: Report of 2 Cases

Gholam Hossain Shahcheraghi, MD,
FRCS(C);
Mahzad Javid, MD

Department of Orthopedic Surgery, Bone
and Joint Diseases Research Center,
Shiraz University of Medical Sciences,
Shiraz, Iran

Correspondence:

Mahzad Javid, MD;
Department of Orthopedic Surgery,
Chamran Hospital,
Chamran Blvd., Shiraz, Iran
Tel: +98 912 1439818
Fax: +98 21 88983610
Email: mahzadjavid@yahoo.com
Received: 17 June 2017
Revised: 8 August 2017
Accepted: 27 August 2017

Abstract

The mirror foot is a rare congenital foot anomaly which is often associated with 6- to 8-toed polydactyly. Postaxial polydactyly is the most common form of this anomaly, while central polydactyly is seen infrequently. We report on 2 cases of the central mirror-foot anomaly. Calcaneus duplication and fibular hypoplasia were present in 1 case. We treated both patients by resecting the middle foot rays and narrowing the foot width through cuneiform excision and use of cerclage wires or heavy suture approximation of the remaining adjacent rays. In the mirror foot, the old and more common treatment was the resection of the border extra toes or rays. Central-ray amputation with dorsal and plantar incisions and narrowing the foot with soft-tissue reduction and cuneiform excision confer excellent functional and cosmetic results.

Please cite this article as: Shahcheraghi GH, Javid M. Treatment of the Mirror Foot with Central Ray Resection: Report of 2 Cases. *Iran J Med Sci.* 2018;43(5):550-553.

Keywords • Polydactyly • Foot • Congenital abnormalities

What's Known

- Mirror image foot, with the full duplication of the foot rays, is a rare anomaly. The usual treatment is the amputation of the extra rays. This is often done via racket-type incisions of the border extra digits.

What's New

- In the central type of the mirror foot, the resection of the middle rays with double (plantar and dorsal) incisions will produce a functional and cosmetic foot and will enable regular shoe wear. Resection of part of the extra cuneiforms and calcaneus can confer a better shape with less width to the foot.

Introduction

Foot polydactyly is seen frequently in humans as an isolated anomaly. It could, rarely, be seen in association with such hand anomalies as the mirror hand, polysyndactyly, and ulnar dimelia.¹⁻⁴ Polydactyly is postaxial (the extra ray on the lateral side of the foot) almost 79% of the time and preaxial (15%) when the polydactyly is on the medial (tibial) side of the limb.^{5,6} Central duplication is quite rare, comprising 6% of the cases.⁶

The mirror -image foot, with the full duplication of the foot rays, is a rare anomaly. It is often reported along with other leg anomalies.⁷⁻⁹ The duplication of cuneiform tarsal bones is also seen. The duplication of hindfoot bones is very unlikely. Leg anomalies such as tibial hemimelia and fibular dimelia as part of syndromic cases have been reported.^{1,3,10}

The usual treatment is the amputation of the extra rays. This is often done via racket-type incisions of the border extra digits. The most normal-looking digits are usually preserved. We herein report 2 cases that were not the usual preaxial polydactyly reported in South Asians or postaxial polydactyly seen in African populations.^{11,12} Our patients had 8 digits of a central ray pattern type with fully developed metatarsal, proximal, middle, and distal phalanges in addition to some tarsal bone duplications. They were both treated, after walking age, with the resection of the central extra forefoot components via double incisions on the dorsal and plantar aspects of the foot while preserving the medial and lateral rays. The resection of the extra cuneiforms and also the partial resection of the duplicated calcaneus conferred excellent functional and cosmetic end results, avoiding a wide foot appearance.

The aim of this report was to describe a rare type of congenital foot polydactyly treated with a new surgical approach not previously explained in the literature.

Case Report

Case 1

A boy born from consanguineous parents presented at age 3.5 years with polydactyly of the left foot. The patient had a normal developmental history with no history of drug use or radiation exposure or any maternal problem during pregnancy. On physical examination, he had 8 digits on the left side, all moving well, with a plantigrade foot and a wider heel with a lateral prominence. X-ray revealed 8 metatarsals and 8 digits as well as double calcaneus. The lateral heel prominence was in fact the second calcaneus. The most medial toe looked bigger and was considered the big toe. Interestingly, the leg radiograph showed a hypoplastic fibula (figure 1). Surgery was done through simultaneous dorsal and plantar longitudinal incisions in the center of the foot with the removal of the extra skin and the resection of 3 central rays. The remaining adjacent metatarsals were approximated using a No. 1 cerclage wire, and the intermetatarsal ligaments were sutured with heavy VICRYL suture. A wedge of bone from the central cuneiform was also removed to narrow the midfoot. The lateral projection of the extra calcaneus was excised with a second incision, and its Achilles tendon was sutured to the Achilles tendon of the medial calcaneus. The cerclage wire was removed 1 year later.

Now, 3.5 years after surgery, the patient has a plantigrade foot and uses regular shoes. The foot is smaller than the normal foot. In addition, the ankle motion is somewhat limited in dorsiflexion, with extra plantarflexion motion. The heel pad is small and slightly pointed on the plantar aspect (figure 2).

Case 2

A 15-month-old boy presented with 8 rays. Similar to the first case, his history revealed parental consanguinity, no family history, and no history of drug or radiation exposure during gestation. Hindfoot tarsal duplication was not

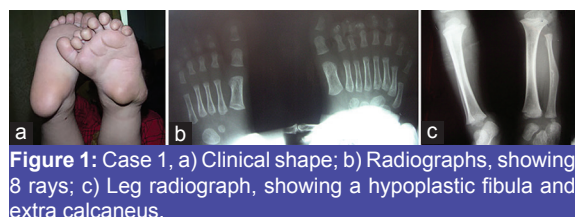

Figure 1: Case 1, a) Clinical shape; b) Radiographs, showing 8 rays; c) Leg radiograph, showing a hypoplastic fibula and extra calcaneus.

seen on X-ray. Later radiographs, however, showed extra cuneiforms. The leg radiograph failed to demonstrate any clear anomaly. The most medial toe looked more developed and larger than the other toes (figure 3). As was the case with the first patient, central ray resection was performed, with the general idea of preserving the most normal-looking and most functional rays. The approximation of the remaining metatarsals was done with heavy sutures, and the intermetatarsal ligaments were repaired. A pin was applied across the metatarsals and was then bent at the 2 ends so that the metatarsal approximation could be held. The pin was removed 6 weeks later. At age 4, almost 3 years after surgery, the patient has a plantigrade foot and normal ankle motion. He uses regular and same-sized shoes, and has no foot complaint (figure 4).

A written consent to report these cases was obtained from the parents.

Discussion

The polydactyly of the foot is seen frequently.^{6,13} Nonetheless, the mirror foot anomaly, also called “diplopodia”, which is often associated with 6 to 8 digits, is very rare.^{13,14} This kind of polydactyly has been often seen with such syndromes as Ellis–Van Creveld, Rubinstein–Taybi, Pallister–Hall, Laurence–Moon–Bardet–Biedl, Holt–Oram, and Down syndrome.^{6,15,16}

There have been different classification systems for foot polydactyly. The location of the duplication could be postaxial, preaxial, or central. The central type accounts for only 6% of foot polydactyl cases.⁶ The classification on the basis of the fifth and first metatarsal morphologies was used by Venn–Watson,¹⁷ who found 6 different variations in metatarsal shapes, while Watanabe et al.¹⁸ recognized 3 groups when

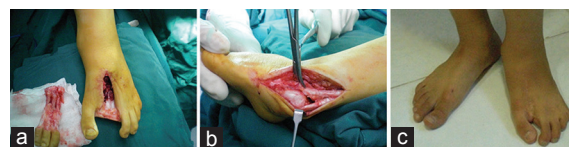

Figure 2: Case 1, Surgical figures (a and b) and final shape (c) are shown.

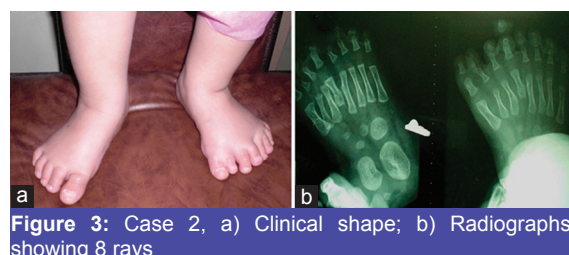


Figure 3: Case 2, a) Clinical shape; b) Radiographs, showing 8 rays

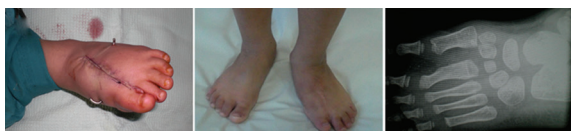

Figure 4: Case 2, Surgical figures and final shape. a) Central ray resection; b, c) Foot shape and radiograph (with extra cuneiform) 3 years after surgery

focusing on different tarsal bone variations. The mirror foot has been also classified similar to the mirror hand classification of Al-Qattan et al.¹⁹ by Fukazawa et al.²⁰

Verghese et al.,¹ investigating different foot anomaly patterns in the preaxial mirror foot in association with leg anomalies in 8 cases, reported lateral foot column duplication in fibular dimelia cases and duplication of the talus in tibial-deficient limbs.

Our cases, however, were more of the central type of the mirror foot polydactyly. Although all the digits had good active motion, the size and shape of the most tibial toe were more similar to those of a big toe. This was also true for the most fibular-side toe, which looked smaller and had a slight medial curve. The toes were all functional and moving well. The authors believe that when all the toes are similarly functional, the ray that is preserved should be the one which would best fit the location (i.e., the bigger toe for the medial and the smaller toe for the lateral side of the foot). Hence, it is reasonable not to rush into amputation until after age 2, when the size and function of the toe can be better evaluated. Indeed, this is a point that is difficult to be certain of in a small infant. The delay in treatment, however, may not be acceptable to overconcerned parents who would hide the child's foot from friends for cosmetic reasons. Simultaneous plantar and dorsal incisions would allow the removal of the extra skin, fat and muscle, giving a more cosmetic shape to the foot. This surgical approach has not been explained for this anomaly in the literature.^{12,13,16,21} Phelps et al.²² reviewed 194 cases of polydactyly and recommended a racket incision for a central extra toe.²² Additionally, the authors mentioned the complications of wider-looking feet, callosity on the remaining border toes, and residual angular deformity in reference to the common foot polydactyly. The central ray resection would obviate callosity formation.

The technique used by Osborn et al.²³ was a double-flap exposure with the incision line at the medial border, which could be a source of shoe irritation on the scar, in addition to the wide mobilization of the flap with the potential for skin necrosis.

The presence of calcaneal duplication, as was seen in our first case, is rare. This

deformity has also been reported by Verghese et al.¹ The condition gave the appearance of a very wide hindfoot to our patient, and that was why we decided to resect it. We removed the smaller section of the calcaneal duplication and transferred the Achilles tendon to the remaining part. The function is fine now, but the patient's heel is slightly narrower and pointed.

Extra numbers of cuneiforms may not be visible in a small child as the foot is not ossified. Putting the patient to sleep for magnetic resonance imaging to find the number of bones may not be acceptable to the parents. The removal of 1 extra cuneiform or the resection of part of the cuneiform could, however, be performed to obviate a very wide midfoot.

The hypoplastic fibula, as was seen in our first case, has not been reported before. Whether this is part of a longitudinal para-axial deficiency, a variation of fibular hemimelia, is not clear. A true limb length discrepancy cannot be established yet. The relation of this finding with mirror foot polydactyly is not clear to us either.

Conclusion

We conclude that for the rare central type of the mirror foot, the resection of the middle rays and the approximation of the remaining rays with double (plantar and dorsal) incisions will produce a functional and cosmetic foot and will enable regular shoe wear. The resection of part of the extra cuneiforms and calcaneus, if present, can confer a better shape with less width to the foot. Anomalies of leg bones may be present with the mirror foot and merit further investigation.

Conflict of Interest: None declared.

References

1. Verghese R, Shah H, Rebello G, Joseph B. Pre-axial mirror polydactyly associated with tibial deficiency: a study of the patterns of skeletal anomalies of the foot and leg. *J Child Orthop.* 2007;1:49-54. doi: 10.1007/s11832-006-0001-5. PubMed PMID: 19308506; PubMed Central PMCID: PMC2656696.
2. Hatchwell E, Dennis N. Mirror hands and feet: a further case of Laurin-Sandrow syndrome. *J Med Genet.* 1996;33:426-8. PubMed PMID: 8733058; PubMed Central PMCID: PMC2656696.
3. Laurin CA, Favreau JC, Labelle P. Bilateral Absence of the Radius and Tibia with Bilateral Reduplication of the Ulna and Fibula. A Case Report. *J Bone Joint Surg*

- Am. 1964;46:137-42. PubMed PMID: 14104303.
4. Sandrow RE, Sullivan PD, Steel HH. Hereditary ulnar and fibular dimelia with peculiar facies. A case report. *J Bone Joint Surg Am.* 1970;52:367-70. PubMed PMID: 4314818.
 5. Lee HS, Park SS, Yoon JO, Kim JS, Youm YS. Classification of postaxial polydactyly of the foot. *Foot Ankle Int.* 2006;27:356-62. doi: 10.1177/107110070602700507. PubMed PMID: 16701056.
 6. Belthur MV, Linton JL, Barnes DA. The spectrum of preaxial polydactyly of the foot. *J Pediatr Orthop.* 2011;31:435-47. doi: 10.1097/BPO.0b013e3182199a68. PubMed PMID: 21572282.
 7. Karchinov K. Congenital diplopodia with hypoplasia or aplasia of the tibia. A report of six cases. *J Bone Joint Surg Br.* 1973;55:604-11. PubMed PMID: 4729026.
 8. Igou RA, Jr., Kruger LM. Fibula dimelia in association with ipsilateral proximal focal femoral deficiency, tibial deficiency, and polydactyly. A case report. *Clin Orthop Relat Res.* 1990;237-41. PubMed PMID: 2394051.
 9. SkollPJ, SilfenR, HudsonDA, BlochCE. Mirror foot. *Plast Reconstr Surg.* 2000;105:2086-8. PubMed PMID: 10839407.
 10. Kumar A, Kruger LM. Fibular dimelia with deficiency of the tibia. *J Pediatr Orthop.* 1993;13:203-9. PubMed PMID: 8459012.
 11. Murphy KA. A prehistoric example of polydactyly from the Iron Age site of Simbusenga, Zambia. *Am J Phys Anthropol.* 1999;108:311-9. doi: 10.1002/(SICI)1096-8644(199903)108:3<311::AID-AJPA6>3.0.CO;2-D. PubMed PMID: 10096682.
 12. Galois L, Mainard D, Delagoutte JP. Polydactyly of the foot. Literature review and case presentations. *Acta Orthop Belg.* 2002;68:376-80. PubMed PMID: 12415940.
 13. El-Shazly M. An eight-toed foot: a rare pedal polydactyly. *J Foot Ankle Surg.* 2007;46:207-9. doi: 10.1053/j.jfas.2006.12.005. PubMed PMID: 17466250.
 14. Akn S. An unusual and nonclassified central polydactyly of the foot. *Ann Plast Surg.* 2004;53:86-8. PubMed PMID: 15211207.
 15. McCarthy GJ, Lindaman L, Stefan M. Pedal polydactyly: an overview with case report. *J Foot Ankle Surg.* 1995;34:577-82. doi: 10.1016/S1067-2516(09)80082-3. PubMed PMID: 8646211.
 16. Sudesh P, Kumar V, Jain M, Patel S. Mirror foot and our surgical experience: a case report and literature review. *Foot (Edinb).* 2010;20:44-5. doi: 10.1016/j.foot.2010.03.001. PubMed PMID: 20359881.
 17. Venn-Watson EA. Problems in polydactyly of the foot. *Orthop Clin North Am.* 1976;7:909-27. PubMed PMID: 185565.
 18. Watanabe H, Fujita S, Oka I. Polydactyly of the foot: an analysis of 265 cases and a morphological classification. *Plast Reconstr Surg.* 1992;89:856-77. PubMed PMID: 1561258.
 19. Al-Qattan MM, Al-Thunayan A, De Cordier M, Nandagopal N, Pitkanen J. Classification of the mirror hand-multiple hand spectrum. *J Hand Surg Br.* 1998;23:534-6. PubMed PMID: 9726562.
 20. Fukazawa H, Kawabata H, Matsui Y. Mirror foot: treatment of three cases and review of the literature. *J Child Orthop.* 2009;3:277-82. doi: 10.1007/s11832-009-0186-5. PubMed PMID: 19582495; PubMed Central PMCID: PMCPMC2726870.
 21. Beaty JH. Polydactyly. Polydactyly in operative paediatric orthopaedics. 2th ed. St Louis: Mosby-Year Book; 1995. p. 112-4.
 22. Phelps DA, Grogan DP. Polydactyly of the foot. *J Pediatr Orthop.* 1985;5:446-51. PubMed PMID: 4019759.
 23. Osborn EJ, Davids JR, Leffler LC, Gibson TW, Pugh LI. Central polydactyly of the foot: surgical management with plantar and dorsal advancement flaps. *J Pediatr Orthop.* 2014;34:346-51. doi: 10.1097/BPO.0000000000000094. PubMed PMID: 24045588.