

# Intralenticular Cilia Following Penetrating Ocular Trauma: A Case Report

Aidin Meshksar, MD; Ali Azimi, MD

Poostchi Ophthalmology Research Center, Shiraz University of Medical Sciences, Shiraz, Iran

## Correspondence:

Ali Azimi, MD;  
Poostchi Ophthalmology Research Center, Poostchi Street,  
P.O. Box: 7193634154, Shiraz, Iran  
**Tel/Fax:** +98 71 32302830,  
**Email:** ali.azimi1365@gmail.com  
Received: 5 May 2018  
Revised: 12 June 2018  
Accepted: 24 June 2018

## Abstract

Penetrating ocular trauma is one of the most important causes of vision loss, especially in men, and can be associated with intraocular foreign bodies. The incidence of intraocular cilia after trauma is very low. Here we report the case of a 24-year-old man who visited Poostchi Ophthalmology Clinic (Shiraz, Iran) due to a gradual vision loss in his left eye over the past 2 months. The probable cause was a foreign object (metal splinter) in the eye as a result of hammering metal on metal. An examination revealed the site of a 2-mm sealed corneal laceration, localized central cataract with intralenticular cilia, and moderate anterior reaction. The patient underwent foreign body removal, lensectomy, and posterior chamber intraocular lens implantation. One day after the operation, the visual acuity of the patient was 20/20. The intraocular cilia may have various clinical presentations; however, there is no report of a case with cilium embedded in the lens without any sight-threatening complications other than localized cataract and a moderate inflammatory reaction. Timely management and operation allow such patients to maintain a good vision.

Please cite this article as: Meshksar A, Azimi A. Intralenticular Cilia Following Penetrating Ocular Trauma: A Case Report. *Iran J Med Sci.* 2019;44(2):176-179. doi: 10.30476/IJMS.2019.44520.

**Keywords** • Eye foreign bodies • Corneal perforation • Anterior capsular rupture • Eye foreign bodies

## What's Known

- Intralenticular foreign body following trauma is rare and may have various clinical presentations. Hence, it requires an individualized approach for each patient.

## What's New

- A rare case of intralenticular cilia and localized central cataract caused by a metal splinter is reported. In similar reported cases, the cilium was either located in the anterior chamber or complicated by endophthalmitis.
- The patient gained 20/20 visual acuity after a successful phacoemulsification and posterior chamber intraocular lens implantation.

## Introduction

Penetrating ocular trauma is one of the most important causes of vision loss, especially in men, and can be associated with intraocular foreign bodies (IOFBs). However, intralenticular foreign bodies (ILFBs) are uncommon and constitute 5%-10% of all IOFBs. ILFBs can be categorized into metallic and non-metallic (e.g. cilia, glass stone, etc.) and almost always result in vision loss due to complete cataract.<sup>1</sup> There are few reports of asymptomatic ILFBs worldwide.<sup>2</sup> The incidence of intraocular cilia after trauma is very low but is described in few reports.<sup>3-5</sup> Intraocular cilia are usually located in the anterior chamber, embedded in the iris, floating in the anterior chamber, or partially lodged in the wound. Although cilium is considered relatively inert, it may have various clinical presentations ranging from being asymptomatic to severe inflammation or endophthalmitis; therefore, requiring different approaches.<sup>6</sup>

Herein we report a rare case of intraocular cilia, which was embedded in the lens at the bulb and protruded into the anterior chamber with localized central traumatic cataract and moderate anterior chamber reaction. The source of the penetrating ocular trauma was a foreign object (metal splinter) in the eye caused by

hammering metal on metal.

### Case Presentation

A 24-years-old man visited Poostchi Ophthalmology Clinic, affiliated to Shiraz University of Medical Sciences (Shiraz, Iran), in October 2017 due to a gradual vision loss in his left eye over the past 2 months. The patient did not wear safety glasses while hammering metal on metal.

On ophthalmic examination, the visual acuity of his left eye was 1-meter (counting fingers) and the relative afferent pupillary defect (RAPD) was negative. Intraocular pressure (IOP) value measured by the air-puff tonometer was 16 mmHg. There was no limitation of motion of the extraocular muscles.

On slit lamp examination, there was a paracentral lid margin notching of the left lower lid (possibly corresponding to the mentioned trauma), moderate blepharitis, and mild ciliary injection of conjunctiva. The pupil was round, regular, and reactive. The cornea was clear except for the site of a 2-mm vertical sealed laceration oriented in the center. The Seidel test was negative. The anterior chamber was formed and 2+ cells were detected in the anterior chamber. Localized central cortical cataract was observed around intralenticular cilia, which was embedded at its bulb and protruded into the anterior chamber (figure 1).

On dilated fundoscopic examination, no sign of vitritis was present. The red reflex was good, but the posterior segment could not be evaluated thoroughly. Consequently, ocular sonography was performed which showed that the retina was attached and no other foreign body was present in the eye. The ocular examination of the right eye was unremarkable.

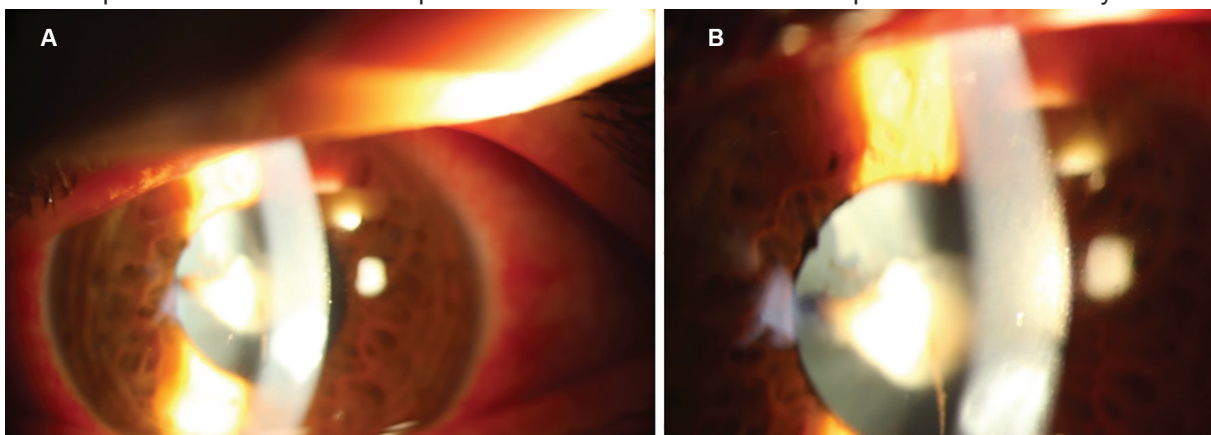
The patient was treated with prednisolone

acetate 1% and homatropine 2% topical eye drops (Sina Darou, Iran) every 6 hours and 8 hours, respectively, for 5 days till the anterior chamber reaction and the ciliary injection were resolved. The patient then underwent foreign body removal, lensectomy, and intraocular lens implantation. Under general anesthesia, after removing the cilia, we performed continuous curvilinear capsulorhexis and lensectomy with an irrigation/aspiration probe. A posterior chamber intraocular lens (PCIOL) was implanted in the capsular bag. On the first post-operative day, the uncorrected visual acuity was 20/20. The patient was subsequently treated with ciprofloxacin 0.3% and prednisolone acetate 1% eye-drops (Sina Darou, Iran) every 4 hours and 2 hours, respectively, for 1 week which was tapered over a month. His post-operative course over 6-month follow-up was uneventful.

A written informed consent was obtained from the patient for the publication of the present case report.

### Discussion

ILFBs almost always result in vision loss due to complete cataract. In the present case, however, the cataract was localized and limited possibly due to the small site of penetrance.<sup>1</sup> There are few reports on asymptomatic ILFBs worldwide and it is estimated that the encapsulation of IOFBs by a thin membrane may play a role in limiting the subsequent complications of traumatic lens capsule rupture. It is also possible that in small size anterior capsular defects (<2 mm), the subcapsular epithelium rapidly proliferates and prevents free fluid and ionic shift into the lens and thus the resulting cataract.<sup>2</sup> However, in capsular defects greater than 3 mm usually total cataract develops.<sup>3</sup> In the present case, the size of the anterior capsular tear caused by the cilia



**Figure 1:** The anterior chamber is formed and centrally localized cataract around the cilia is seen (A). With greater magnification, the cilium is seen embedded at its bulb in the lens with the surrounding localized cataract and protruding into the anterior chamber (B).

was 1 mm and thus could be easily epithelialized before complete cataract formation. The incidence of intraocular cilia after trauma is very low and is only described in a few reports. It is mainly caused by a metal wire, contrary to our case which was caused by a splinter as a result of hammering metal on metal.<sup>4, 5, 7</sup>

The incidence of cilia in the anterior chamber is very low (0.4%). The anterior chamber is the most frequent site where intraocular cilia is reported (45%). However, it is usually embedded in the iris and sometimes floats in the anterior chamber or partially embedded in the wound.<sup>8, 9</sup> In the literature, in nearly all similar cases, the cilium was floating in the anterior chamber. There was only one report of the cilia embedded in the lens which was complicated by a propionibacterium acnes lens abscess.<sup>10</sup>

Cilium is considered to be a relatively inert IOFB and shown to be tolerated for 50 years (one case report). However, the consequence of intraocular cilium is not predictable and can cause inflammation with varying degrees of severity. There are reports of inducing uveitis, iris cyst, cataract, intralenticular abscess, and endophthalmitis.<sup>6, 10</sup> However, in our patient, the intralenticular cilium resulted in 2+ anterior chamber reaction and simple cortical cataract which was managed efficiently with eye-drops pre-operatively.

Management of ILFBs is controversial and depends on the patients' age, type of foreign body, its location and impact on the visual acuity, and the accompanying ocular damage following trauma. Small ILFBs not involving the visual axis could be managed conservatively until the progression of cataract, ocular inflammation, and signs of siderosis bulbi in the metallic foreign bodies. There are reports of patients with ILFBs who maintained good vision for up to 40 and 60 years of follow-up. When the foreign body and the localized lens opacity compromise visual acuity, it is recommended to perform lensectomy or phacoemulsification, foreign body removal, and PCIOL implantation. However, this procedure impairs the near vision which can be disabling in young patients.<sup>2</sup> Since our patient had a 1 mm localized cortical cataract, it was decided to perform lensectomy, foreign body removal, and PCIOL due to vision loss. Despite perioperative ocular inflammation in such cases, as in our patient, good visual acuity can be obtained.

The main limitation of the present study was the unavailability of our patient for further follow-up beyond 6 months post-operation.

## Conclusion

Intraocular cilium may have various clinical

presentations requiring an individualized approach for each patient. In the present case, the cilium was embedded in the lens, protruded into the anterior chamber, and caused a localized central cortical cataract with moderate inflammatory reaction. Due to visual impairment, its removal was deemed necessary. Timely management and operation allow such patients to maintain a good vision.

**Conflict of Interest:** None declared.

## References

- 1 Arora R, Sanga L, Kumar M, Taneja M. Intralenticular foreign bodies: report of eight cases and review of management. *Indian J Ophthalmol.* 2000;48:119-22. PubMed PMID: 11116507.
- 2 Chang YS, Jeong YC, Ko BY. A case of an asymptomatic intralenticular foreign body. *Korean J Ophthalmol.* 2008;22:272-5. doi: 10.3341/kjo.2008.22.4.272. PubMed PMID: 19096248; PubMed Central PMCID: PMCPMC2629922.
- 3 Medina FM, Pierre Filho Pde T, Lupinacci AP, Costa DC, Torigoe AM. Intralenticular metal foreign body: case report. *Arq Bras Oftalmol.* 2006;69:749-51. doi: 10.1590/S0004-27492006000500025. PubMed PMID: 17187148.
- 4 Gopal L, Banker AS, Sharma T, Parikh S, Bhende PS, Chopra S. Intraocular cilia associated with perforating injury. *Indian J Ophthalmol.* 2000;48:33-6. PubMed PMID: 11271932.
- 5 Humayun M, de la Cruz Z, Maguire A, Dangel ME, Stark WJ, Green WR. Intraocular cilia. Report of six cases of 6 weeks' to 32 years' duration. *Arch Ophthalmol.* 1993;111:1396-401. doi: 10.1001/archophth.1993.01090100104036. PubMed PMID: 8216021.
- 6 Yalniz-Akkaya Z. Post-traumatic cilia remaining inert in the anterior chamber for 50 years: a case report. *J Med Case Rep.* 2011;5:527. doi: 10.1186/1752-1947-5-527. PubMed PMID: 22029734; PubMed Central PMCID: PMCPMC3213705.
- 7 Solomon A, Chowers I, Frucht-Pery J. Retained eyelashes in the anterior chamber following corneal perforation. *Eye (Lond).* 1998;12 ( Pt 6):1031-3. doi: 10.1038/eye.1998.270. PubMed PMID: 10326017.
- 8 Srivastava S. Cilia in anterior chamber. *Indian J Ophthalmol.* 1963;11:17.
- 9 Bhalla JS, Lal P. Eyelash In Anterior Chamber: An Unusual Intraocular Foreign Body.

- The Official Scientific Journal of Delhi Ophthalmological Society. 2017;28:37-9. doi: 10.7869/djo.290.
- 10 Fish LA, Ragen MT, Smith RE, Lean J. Propionibacterium acnes lens abscess after traumatic implantation of intralenticular cilia. Am J Ophthalmol. 1988;105:423-4. doi: 10.1016/0002-9394(88)90313-3. PubMed PMID: 3358438.