

Inguinal Bladder Hernia: Use of Virtual Computed Tomographic Cystography

Inguinal bladder hernia (IBH) was first described in 1951 as scrotal cystocele. It is an uncommon clinical entity that occurs in approximately 1-4% of inguinal hernias.¹ Despite numerous studies, IBH remains a challenge to surgeons and is usually diagnosed at the time of the herniorrhaphy. It has also been associated with the risk of unforeseen complications involving the bladder or ureter.² The condition does not pose a problem if the bladder is identified and not injured during the surgery. Otherwise, it may result in catastrophic complications due to bladder and ureteral injuries.² It is therefore important that general surgeons and urologists are aware of the possibility and perform preoperative evaluation and provide optimal treatment.

A 55-year-old man referred to our radiology department complaining of recurrent episodes of gross hematuria. He had no history of urinary stone, trauma, urinary symptoms, or previous episodes of urinary retention. He also mentioned the presence of a palpable mass in his left inguinal region for the past two months which did not cause any discomfort. Cross-sectional images indicated the need for preoperative computed tomography (CT) to diagnose the condition (figure 1a). In addition, we introduced a novel technique of CT reconstruction to produce virtual CT cystography images (figure 1b). In this technique, the bladder was exclusively selected by the segmentation technique using OSIRIX MD® (Pixmeo, Switzerland) software. The pixel value in the selected region of interest (ROI) was set to 200 HU and virtual CT cystography images were then reconstructed using the maximum intensity projection (MIP) reconstruction technique. This novel technique was invented by the authors to facilitate accurate surgical planning. Preoperative diagnosis of IBH is usually confirmed by imaging modalities such as ultrasound, cystography, and CT.³ The familiarity of radiologists with imaging features of IBH is essential for preoperative diagnosis and the prevention of catastrophic intraoperative complications.

To the best of our knowledge, this is the first application of virtual CT cystography as a reconstruction technique. Written informed consent for the publication of the images, with the protection of anonymity, was obtained from the patient.

Conflict of Interest: None declared.

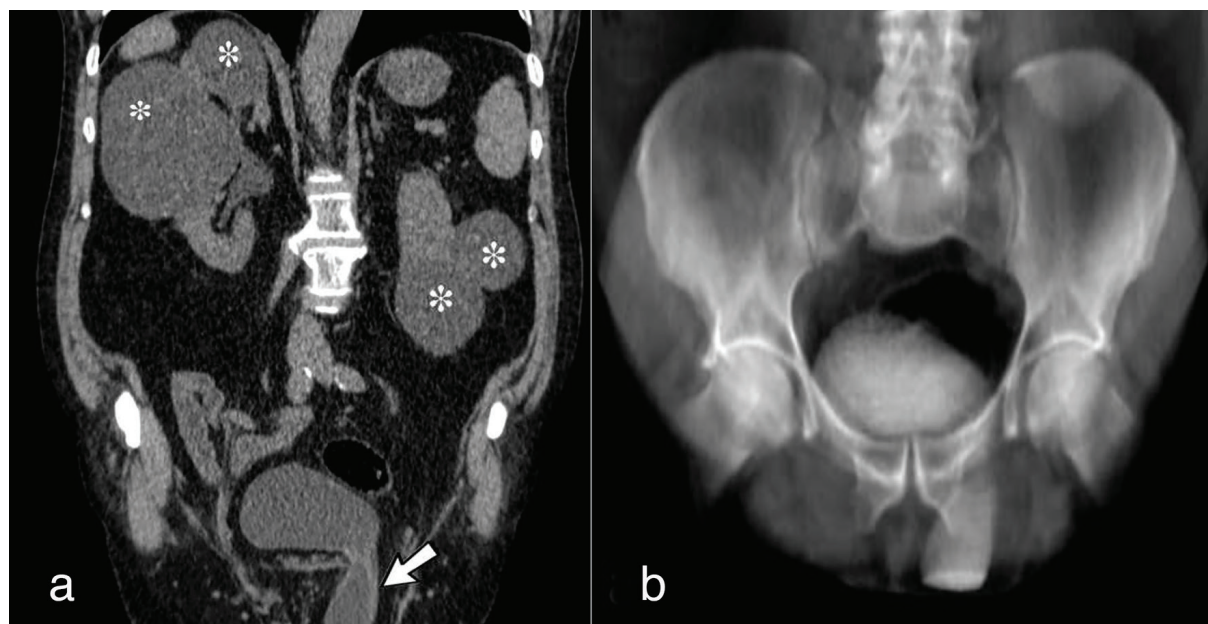


Figure 1: Coronal multiplanar reconstruction of abdominopelvic CT-scan (a) and virtual CT cystography (b) in a 55-year-old male patient with gross hematuria. Arrow: Inguinoscrotal herniation of bladder, Asterisks: Multiple simple cysts in each kidney

Please cite this article as: Farrokh D, Mortazavi R, Dehghani S, Seilanian-Toosi F, Abbasi B. Inguinal Bladder Hernia: Use of Virtual Computed Tomographic Cystography. *Iran J Med Sci.* 2019;44(5):430-431. doi: 10.30476/IJMS.2019.45393.

Donya Farrokh, MD;  Reihane Mortazavi, MD; Soroosh Dehghani, MD; Farrokh Seilanian-Toosi, MD; Bita Abbasi, MD 

Department of Radiology, Faculty of Medicine, Mashhad University of Medical Sciences, Mashhad, Iran

Correspondence:

Bitā Abbasi, MD;

Department of Radiology, Imam Reza Hospital, Razi Sq., Mashhad, Iran

Tel: +98 51 38525004

Email: abbasib@mums.ac.ir

Received: 16 October 2018

Revised: 12 January 2019

Accepted: 03 February 2019

References

- 1 Moufid K, Touiti D, Mohamed L. Inguinal bladder hernia: four case analyses. *Rev Urol.* 2013;15:32-6. PubMed PMID: 23671403; PubMed Central PMCID: PMC3651540.
- 2 Kraft KH, Sweeney S, Fink AS, Ritenour CW, Issa MM. Inguinoscrotal bladder hernias: report of a series and review of the literature. *Can Urol Assoc J.* 2008;2:619-23. doi: 10.5489/cuaj.980. PubMed PMID: 19066682; PubMed Central PMCID: PMC3651540.
- 3 Taskovska M, Janez J. Inguinal hernia containing urinary bladder-A case report. *Int J Surg Case Rep.* 2017;40:36-8. doi: 10.1016/j.ijscr.2017.08.046. PubMed PMID: 28923679; PubMed Central PMCID: PMC5601302.