

# A Double Cystic Duct With a Single Gallbladder Successfully Treated With Laparoscopic Cholecystectomy: A Challenge to Laparoscopic Surgeons

Hamed Anisi<sup>1</sup>, MD; Jalal Vahedian Ardakani<sup>1</sup>, MD; Mahmoodreza Khoonsari<sup>2</sup>, MD; Abdolhamid Chavoshi Khamneh<sup>3</sup>, MD

<sup>1</sup>Department of General Surgery, School of Medicine, Iran University of Medical Sciences, Tehran, Iran;

<sup>2</sup>Department of Internal Medicine, School of Medicine, Iran University of Medical Sciences, Tehran, Iran;

<sup>3</sup>Department of General Surgery, School of Medicine, Tehran University of Medical Sciences, Tehran, Iran

## Correspondence:

Abdolhamid Chavoshi Khamneh, MD; Imam Khomeini Hospital Complex, Tohid Square, Postal code: 14197-33141, Tehran, Iran

Tel: +98 21 82141000

Fax: +98 21 88602217

Email: chavoshikhamneh.ah@gmail.com

Received: 24 September 2019

Revised: 01 February 2020

Accepted: 07 March 2020

## What's Known

- A single gallbladder with a double cystic duct is a relatively rare congenital malformation. Up until late 2017, only 20 patients had been reported with duplicated cystic ducts. Misdiagnosis of this condition may lead to unwanted consequences such as bile duct injury and more complications.

## What's New

- In this report, we described a patient with a duplicated cystic duct, originating from the common bile duct and converging in the Hartmann pouch of the gallbladder, who underwent cholecystectomy. Endosonography was performed before the procedure but showed no malformation. A successful laparoscopic cholecystectomy was performed.

## Abstract

Although the cystic duct has diverse variations, a double cystic duct is rarely found. Only 20 cases had been reported until late 2017. In the present study, we describe a 58-year-old woman with a double cystic duct who initially presented with a passed stone and pancreatitis concomitant with a gallbladder containing microlithiasis. The double cystic duct was not detected in preoperative endoscopic ultrasonography; and the anomaly was an incidental finding during laparoscopic cholecystectomy. The patient had no postoperative complications and was discharged uneventfully. Postoperative magnetic resonance cholangiography showed a normal biliary tree structure.

Please cite this article as: Anisi H, Vahedian Ardakani J, Khoonsari MR, Chavoshi Khamneh A. A Double Cystic Duct With a Single Gallbladder Successfully Treated With Laparoscopic Cholecystectomy: A Challenge to Laparoscopic Surgeons. *Iran J Med Sci.* 2020;45(5):391-394. doi: 10.30476/ijms.2020.83304.1229.

**Keywords** • Bile ducts • Gallbladder • Cholangitis • Gallstones • Cystic duct

## Introduction

A single gallbladder with a double cystic duct is a relatively rare congenital malformation.<sup>1</sup> Up until late 2017, only 20 patients had been reported with duplicated cystic ducts in the English literature.<sup>2</sup> The preoperative diagnosis of a duplicated cystic duct is difficult, and the majority of the cases are found intraoperatively.<sup>3</sup> In 1956, Caster and Flannery<sup>4</sup> studied 101 cases with the congenital abnormalities of the gallbladder and categorized double cystic ducts into three types according to the site of the drainage. The extreme rarity of this variation poses a challenge to surgeons, and missing the case may lead to unwanted consequences such as bile duct injury and postoperative morbidities.<sup>5</sup> However, conducting a sensitive imaging test may help prevent damage in suspected patients.

In this report, we describe a patient with a duplicated cystic duct, originating from the Hartmann pouch of the gallbladder and converging in the common bile duct (CBD), who underwent cholecystectomy. Endosonography was performed before the procedure but failed to demonstrate any malformation. A successful laparoscopic cholecystectomy was performed.

## Case Presentation

A 58-year-old Caucasian overweight woman without any previously diagnosed diseases presented to the Department

of Surgery, Firoozgar Hospital, Tehran, Iran, in May 2019. She had abdominal pain that was predominantly localized in the epigastric area and the right upper quadrant approximately from 10 days before admission. The pain was constant and radiated to the back, suggesting pancreatitis. The patient mentioned episodes of fever and chills accompanied by nausea and vomiting. She noted the loss of appetite, food intolerance, and icteric sclera of a few days' duration. She had no history of previous interventions or surgeries. Written informed consent was obtained from the patient for reporting her data.

### Clinical Findings

Physical examination revealed generalized mild icterus. The patient had mild tenderness in the right upper quadrant and the epigastrium, and the Murphy sign was positive.

### Diagnostic Assessments

Laboratory studies showed leukocytosis (white blood cell count=13.9 ( $4-10 \times 10^3 \text{ mm}^3$ ), mildly elevated levels of liver enzymes (aspartate transaminase=58 U/l [female<31, male<33], alanine aminotransferase=63 U/l [female<31, male<33], and alkaline phosphatase=706 IU/L [up to 270]), a total bilirubin level of 6.9 mg/dL (0.2-1.2), a direct bilirubin level of 3.8 mg/dL (0.1-0.7), an amylase level of 164 U/l (<100), and a C-reactive protein level of 65 mg/L (up to 5). Primarily, cholangitis was highly suspected. Additionally, the CBD was mildly dilated (the largest diameter of the CBD=7.5 mm in the proximal part), and it contained no stones, sludge, or lesions. The pancreatic duct contour and diameter, as well as the pancreatic head, body, and ampulla, appeared normal. Further, the gallbladder contained sludge and microlithiasis. Passed stone, followed by transient pancreatitis, was suspected. The patient was recommended to undergo cholecystectomy.

### Therapeutic Intervention

The patient was taken into the operating room and prepared for laparoscopic cholecystectomy. Four portal accesses were inserted, and CO<sub>2</sub> was used for the insufflation of the abdominal cavity. Two cystic ducts were seen in the Calot triangle: one originating from the choledochal duct and the other from the common hepatic duct (figure 1). Both cystic ducts and the artery were dissected free and secured. A plastic hemolock clip was applied to the artery, and both cystic ducts were clipped using three hemolocks (figure 1-B). Before hemolock application on the second cystic duct, to perform a safe operation, we carefully dissected the gallbladder antegradely from the

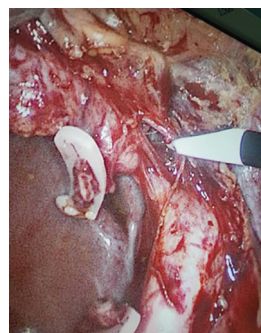


Figure 1: The suspected second cystic duct was found accidentally during the surgery.

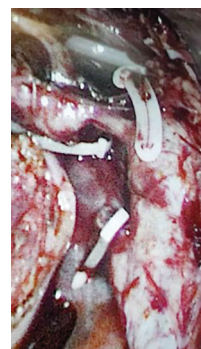


Figure 2: Safe confirmation of the second cystic duct was done after the antegrade dissection of the gallbladder from the liver.

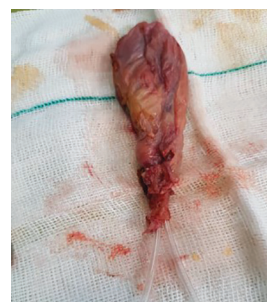
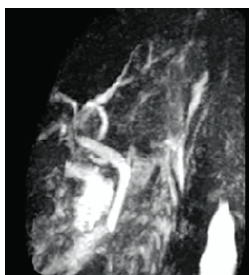
Figure 3: A Nelaton catheter was passed after the antegrade dissection of the gallbladder to confirm the second duct. The excised gallbladder showed two cystic ducts converging into the infundibulum.

fundus to the suspected second cystic duct (figure 2). However, the gall bladder was perforated during the procedure, and its contents spilled into the abdominal cavity. Washing with normal saline was performed multiple times to remove the gallbladder contents from the cavity completely. Ultimately, all portal defects were repaired.

A Nelaton catheter was passed slightly through both ducts, which converged into the infundibulum of the excised gallbladder (figure 3).

Postoperatively, the patient received an empirical antibiotic regimen for infection prophylaxis for three days. The laboratory tests, including liver enzymes and the bilirubin level, became normal and she was discharged on day three after the operation with a good diet tolerance.



**Figure 4:** Postoperative magnetic resonance cholangiopancreatography confirmed that the operation was performed safely with no bile duct damage.

#### Follow-up and Outcomes

Clinical follow-up was done two weeks postoperatively, and the patient was in good health condition. She had no complaints of pain, fever, or icterus. A postoperative magnetic resonance cholangiopancreatography (MRCP) was performed, and no abnormal findings except mild dilation at the central intrahepatic bile duct, and the CBD were reported (figure 4).

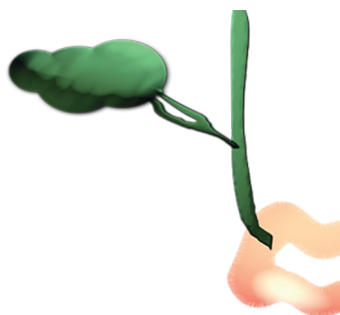
#### Discussion

Bile duct injury is a serious and common complication in patients undergoing laparoscopic cholecystectomy. The intraoperative detection of cystic duct anomalies and more specifically, a duplicated cystic duct insofar as it is an aberrant type, is a daunting challenge to surgeons. Postoperative bile leakage is a serious complication; it is reported in approximately 2% of patients.<sup>6</sup> Other possible complications include conversion into open surgery, bile fistulae, and liver cyst infection.<sup>3</sup>

The anatomical distinctions of cystic ducts and gallbladders were first reported by Edward Boyden in the early 1920s.<sup>7</sup> Later, Caster and Flannery classified cystic duct duplications into three subgroups: H type, wherein cystic ducts join the CBD at two different sites; Y type, wherein cystic ducts join each other and then drain into the CBD; and the trabecular type, wherein one cystic duct joins the CBD and the other enters the liver parenchyma.<sup>4</sup>

Duplicated cystic ducts are more common among females.<sup>1</sup> This could be because of the higher incidence of symptomatic cholelithiasis and cholecystectomy in the female gender. It has been reported that in 80% of patients, a double gallbladder is also present.<sup>5</sup> The age at the diagnosis of a double cystic duct varies between newborns and about 75 years.<sup>1</sup> In a newborn, a double gallbladder is accompanied by vertebral defects, anal atresia, cardiac defects, tracheoesophageal fistulae, renal anomalies, and limb abnormalities (VACTERL).<sup>8</sup>

In the current case, the patient had a single



**Figure 5:** A schematic view of the current case is illustrated.

gallbladder with two cystic ducts that had two separate origins and drained separately into the CBD, presenting like a Y type variation (figure 5).

Ultrasonography usually fails to delineate the anatomical variations of the cystic duct.<sup>1,9</sup> In our case, neither abdominal sonography nor EUS raised suspicions of an abnormality.

Munie and others summarized case reports of 20 patients with duplicated cystic ducts from 1961 to 2019 in the English literature.<sup>2</sup> They reported that 75% of the patients were female and the H type variation was the most common type. Among the patients who underwent preoperative imaging assessments, comprised of EUS, endoscopic retrograde cholangiopancreatography, and intraoperative cholangiography (IOC), malformations were diagnosed only in three out of seven patients, preoperatively. In the current study, EUS results were not suggestive of cystic duct abnormalities. Unfortunately, we did not perform IOC.

Buddingh and others utilized IOC and the method of the critical view of safety photographs to assess the biliary anatomy.<sup>10</sup> They demonstrated that IOC images had superior results in the documentation of the biliary anatomy during the surgery by comparison with the critical view of safety (conclusive in 57% vs 27%;  $P < 0.001$ ). Both methods had limitations in visualizing the biliary anatomy and were not satisfactory.

Sarawagi and others studied the imaging features of cystic duct variations in 198 patients using MRCP and reported that about half of their patients had normal lateral insertions of the cystic duct in the middle third of the CBD.<sup>9</sup> Additionally, medial, low, and high insertions were less common. The authors reported no case with double cystic ducts and concluded that MRCP was an ideal imaging technique for determining the cystic duct anatomy.

On the whole, despite all the limitations of imaging modalities, it is generally accepted that performing preoperative and intraoperative imaging studies is mandatory in suspected patients and may determine the abnormality. Notwithstanding the normal results of imaging

reports, the surgeon should be aware of possible missed anatomical variations during the procedure. Because of the lack of MRCP facilities in our center, we could not perform it before surgery. Post-discharge MRCP revealed normal results.

The failure to perform preoperative MRCP and IOC was the main limitation of our study. MRCP is reported as an optimal imaging modality for cystic duct malformations. However, as preoperative EUS and endoscopic retrograde cholangiopancreatography failed to reveal any anomaly, we neither performed MRCP nor made cholangiography devices ready. Therefore, to confirm our observations, we passed a Nelaton through the ducts.

#### Take-away Lessons

Duplicated cystic ducts are extremely rare variations. It appears that imaging techniques are not sensitive and specific enough to detect the abnormality pre/intraoperatively. Preoperative MRCP and IOC may help to determine cystic duct variations. Nonetheless, it is important to keep a watchful eye on the anatomy during the surgery, even with normal imaging findings.

#### Conclusion

This study highlights the point that despite all recent advances in imaging techniques, there are still limitations in visualizing anatomic variations in the cystic duct. It is, therefore, essential to be deeply observant of the anatomy during the surgery even if preoperative imaging tests reveal normal findings.

#### Acknowledgement

We thank the Operating Rooms' staff of Firoozgar Hospital for their cooperation.

**Conflict of Interest:** None declared.

#### References

- 1 Salih AM, Kakamad FH, Mohammed SH, Salih RQ, Habibullah IJ, Muhialdeen AS, et al. Double cystic duct, a review of literature with report of a new case. *Int J Surg Case Rep.* 2017;38:146-8. doi: 10.1016/j.ijscr.2017.07.027. PubMed PMID: 28759827; PubMed Central PMCID: PMC5537449.
- 2 Munie S, Nasser H, Go PH, Rosso K, Woodward A. Case report of a duplicated cystic duct: A unique challenge for the laparoscopic surgeon. *Int J Surg Case Rep.* 2019;56:78-81. doi: 10.1016/j.ijscr.2019.02.030. PubMed PMID: 30851627; PubMed Central PMCID: PMC6407078.
- 3 Fujii A, Hiraki M, Egawa N, Kono H, Ide T, Nojiri J, et al. Double cystic duct preoperatively diagnosed and successfully treated with laparoscopic cholecystectomy: A case report. *Int J Surg Case Rep.* 2017;37:102-5. doi: 10.1016/j.ijscr.2017.06.013. PubMed PMID: 28651227; PubMed Central PMCID: PMC5485761.
- 4 Caster MP, Flannery MG. Congenital abnormalities of the gallbladder; 101 cases. *Surg Gynecol Obstet.* 1956;103:439-57. PubMed PMID: 13371485.
- 5 Otaibi W, Quach G, Burke B. Double Cystic Duct in a Septated Gallbladder. *J Investig Med High Impact Case Rep.* 2015;3:2324709615579105. doi: 10.1177/2324709615579105. PubMed PMID: 26425640; PubMed Central PMCID: PMC4528872.
- 6 Ljubicic N, Biscanin A, Pavic T, Nikolic M, Budimir I, Mijic A, et al. Biliary leakage after urgent cholecystectomy: Optimization of endoscopic treatment. *World J Gastrointest Endosc.* 2015;7:547-54. doi: 10.4253/wjge.v7.i5.547. PubMed PMID: 25992194; PubMed Central PMCID: PMC4436923.
- 7 Boyden EA. The accessory gall-bladder—an embryological and comparative study of aberrant biliary vesicles occurring in man and the domestic mammals. *American Journal of Anatomy.* 1926;38:177-231. doi: 10.1002/aja.1000380202.
- 8 Lugo-Vicente H, Correa M, Brunet H. Double cystic duct in a child with VACTERL association: a case report. *Bol Asoc Med P R.* 2009;101:56-8. PubMed PMID: 19954104.
- 9 Sarawagi R, Sundar S, Gupta SK, Raghuvanshi S. Anatomical Variations of Cystic Ducts in Magnetic Resonance Cholangiopancreatography and Clinical Implications. *Radiol Res Pract.* 2016;2016:3021484. doi: 10.1155/2016/3021484. PubMed PMID: 27313891; PubMed Central PMCID: PMC4897729.
- 10 Buddingh KT, Morks AN, ten Cate Hoedemaker HO, Blaauw CB, van Dam GM, Ploeg RJ, et al. Documenting correct assessment of biliary anatomy during laparoscopic cholecystectomy. *Surg Endosc.* 2012;26:79-85. doi: 10.1007/s00464-011-1831-x. PubMed PMID: 21792718; PubMed Central PMCID: PMC3242940.