

Cervicofacial Necrotizing Fasciitis in Patients with No Underlying Medical Conditions: A Review of Four Cases Seen in Twelve Months at a Nigerian Tertiary Hospital

Adesina Oluwafemi Adewale¹, BDS, FMCDS;
Opaleye Taofiq Olamide², BDS;
Salmal Ajibola Yussuf², BDS;
Idowu Omobolaji Stephen², BDS

¹Department of Consultant and Head, Department of Oral and Maxillofacial Surgery, Faculty of Dentistry, Lagos State University College of Medicine, Lagos State, Nigeria;

²Department of Oral and Maxillofacial Surgery, Faculty of Dentistry, Lagos State University College of Medicine, Lagos State, Nigeria

Correspondence:

Adesina Oluwafemi Adewale, BDS, FMCDS; Department of Oral and Maxillofacial Surgery, Faculty of Dentistry, Lagos State University College of Medicine, Ikeja, Postal code: 100282, Lagos State, Nigeria
Tel: +23 480 35842203
Email: femmyadesina2000@yahoo.com
Received: 1 August 2017
Revised: 18 December 2017
Accepted: 3 January 2018

What's Known

- Necrotizing fasciitis of the facial region is a rare occurrence, especially in an immunocompetent patient. Factors predisposing to necrotizing fasciitis are diabetes, hypertension, obesity, malnutrition, peripheral vascular disease, severe liver disease, alcoholism, and acquired immunodeficiency syndrome.
- Clinical features of necrotizing fasciitis in the early stages are not specific, so it may not be correctly diagnosed.

What's New

- All the four cases presented had no known underlying medical condition
- Patients with oral and maxillofacial infections who have extraordinary clinical symptoms such as extensive swelling, redness, fever, crepitation, or a marked increase in serum C-reactive protein should be strongly suspected of having necrotizing fasciitis.
- Cervicofacial necrotizing fasciitis in these cases had odontogenic origins.

Abstract

Necrotizing fasciitis of the head and neck is a rare but rapidly progressive infection involving the skin, subcutaneous tissue, and fascia. We report 4 cases of cervicofacial necrotizing fasciitis with similar patterns of presentation. All the 4 cases presented with an odontogenic source and no underlying medical condition. All the patients had tooth extraction and serial wound debridement. Three of these patients recovered well, and healing of the wound occurred by secondary intention. One patient had a resultant neck defect, which was repaired with a supraclavicular island flap after the infection had subsided. We advocate the importance of early detection of necrotizing fasciitis with or without an underlying medical condition and an aggressive medical and surgical intervention. Additionally, eradication of the source of infection is highly indicated to reduce the mortality of this disease.

Please cite this article as: Adewale AO, Olamide OT, Yussuf SA, Stephen IO. Cervicofacial Necrotizing Fasciitis in Patients with No Underlying Medical Conditions: A Review of Four Cases Seen in Twelve Months at a Nigerian Tertiary Hospital. *Iran J Med Sci*. 2018;43(6):653-658.

Keywords • Neck • Fasciitis, • necrotizing • Infection • Tooth

Introduction

Necrotizing fasciitis is a soft-tissue infection which is, albeit rare, rapidly progressive and potentially fatal. It is usually caused by toxin-producing virulent bacteria and is characterized by widespread fascia necrosis with relative sparing of the skin and the underlying muscle.^{1,2} Necrotizing fasciitis primarily involves the superficial fascia, subcutaneous fat (which contains vascular structures and nerves), and deep fascia.¹ It is often associated with severe systemic toxicity and requires prompt recognition and aggressive treatment.³ Multiple terms have been used to describe necrotizing fasciitis including hemolytic streptococcal gangrene, progressive synergistic bacterial gangrene, necrotizing erysipelas, suppurative fasciitis, acute dermal gangrene, and Fournier's gangrene.⁴

The disease is now known to be an infection of polymicrobial or mixed aerobic-anaerobic infection.⁵ Patients with immunocompromised status such as those with diabetes mellitus, cancer, alcoholism, vascular insufficiencies, organ transplants, human immunodeficiency virus, and malnutrition are prone to this type of infection.⁶ Organisms spread from the subcutaneous tissue along the superficial and deep fascia planes,

presumably facilitated by bacterial enzymes and toxins.⁷ This deep infection causes vascular compression, ischemia, and tissue necrosis. The superficial nerves are damaged, producing the characteristic localized anesthesia.⁸ Septicemia ensues with systemic toxicity.

Necrotizing fasciitis is commonly seen in the extremities, trunk, and perineum.⁷ In the head and neck region, necrotizing fasciitis is rare (5.3%)⁹ but when it does occur, dental infection is a frequent cause.¹⁰ The source of facial cervicofacial necrotizing fasciitis (CNF) infection is either dental, sinusoidal, peritonsillar, or salivary gland infections. Infections secondary to surgery or trauma have also been reported.¹⁰ Group A beta-hemolytic streptococci and staphylococci have been classically described as the causative agents, and obligate anaerobic bacteria have also been implicated.¹¹

We report 4 cases of CNF from odontogenic infection seen in patients with no specific underlying systemic condition.

Case 1

A 60-year-old female trader presented with right submandibular and upper cervical swelling with an associated ulcer of about 1 week's duration. She had been seen previously by a dentist, who prescribed amoxicillin and metronidazole; however, because of her failure to comply with treatment, her symptoms continued to worsen. There was no significant finding in her past medical history. Physical examination revealed a conscious and alert woman with a pulse rate of 81 beats/min and blood pressure of 100/70 mm Hg. In addition, she was acyanosed, anicteric, febrile (37.8°C), not in respiratory distress (20 cycles/min), and not dehydrated. Extraoral examination demonstrated a diffuse fluctuant swelling with pus discharge, and the overlying skin appeared hyperemic. There was also an area with necrotic ulcer, which measured about 6 cm×4 cm in its widest diameter (figure 1a). Intraorally, there was mild trismus and grade II mobility of the right second mandibular molar. A diagnosis of CNF involving the right submandibular and upper cervical region was made.

Orthopantomogram (OPG) showed that the right mandibular second molar had severe alveolar bone loss. The patient's blood sugar was within the normal limit. *Klebsiella pneumoniae* and *Proteus mirabilis* species were isolated from the wound. The retroviral screening was negative.

The patient was admitted after wound debridement with hydrogen peroxide (1:4), and extraction of the right mandibular second molar

was done. Intravenous antibiotics including ceftriaxone (Roche, Switzerland), metronidazole (Trimetro, Nigeria), and gentamicin (Medwise Overseas Pvt. Ltd., India) were started. She was also placed on folic acid tablets (Emzor, Nigeria), vitamin B complex (Emzor, Nigeria), and vitamin C (Emzor Nigeria), all in divided doses for a period of 2 weeks.

Thorough serial debridement was done using hydrogen peroxide and EUSOL dressing (twice daily at alternate days for 4 days) until a healthy tissue was seen around the wound. The residual defect was left to heal with secondary intention (figure 1b). The patient was discharged to the outpatient clinic without complications 8 days after admission and had a couple of review visits before final discharge.

Case 2

A 28-year-old male footballer presented with bilateral submandibular swelling with extension into the anterior neck of about 5 days' duration. There was a 2-week history of toothache, which he claimed had subsided following a self-administered medication. There was no significant finding in his past medical history.

Clinical examination revealed a conscious and alert man in mild respiratory distress (27 cycles/min) with a pulse rate of 86 beats/min and blood pressure of 110/70 mm Hg. He was acyanosed, anicteric, afebrile (36.8 °C), and not dehydrated. Extraoral examination showed bilateral submandibular swelling with associated anterior neck swelling, which was diffuse, firm to touch, and tender. Additionally, the overlying skin appeared hyperemic. Intraoral examination demonstrated a mild trismus (about

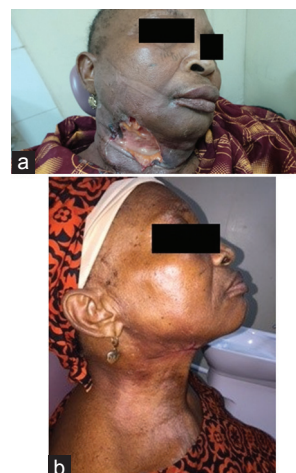

Figure 1: a) Necrotizing fasciitis, involving the right submandibular and cervical regions secondary to an odontogenic infection. b) Healing by secondary intention after serial debridement.

20 mm of interincisal distance), halitosis, poor oral hygiene, raised floor of the mouth, and pus discharge around an impacted right mandibular third molar.

OPG showed that the right mandibular third molar had mesioangular impaction with a carious cavity in the impacted tooth. Hematological parameters, including blood glucose, were within the normal range. *Citrobacter freundii* was isolated from the wound. The retroviral screening was negative.

Incision and drainage was done immediately. Intravenous antibiotics including ceftriaxone (Roche, Switzerland), metronidazole (Trimetro, Nigeria), and gentamicin (Medwise Overseas Pvt. Ltd., India) were instituted. Extraction of the impacted tooth was done after 72 hours (after achieving an improved mouth opening).

Two days after admission, there was pus discharge and sloughing off of the skin of the anterior neck swelling and the patient was then diagnosed with CNF. Immediately, thorough serial debridement was commenced using hydrogen peroxide (1:4) and EUSOL dressing (twice daily at alternate days for 3 days). The resultant neck defect was repaired with a supraclavicular island flap under general anesthesia after infection had subsided. The flap healed, and the clinical condition of the patient improved satisfactorily. He was discharged 1 month after admission.

Case 3

A 50-year-old male trader presented with left submandibular swelling of 3 days' duration and toothache of 10 days' duration. He claimed that the toothache was initially severe in characteristics but became dull after he took some medications. He did not know the names of the medications, however. There was no significant contributory finding in the patient's medical history.

Clinical examination revealed a conscious and alert man in mild respiratory distress (26 cycles/min) with a pulse rate of 105 beats/min and blood pressure of 147/90 mm Hg. He was acyanosed, anicteric, febrile (37 °C), and not dehydrated. There was right submandibular swelling with associated right submandibular and neck swelling of varying consistency (from firm to fluctuant). The swelling was also tender, and the overlying skin appeared hyperemic. Intraorally, there was trismus (about 22 mm of interincisal distance), halitosis, poor oral hygiene, and grade III mobility of the left mandibular second molar.

OPG revealed alveolar bone loss around the right mandibular second molar (figure 2a).

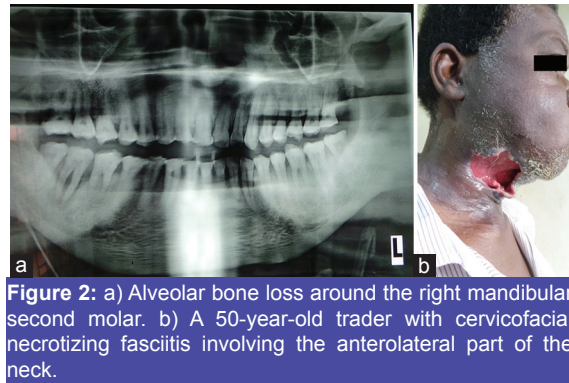


Figure 2: a) Alveolar bone loss around the right mandibular second molar. b) A 50-year-old trader with cervicofacial necrotizing fasciitis involving the anterolateral part of the neck.

Hematological parameters, including blood glucose, were within the normal range. *Proteus mirabilis* and *Klebsiella pneumoniae* were isolated from the wound. The retroviral screening was negative.

The patient was admitted following incision and drainage with extraction of the left mandibular second molar on the first day of presentation. Intravenous antibiotics including ceftriaxone, metronidazole, and gentamicin (Medwise Overseas Pvt. Ltd., India) were instituted.

A day after admission, there was pus discharge and sloughing off of the skin of the anterolateral neck swelling (figure 2b). A diagnosis of CNF was then made. Immediately, thorough serial debridement was commenced using hydrogen peroxide (1:4) and EUSOL dressing. The resultant anterolateral neck defect was left to heal with secondary intention. The patient was discharged to the outpatient clinic without complications 10 days after admission.

Case 4

A 34-year-old male electrician presented with right submandibular swelling, necrotic ulcer of about 1 week's duration, and toothache of 2 weeks' duration. The pain was initially severe, but it was relieved with some self-medication. There was no significant finding in his past medical history.

Clinical examination revealed a conscious and alert man with a pulse rate of 79 beats/min and blood pressure of 110/70 mm Hg. He was acyanosed, anicteric, afebrile (36.6 °C), not in respiratory distress (18 cycles/min), and not dehydrated. There was right submandibular swelling, which was diffuse, fluctuant with pus discharge, and tender. The overlying skin appeared hyperemic. There was also an associated necrotic ulcer, which measured about 7 cm×5 cm in its widest diameter. Intraorally, there was moderate trismus (about 25 mm of interincisal distance), halitosis, poor oral hygiene,

and pus discharge around the right mandibular third molar, which was grossly carious.

OPG revealed a carious cavity on the right mandibular third molar. Hematological parameters, including blood glucose, were within the normal range. *Staphylococcus haemolyticus* and *streptococcus pneumoniae* (both sensitive to ceftriaxone) as well as *Klebsiella pneumoniae* were isolated from the wound. The retroviral screening was negative. The patient had debridement with extraction of the right mandibular third molar. The treatment also included intravenous ceftriaxone (Roche, Switzerland), metronidazole (Trimetro, Nigeria), and gentamicin (Medwise Overseas Pvt. Ltd., India). Thorough serial debridement was done twice daily for 4 days using hydrogen peroxide (1:4) and EUSOL dressing. The right submandibular defect (about 7 cm×5 cm) was meant to be repaired using a split skin graft; nonetheless, due to the patient's financial constraint, the defect was left to heal with secondary intention. This was followed by wound contracture, which was then relieved under local anesthesia. The patient was discharged without any further complications.

All of the patients signed written informed consent forms.

Discussion

The term "necrotizing fasciitis" was coined by Wilson in 1952 to emphasize the features of fascia necrosis, observed when there is spread of infection along the fascia planes, and the nonspecific nature of the causative microbes.¹²

The head and neck region, unlike the other anatomic sites, are rarely affected due to their rich vascular supply.¹³ Ndukwe et al.¹⁴ and Obimakinde et al.¹⁵ from Southwest Nigeria reported 16 and 12 cases of CNF, respectively, over a period of 10 and 5 years. In the present study, only 4 cases were seen in the year under review.

Advanced age, chronic alcohol abuse, diabetes mellitus, human immunodeficiency virus infection, intravenous drug abuse, malnutrition, obesity, organ failure, peripheral vascular disease, severe liver disease, and underlying malignancy render individuals prone to this type of infection.^{13,16} Diabetes mellitus is, however, the most frequent associated disorder.¹⁷ These risk factors define the induction, progression, and results of the disease insofar as several of them produce leukocyte dysfunction, reduced chemotaxis, phagocytosis, and opsonization.¹³

None of the cases presented in the current study had any underlying medical condition.

Hernandez et al.¹³ in a systematic review also found cases caused by a yeast-like fungal infection in immunocompetent patients, which rules out the previous notion that this kind of infection affects immunocompromised individuals.

The diagnosis of CNF is not easy due to its rarity.¹⁸ The symptoms of CNF may be nonspecific at onset and depend on its site and the stage of the disease. CNF may sometimes present as a common abscess at the early stage. Clinicians should, therefore, have a high index of suspicion with any patient presenting with a fast-spreading swelling which is erythematous with associated fever. Palpation of the wound to check for crepitus, which might indicate subcutaneous gas production, is also necessary. Nonetheless, deep-seated gas may not be clinically palpable.¹⁸ Case II and Case III in the current study were initially wrongly diagnosed to be Ludwig angina until tissue necrosis was observed.

X-ray, computed tomography (CT) scanning, and magnetic resonance imaging are useful in diagnosing CNF if there is subcutaneous gas. The gold standard for diagnosis is intravenous contrast CT scan, which can distinguish between abscesses, erysipelas, and cellulitis.¹⁹ However, radiological tests should never delay surgery if there is crepitus on examination or evidence of advancing soft tissue infection.¹⁷ None of the patients in the present study could afford CT scanning. Consequently, they only had OPG, which merely showed dental pathologies.

Laboratory values can also aid in the diagnosis of CNF. They are useful because values can be assigned to the laboratory risk indicator for necrotizing fasciitis score in order to assess the likelihood of having CNF. (They include serum C-reactive protein >150 mg/L [4 points], white blood count >25 × 10³/μL [2 points] and between 15 and 25 × 10³/μL [1 point], hemoglobin <11 g/dL [2 points] and between 11 and 13.5 g/dL [1 point], serum creatinine >1.6 mg/dL [2 points], and serum glucose >180 g/dL [1 point].) A score below 5 indicates a probability of less than 50% of the presence of CNF, meanwhile a score above 6 should raise the suspicion of the presence of CNF at 75% to 80%.¹³

Antibiotic therapy with broad-spectrum antibiotics, repeated surgical debridement, and intensive care support should be promptly instituted.¹⁸ All the 4 patients in the current study had broad-spectrum antimicrobial therapy and repeated episodes of surgical debridement. Treatment must be initiated before obtaining the results.²⁰ Surgical debridement is aimed at eradicating all necrotic tissues until fresh viable tissue is observed. Evidence has shown that

when treatment is based on just antimicrobial therapy and support, mortality approaches 100%.²¹

Prompt surgical intervention with the removal of the source of infection is necessary to achieve good prognosis as demonstrated in all the 4 cases presented herein. The most commonly implicated factor reported for CNF in the head and neck region is odontogenic infection or post-extraction infection.^{22,23} Infection from the second or third molar is common for cervicofacial infection. This is because the roots of these molars extend below the insertion of the mylohyoid muscle, which is connected to the submandibular space.²⁴

Immediate reconstruction of the resultant defect is not recommended after recovery from the infection. Primary closure can be performed with various local flaps, skin graft, regional flaps, and even free vascularized flaps.²⁵ In the 4 presented cases, 3 defects were closed primarily, while 1 had a skin flap.

No mortality was recorded in any of the cases presented in the current study. Death is most often secondary to sepsis, multiorgan failure, or respiratory failure.^{23,26} Overall mortality ranges between 10% and 40% and can be as high as 80% with delayed medical or surgical intervention.¹⁷

Conclusion

CNF is a rapidly spreading and potentially fatal disease. Dental infection constitutes a common cause of this disease. Therefore, clinicians should have a high index of suspicion when patients present with a fast-spreading swelling which is erythematous and associated fever. Prompt and aggressive medical and surgical treatment will help to reduce mortality secondary to CNF.

Acknowledgement

Photographs of the patients are published with their permission.

Conflict of Interest: None declared.

References

- Green RJ, Dafoe DC, Raffin TA. Necrotizing fasciitis. *Chest*. 1996;110:219-29. doi: 10.1378/chest.110.1.219. PubMed PMID: 8681631.
- Majeski JA, Alexander JW. Early diagnosis, nutritional support, and immediate extensive debridement improve survival in necrotizing

- fasciitis. *Am J Surg*. 1983;145:784-7. PubMed PMID: 6344676.
- Donaldson PM, Naylor B, Lowe JW, Gouldsbrough DR. Rapidly fatal necrotising fasciitis caused by *Streptococcus pyogenes*. *J Clin Pathol*. 1993;46:617-20. PubMed PMID: 8157746; PubMed Central PMCID: PMC501388.
- Voros D, Pissiotis C, Georgantas D, Katsaragakis S, Antoniou S, Papadimitriou J. Role of early and extensive surgery in the treatment of severe necrotizing soft tissue infection. *Br J Surg*. 1993;80:1190-1. doi: 10.1002/bjs.1800800943. PubMed PMID: 8402129.
- Obiechina AE, Arotiba JT, Fasola AO. Necrotizing fasciitis of odontogenic origin in Ibadan, Nigeria. *Br J Oral Maxillofac Surg*. 2001;39:122-6. doi: 10.1054/bjom.2000.0585. PubMed PMID: 11286446.
- Whitesides L, Cotto-Cumba C, Myers RA. Cervical necrotizing fasciitis of odontogenic origin: a case report and review of 12 cases. *J Oral Maxillofac Surg*. 2000;58:144-51. PubMed PMID: 10670592.
- Vivek G, Singh R, Veena G, Arya P. Necrotizing fasciitis of face in odontogenic infection: A rare clinical entity. *World J Dent*. 2012;3:261-4.
- Fliss DM, Tovi F, Zirkun HJ. Necrotizing soft-tissue infections of dental origin. *J Oral Maxillofac Surg*. 1990;48:1104-8. PubMed PMID: 2213300.
- Carter LM, Layton S. Cervicofacial infection of dental origin presenting to maxillofacial surgery units in the United Kingdom: a national audit. *Br Dent J*. 2009;206:73-8. doi: 10.1038/sj.bdj.2009.4. PubMed PMID: 19165262.
- Eltayeb AS, Ahmad AG, Elbeshir EI. A case of labio-facial necrotizing fasciitis complicating acne. *BMC Res Notes*. 2016;9:232. doi: 10.1186/s13104-016-2041-3. PubMed PMID: 27107717; PubMed Central PMCID: PMC4841958.
- Banerjee AR, Murty GE, Moir AA. Cervical necrotizing fasciitis: a distinct clinicopathological entity? *J Laryngol Otol*. 1996;110:81-6. PubMed PMID: 8745791.
- Wilson B. Necrotizing fasciitis. *Am Surg*. 1952;18:416-31. PubMed PMID: 14915014.
- Hernández DAA, Manuel A, Chávez G, Rivera AS. Facial Necrotizing Fasciitis in Adults: A Systematic Review. *Heighpubs Otolaryngol and Rhinol*. 2017;1:20-31.
- Ndukwe KC, Fatusi OA, Ugboko VI. Craniocervical necrotizing fasciitis in Ile-Ife, Nigeria. *Br J Oral Maxillofac Surg*.

- 2002;40:64-7. doi: 10.1054/bjom.2001.0715. PubMed PMID: 11883974.
15. Obimakinde OS, Okoje VN, Akinmoladun VI, Fasola AO, Arotiba JT. Retrospective evaluation of necrotizing fasciitis in University College Hospital, Ibadan. *Niger J Clin Pract.* 2012;15:344-8. doi: 10.4103/1119-3077.100644. PubMed PMID: 22960973.
 16. Yadav S, Verma A, Sachdeva A. Facial necrotizing fasciitis from an odontogenic infection. *Oral Surg Oral Med Oral Pathol Oral Radiol.* 2012;113:e1-4. doi: 10.1016/j.tripleo.2011.06.010. PubMed PMID: 22669114.
 17. Al-Ali MA, Hefny AF, Idris KM, Abu-Zidan FM. Cervical necrotizing fasciitis: an overlooked diagnosis of a fatal disease. *Acta Otolaryngol.* 2018;138:411-4. doi: 10.1080/00016489.2017.1393841. PubMed PMID: 29105542.
 18. Becker M, Zbaren P, Hermans R, Becker CD, Marchal F, Kurt AM, et al. Necrotizing fasciitis of the head and neck: role of CT in diagnosis and management. *Radiology.* 1997;202:471-6. doi: 10.1148/radiology.202.2.9015076. PubMed PMID: 9015076.
 19. Santos Gorjon P, Blanco Perez P, Morales Martin AC, Del Pozo de Dios JC, Estevez Alonso S, Calle de la Cabanillas MI. Deep neck infection. Review of 286 cases. *Acta Otorrinolaringol Esp.* 2012;63:31-41. doi: 10.1016/j.otorri.2011.06.002. PubMed PMID: 21820639.
 20. Fenton CC, Kertesz T, Baker G, Sandor GK. Necrotizing fasciitis of the face: a rare but dangerous complication of dental infection. *J Can Dent Assoc.* 2004;70:611-5. PubMed PMID: 15473945.
 21. Schütz P, Joshi RM, Ibrahim HHH. Odontogenic necrotizing fasciitis of the neck and upper chest wall. *J Oral Maxillofac Surg Med Pathol.* 2012;24:32-5.
 22. Lorenzini G, Picciotti M, Di Vece L, Pepponi E, Brindisi L, Vessio V, et al. Cervical necrotizing fasciitis of odontogenic origin involving the temporal region--a case report. *J Craniomaxillofac Surg.* 2011;39:570-3. doi: 10.1016/j.jcms.2010.05.002. PubMed PMID: 22036666.
 23. Ricalde P, Engroff SL, Jansisyanont P, Ord RA. Paediatric necrotizing fasciitis complicating third molar extraction: report of a case. *Int J Oral Maxillofac Surg.* 2004;33:411-4. doi: 10.1016/j.ijom.2003.08.008. PubMed PMID: 15145048.
 24. De Backer T, Bossuyt M, Schoenaers J. Management of necrotizing fasciitis in the neck. *J Craniomaxillofac Surg.* 1996;24:366-71. PubMed PMID: 9032605.
 25. Richardson D, Schmitz JP. Chronic relapsing cervicofacial necrotizing fasciitis: case report. *J Oral Maxillofac Surg.* 1997;55:403-8. PubMed PMID: 9120705.
 26. Shindo ML, Nalbene VP, Dougherty WR. Necrotizing fasciitis of the face. *Laryngoscope.* 1997;107:1071-9. PubMed PMID: 9261011.