

# Splenogonadal Fusion Operated as a Malignant Tumor

Mohammad Reza Farzaneh<sup>1</sup>,  
Mohammad Zaki Abbasi<sup>2</sup>, Batool Amini<sup>3</sup>

## Abstract

Splenogonadal fusion is a rare congenital malformation whereby the splenic tissue is found attached or surrounded by the testis, and presents in both continuous and discontinuous forms. Splenogonadal fusion may be misinterpreted as a primary malignant testicular or an adenomatoid tumor. Knowledge about the existence of such an entity is essential in order to preserve the testis during surgical operation. We describe a case of splenogonadal fusion in a young man with bilateral normal oriented scrotal testis.

**Iran J Med Sci 2010; 35(2): 157-159.**

**Keywords** • Neoplasms • Spleen • tumor • testis

## Introduction

Splenogonadal fusion, which is a rare congenital malformation as a consequence of splenic fusion to the early gonad during the weeks 5 to 8 of embryonic development, was first described by Pommer in 1889.<sup>1,2</sup> In male fetus the splenic tissue descends accompanying testis leaving either a fibrous cord containing tiny islands of ectopic spleen or a string of splenic tissue without association to the spleen. These conditions are further designated as the continuous or discontinuous sub-categories, respectively.<sup>3</sup>

Although splenogonadal fusion is more prevalent in male patients, it affects both genders, and is seldom diagnosed pre-operatively. The ectopic splenic tissue is mostly localized at the upper pole of the left testis and is potentially mistaken for a malignant testicular or an adenomatoid epididymis tumor. Since its first description in 1889, more than 150 cases have been presented worldwide in the literature; of them two patients had the fusion in right testis and a few cases have been reported in females.<sup>4</sup> Because of inaccessibility of ovary for clinical examination, accurate incidence of splenogonadal fusion in female patients might have been neglected. Clinical presentation is typically a testicular mass, which is incidentally observed at orchiopexy. Here we report a patient with splenogonadal fusion who underwent surgical operation with the chief complaint of a painless testicular mass.

## Case Report

A 19-year-old, well developed, well nourished male patient with both descended testicles was referred to the urology clinic because of a left scrotal mass for 5 years. Clinical examinations revealed an enlarged non-tender left testis and subsequent ultrasonographic study revealed a dimensionally small testis (28×18.5×15 mm) with a hypoechoic mass measuring 28×23×15 mm in the lower pole of the left testis

<sup>1</sup>Department of Pathology,

<sup>2</sup>Department of Urology,  
Fatemeh Zahra Hospital,  
Faculty of Medicine,

<sup>3</sup>Educational Development Center,  
Bushehr University of Medical Sciences,  
Bushehr, Iran.

### Correspondence:

Mohammad Reza Farzaneh MD,  
Department of Pathology,  
Fatemeh Zahra Hospital,  
Bushehr University of Medical Sciences,  
Bushehr, Iran.

**Tel:** +98 917 3713415

**Fax:** +98 771 2541823

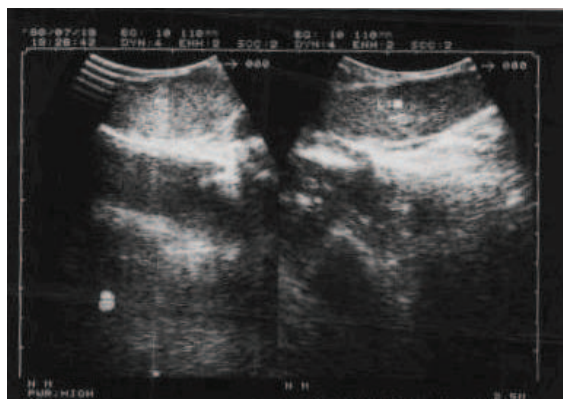
**Email:** mrfarzaneh@yahoo.com

Received: 24 May 2009

Revised: 7 July 2009

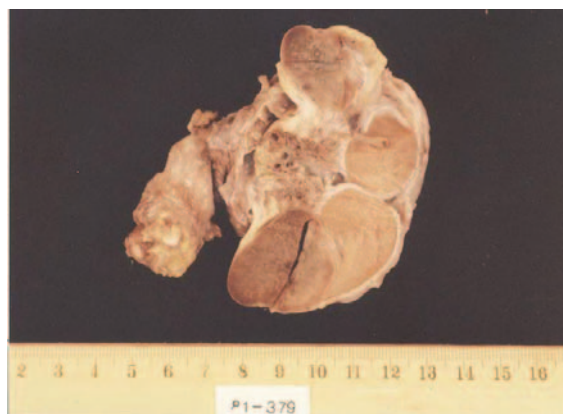Accepted: 14 September 2009

(figure 1). Both the right testis and epididymis were normal. Abdominal ultrasonography showed normal spleen. Other organs such as heart, abdomen, lungs, and reticuloendothelial system were examined and no congenital anomaly was detected.



**Figure 1:** The testicular tumor in ultrasonography that revealed a well circumscribed hypoechoic mass.

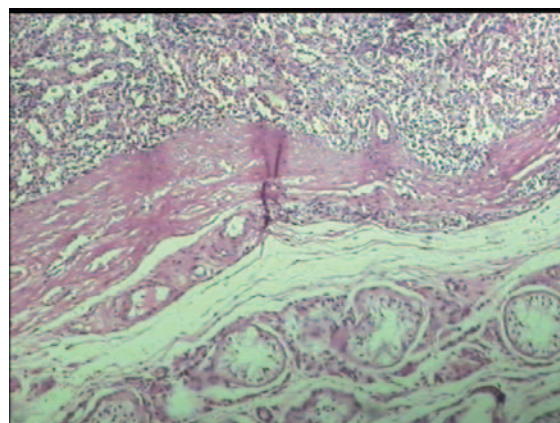
Although tumor markers such as chorionic gonadotropin hormone and  $\alpha$ -fetoprotein (AFP) levels were normal, the patient was recommended for left orchiectomy with suspicion of malignant tumor. After preparation, he underwent left inguinal exploration and there was a firmly dark red mass attached by sharp margins to testis with a thick fibrous band and there was no connection between the spleen and the mass (figure 2).



**Figure 2:** Gross specimen showing discontinuous splenogonadal fusion.

No additional connection to other abdominal organs was found. Orchiectomy was performed and subsequently the specimen was submitted to the pathology department for further investigation. Multiple serial cut sections showed a

well-defined dark red brown encapsulated tumoral tissue attached to testis without necrosis or hemorrhage. Microscopic evaluation of the specimen showed the splenic tissue separated from normal testicular tubules by a dense fibrous band. No evidence of dysplasia or malignancy was observed (figure 3). The postoperative course was uneventful. And he remained well 48 months after the operation.



**Figure 3:** Splenogonadal fusion. Normal testicular tubules (lower right) and splenic tissue (upper left) separated by a fibrous band. (HE  $\times$  200)

## Discussion

Approximately 150 cases of splenogonadal fusion have been reported since 1889.<sup>2</sup> The most recent comprehensive review of splenogonadal fusion was in 1990 by Carrgher.<sup>5</sup> In 1990, about 120 cases of such disease had been reported in the literature. Approximately one fifth were not discovered until autopsy. Seventy-one (56%) were continuous and fifty-two (44%) were discontinuous. The study reported a male:female ratio of 16:6.1. However, the incidence of splenogonadal fusion in female patients has been underestimated because of the inability to palpate the female gonads by routine physical examination. All the cases described in female patients are the continuous type and have been found at autopsy or as an incidental finding at laparotomy.<sup>1,5,6</sup> One-third of splenogonadal fusion cases are associated with other congenital anomalies including limb and orofacial malformation and more likely are in the continuous form.<sup>7</sup>

During the 5th week of gestation, the stomach is displaced toward the left of the median plane and rotates around its axis. It is proposed that an insult occurring during this period can cause a fusion between the sur-

face of the developing genital ridge and the splenic anlagen.<sup>8</sup>

In 1956, Putschar and Manion reported two distinct types of splenogonadal fusion. Continuous fusion is manifested as a cord of spleen or fibrous tissue, which associates the abdominal spleen and gonad. In discontinuous form the ectopic tissue has no connection to the spleen.<sup>2</sup> Karaman and Gonzales have reported that 55% of the 137 cases worldwide have the continuous type,<sup>9</sup> which carries a higher risk of accompanying abnormalities.<sup>10,11</sup> Limb defects, micrognathia, cryptorchidism, anal atresia, ventricular septal defects, microgastria, craniosynostosis, thoracopagus, spina bifida, diaphragmatic hernia, hypoplastic lung, and abnormal lung fissures have all been reported to be concurrent with splenogonadal fusion.<sup>12,13</sup>

In 1994, Nyari and Papp,<sup>14</sup> proposed sonographic diagnosis of splenogonadal fusion; however, computed tomography or magnetic resonance imaging could be more sensitive for preoperative assessment. Review of the literature shows that previous cases are adults but cases that reported recently have been very young and nearly half of them presented below 10 years of age.<sup>15,16</sup> Our case is a classic type of such fusion and is the first report from Iran. The present case resembles other cases that have been reported previously. In our center, because of the unfamiliarity of surgeons with frozen section diagnosis and fine needle aspiration especially in visceral organs and testis, we were not able to preserve the testis. We should consider splenogonadal fusion as a differential diagnosis of testicular enlargement and further imaging studies, fine needle aspiration, and frozen section diagnosis must be taken into account to avoid unnecessary orchiectomy.

### Conclusion

Splenogonadal fusion is a rare cause of testicular mass and requires more attention at the time of diagnosis. Increasing awareness of this congenital malformation can allow for a prompt diagnosis and avoid unnecessary orchiectomy. To preserve the testicles, pre-operative identification of SGF is obligatory. Also further evaluation of the ectopic tissue with fine needle aspiration biopsy, imaging examinations and frozen section diagnosis is recommended.

**Conflict of Interest:** None declared

### References

- 1 Andrews RW, Copeland DD, Fried FA. Splenogonadal fusion. *J Urol* 1985; 133:1052-3.
- 2 Putschar WGJ, Manion WC. Splenicgonadal fusion *AM J Pathol* 1956: 15-35.
- 3 Knorr PA, Borden TA. Splenogonadal fusion. *Urology* 1994; 44:136-8.
- 4 Thomsen BM, Wierod FS, Rasmussen KC. Combined malignant testicular tumor and splenogonadal fusion. A case study. *Scand J Urol Nephrol* 1997; 31: 393-5.
- 5 Carragher AM. One hundred years of splenogonadal fusion. *Urology* 1990; 35: 471-5.
- 6 Chen SL, Kao YL, Sun HS, Lin WL. Splenogonadal fusion. *J Formos Med Assoc* 2008; 107: 892-5.
- 7 Kennedy KP, Barnard S, Speakman MJ. Splenogonadal fusion-not just another hydrocele. *Ann R Coll Sur Engl* 2006; 88:163-4.
- 8 Varma DR, Sirineni GR, Rao MV, et al. Sonographic and CT features of splenogonadal fusion. *Pediatr Radiol* 2007; 37: 916-9.
- 9 Karaman MI, Gonzales ET Jr. Splenogonadal fusion: report of 2 cases and review of the literature. *J Urol* 1996; 155: 309-11.
- 10 Milliken I, Cherian A, Najmaldin A, Powis MR. Splenogonadal fusion: a rare cause of testicular enlargement. *Pediatr Surg Int* 2007; 23: 365-7.
- 11 Meteoglu I, Levi E, Erku M, Culhaci N, Yazici M. Splenogonadal fusion in a bilateral cryptorchidism: a case report. *The Internet Journal of Pathology* 2003; 2: 2.
- 12 Braga LH, Braga MM, Dias MA. Laparoscopic diagnosis and treatment of splenogonadal fusion associated with intra-abdominal cryptorchidism in a child. *Pediatr Surg Int* 1999; 15: 465-6.
- 13 Hizli F, Uygur MC, Irkkan C. Splenogonadal fusion: report of a case. *Int J Urol* 2005; 12: 591-2.
- 14 Nyari E, Papp R, Deak M. Year book of pediatric Radiology. Splenogonadal fusion. Miskole, Hungary: Borsod Country Teaching Hospital; 1994. p. 55-7.
- 15 Wardhan H, Kumar A, Jain N, Khurana V, Aggarwal A. splenogonadal fusion: case report and review of literature. *Pediatr Surg Int* 1993; 8:58-59.
- 16 Al Hashash B, Yadav SK, Mallik A. Splenogonadal fusion in a boy: case report and review of literature. *KMJ* 2008, 40: 72-4.