

Primary Thoracic Wall Hydatid Cyst Extended to the Abdominal wall: A Case Report

Gholamali Godazandeh¹, MD; Farzad Mokhtari-Esbuie², MD; Sara Azooji³, MD

¹Department of Thoracic Surgery, School of Medicine, Mazandaran University of Medical Sciences, Sari, Iran;

²Department of General Surgery, School of Medicine, Iranshahr University of Medical Sciences, Iranshahr, Iran;

³Department of Health Care, School of Medicine, Iranshahr University of Medical Sciences, Iranshahr, Iran

Correspondence:

Farzad Mokhtari-Esbuie, MD;
Unit 8, Apartment 83/2, Kazemi Avenue,
Moalem Street, P.O. Box:48178-43685,
Sari, Iran

Fax: +98 11 32264044

Tel: +98 11 33244496

Email: farzad_mokhtari_s@yahoo.com

Received: 26 May 2019

Revised: 8 July 2019

Accepted: 21 July 2019

Abstract

Hydatid disease (HD) is an infectious disease caused by echinococcosis. Hydatid cyst (HC) most commonly invades the liver (60-70%) and the lungs (20-25%). However, other parts of the body and even unusual locations can be infected, mimicking a benign lesion that could be easily missed. Primary HC of the chest wall is extremely rare, even in countries where echinococcosis is endemic.

We herein present a case of a 40-year-old man with a right-sided growing thoracic wall mass. The patient did not present the relevant history (living in rural areas or being in contact with farm animals) and the serological examination with the indirect hemagglutination test was negative. During surgery, a cystic mass between the eleventh and twelfth ribs was observed. The thoracic wall mass extended to the posterior abdominal wall and was entirely extrapulmonary and extraperitoneal. All cystic structures of the thoracic wall and intrathoracic region were removed, and the primary defect was reconstructed. In endemic areas such as Iran, HD should be considered in the differential diagnosis of mass lesions located in the chest wall or other parts of the body, even without the relevant history or serologic evidence.

Please cite this article as: Godazandeh GA, Mokhtari-Esbuie F, Azooji S. Primary Thoracic Wall Hydatid Cyst Extended to the Abdominal wall: A Case Report. *Iran J Med Sci.* 2020;45(3):220-223. doi: 10.30476/ijms.2019.82036.

Keywords • Echinococcosis • Thoracic wall • Albendazole

What's Known

- Hydatid cysts most commonly invade the liver (60-70%) and the lungs (20-25%). However, other parts of the body and even unusual locations can be infected.
- The primary thoracic wall hydatid cyst is very rare, even in countries where echinococcosis is endemic.

What's New

- Preoperative diagnostic methods for thoracic wall hydatid cyst are not always reliable, since its clinical presentation may mimic benign or malignant cystic tumors.
- In endemic areas, hydatid disease should be considered in the differential diagnosis of mass lesions located in the thoracic wall, even without the relevant clinical history.

Introduction

Hydatid disease (HD) is an infectious disease caused by echinococcosis.¹ Dogs are the definitive hosts, while humans and sheep act as intermediate hosts. Humans and sheep get the infection by eating the vegetables and grass contaminated with ova from dogs' feces.² In humans, three types of echinococcosis are known to occur: cystic echinococcosis caused by *Echinococcus granulosus*, alveolar echinococcosis caused by *Echinococcus multilocularis*, and polycystic echinococcosis due to *Echinococcus Vogeli* or *Echinococcus oligarthrus*. Larvae of the echinococcosis emerge from the eggs in the intestine and can migrate into almost every part of the body after invading blood or lymphatic vessels.³

There is a worldwide prevalence of HD, including Iran, and it is most common among women, as they are typically responsible for food preparation and often care for domestic pets. In most cases, the infection is acquired during childhood, but its clinical signs and symptoms do not usually appear until adulthood.^{4,5} HC most commonly invade the liver (60-70%) and the lungs (20-25%). However, other parts of the body and even unusual

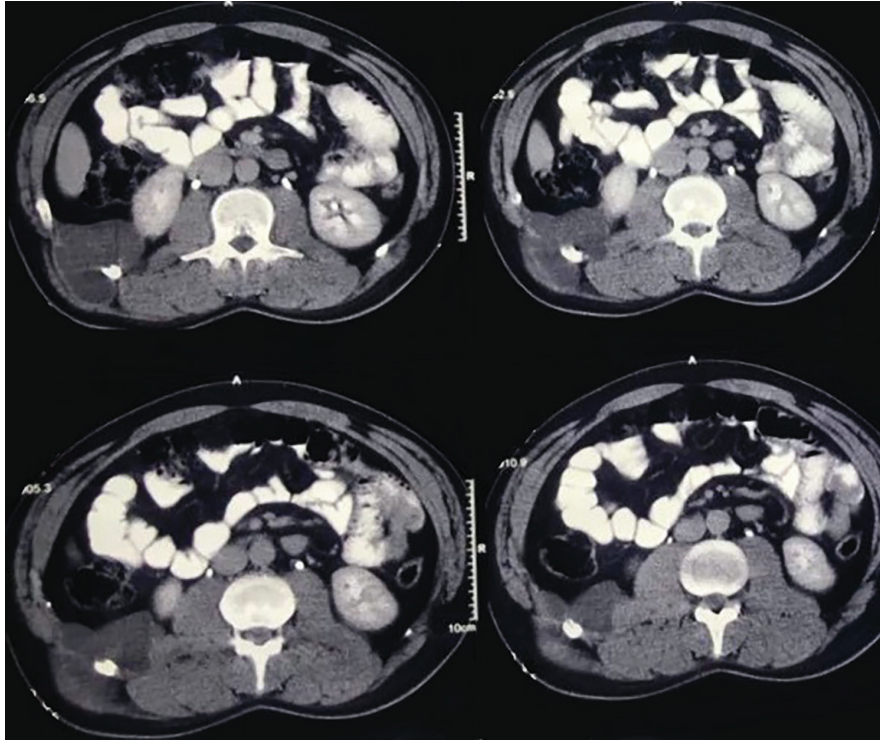


Figure 1: Contrast-enhanced computed tomography (CT) scan showed a large cystic mass between the eleventh and twelfth ribs with extension to the posterior abdominal wall.

locations can be infected, mimicking a benign lesion that could easily be missed.^{6,7}

Primary thoracic wall HC is extremely rare, even in endemic areas. We herein report a case of a primary thoracic wall HC with extension to the posterior abdominal wall presenting itself as a painless mass.

Case Presentation

A 40-year-old man with a right-sided growing thoracic wall mass was referred to Imam Khomeini Hospital (Sari, Iran) in 2015. The painless mass was present for approximately five months and the patient had never lived in rural areas, nor been in contact with farm animals. His past surgical history and family history were unremarkable, and the patient was not jaundiced. Physical examination confirmed that the patient had a non-tender, palpable mass along the right posterolateral thoracic wall. Laboratory test results were normal, and a serological examination with the indirect hemagglutination test for the diagnosis of HD was negative.

A computed tomography (CT) scan revealed a hypodense, cystic mass with septations in the thoracic wall with an extension to the posterior abdominal wall (figure 1). Under general anesthesia, the patient was secured in the left lateral position and a transverse incision was made; revealing a cystic mass between the eleventh and twelfth ribs. Further inspection

showed that the thoracic wall mass extended to the posterior abdominal wall and was entirely extrapulmonary and extraperitoneal (figure 2). Subsequently, all cystic structures of the thoracic wall and intrathoracic region were removed and the primary defect was reconstructed. Histopathological examination of the resected sample indicated HC. The postoperative period was uneventful and the patient was discharged two days after the surgery and had a good recovery. Albendazole 400 mg (Mediva Lifecare, Haryana, India) was prescribed for four weeks postoperatively. During 2 years' follow-up, there were no complications nor any signs of recurrence. Written informed consent was obtained from the patient for the publication of the present case report.

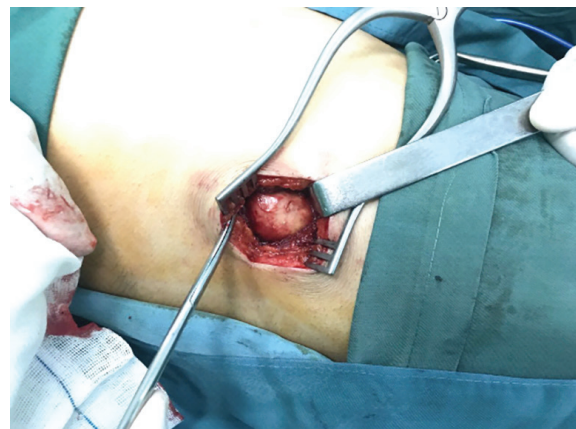

Figure 2: Thoracic wall mass was observed during surgery.

Discussion

A rare case of the primary thoracic wall HC with extension to the posterior abdominal wall is described. Despite several important advances to control HD, the disease remains a major health problem in some countries. It is still an endemic disease in some parts of the world, including South Australia, New Zealand, Africa, South America, Greece, Spain, and the Middle East.⁸ The main risk factor for the disease is living in rural areas. However, the patient in our case never lived in rural areas, nor been in contact with farm animals. HD is also endemic in Iran. In a recent meta-analysis, Shafiei and colleagues evaluated the seroprevalence of the echinococcosis in Iran. The prevalence was higher in the west and southwest of Iran between 0.1 to 15.4%. The pooled estimate of the prevalence of echinococcosis on a random-effect model was estimated about 6%.⁹

The most common causative organism for HD and the only one that causes HC is *Echinococcus granulosus*. Humans are only accidental hosts and do not play a part in the life cycle of the parasite. The eggs are released from their cover after moving to the humans' gastrointestinal system, then the larvae invade the jejunum's mucosa and are transferred to every part of the body by venous and lymphatic channels, and gradually enlarged after transforming into small cysts.¹⁰ HCs are found in all parts of the body such as the cardiovascular system, brain, kidney, mediastinum, and even unusual locations such as the chest wall.⁶ Thoracic wall HC often occurs due to previous hepatic cyst rupture or fistulation. A previous study reported a thoracic wall HC due to the rupture of a hepatic cyst.¹¹ Another study reported a case of a primary thoracic wall HC with a painful chest wall mass.¹² They also stated that primary HC of the chest wall is extremely rare, and there are as few as 10 reported cases in the literature.

There are two theories for primary thoracic wall HC. The first theory is the local spread from the surrounding chest organ with the vanishing of the primary source. The second theory is when the embryo crosses the duodenal wall into the portal vein or the periduodenal and perigastric lymphatics, which are linked with the thoracic lymphatic and ducts.¹⁰ The second theory may explain the formation of the primary HC of the chest wall in our patient because there was no sign of HC in the liver or lung of our patient.

The symptoms of HD are sometimes absent and, in many cases, the infection is detected only incidentally by imaging studies. Its symptoms depend on the host organ, location,

its effect on adjacent structures, complications due to rupture, secondary infections, and immunological reactions caused by the cyst.⁶ Argaw and colleagues stated that patients with HD often have a history of contact with domestic animals. They described a case of a 36-year-old housewife with a history of living in rural areas and being in contact with farm animals.¹⁰ However, as in our case, sole reliance on the patient's history and laboratory results could prove to be deceptive. Sometimes HC presents itself as an inert, painless, and non-inflammatory mass without any deterioration of the patient's general condition. Its clinical manifestations in most parts of the body are too non-specific to make a diagnosis based on the signs and symptoms before surgery.⁶ The most commonly used serologic tests are the latex agglutination test, indirect hemagglutination test, enzyme-linked immunosorbent assay (ELISA), and polymerase chain reaction test. ELISA and the indirect hemagglutination test are most common but may produce false-negative results.¹³ In our study, the serological examination with the indirect hemagglutination test was negative. The best diagnostic tests for HC are radiologic imaging modalities. Ultrasonography, computed tomography (CT) scan, and magnetic resonance imaging (MRI) constitute the most frequently used imaging techniques. The main radiologic findings include thick cyst wall, calcification, daughter cyst, and germinal membrane separated from the cyst wall. MRI and CT-scan are necessary for localizing the cysts, thus they are useful for optimizing surgical planning.¹⁴ In our case, a thoracic and abdominal CT-scan was performed before planning for surgery. The scan showed a hypodense, cystic mass with septations located in the thoracic wall extended to the posterior abdominal wall.

Untreated HC can rupture and spread with adverse consequences. complete surgical resection of the intact cyst is a choice of treatment. Leakage of the cyst content can lead to anaphylaxis or late local recurrence. If the complete excision is impossible, the cyst content (membrane, daughter cyst, and fluid) must be removed. Then, the cyst cavity must be irrigated by scolicedal agents. If there is no bone involvement, as in our patient, the cure rate is high.¹⁵ In the present case, after further inspections during surgery and confirmation of the diagnosis, we removed all parts of the cyst from the thoracic and abdominal walls. In cases with thoracic wall HC, preoperative diagnostic methods are not always reliable. Clinical presentations are non-specific and may mimic benign or malignant cystic tumors, metastases,

abscesses, pseudocysts, hematomas, or other lesions. Unless this is kept in mind, the diagnosis of HD may easily be missed because of its unusual presentation, deceptive history, and inconclusive examination results. In the present study, the lack of relevant patient's history and the false-negative serological result posed a diagnostic challenge. The exact preoperative diagnosis of HD is critical because of the risks of anaphylaxis or the spread of daughter cysts with subsequent recurrence.

Conclusion

In endemic areas such as Iran, HD should be considered in the differential diagnosis of mass lesions in the chest wall or other parts of the body, even without the relevant history or serologic evidence.

Conflict of Interest: None declared.

References

- 1 HAgudelo Higuera NI, Brunetti E, McCloskey C. Cystic Echinococcosis. *J Clin Microbiol.* 2016;54:518-23. doi: 10.1128/JCM.02420-15. PubMed PMID: 26677245; PubMed Central PMCID: PMC4767951.
- 2 Pedrosa I, Saiz A, Arrazola J, Ferreiros J, Pedrosa CS. Hydatid disease: radiologic and pathologic features and complications. *Radiographics.* 2000;20:795-817. doi: 10.1148/radiographics.20.3.g00ma06795. PubMed PMID: 10835129.
- 3 Eckert J, Gemmell M, Meslin F, Pawlowski Z. WHO/OIE manual on echinococcosis in humans and animals: a public health problem of global concern 2001. Geneva: World Organisation for Animal Health; p. 56-60.
- 4 Ertabaklar H, Dayanir Y, Ertug S. Research to investigate human cystic echinococcosis with ultrasound and serologic methods and educational studies in different provinces of Aydin/Turkey. *Turkiye Parazitoloj Derg.* 2012;36:142-6. doi: 10.5152/tpd.2012.34. PubMed PMID: 23169156.
- 5 Karaman U, Miman O, Kara M, Gicik Y, Aycan OM, Atambay M. Hydatid cyst prevalence in the region of Kars. *Turkiye Parazitoloj Derg.* 2005;29:238-40. PubMed PMID: 17124677.
- 6 Geramizadeh B. Unusual locations of the hydatid cyst: a review from Iran. *Iran J Med Sci.* 2013;38:2-14. PubMed PMID: 23645952; PubMed Central PMCID: PMC3642939.
- 7 Karapolat S, Dumlu T, Yildirim U, Karapolat B, Erbas M. Primary hydatid cyst of the chest wall. *Lung.* 2012;190:583-5. doi: 10.1007/s00408-011-9368-2. PubMed PMID: 22249910.
- 8 McManus DP, Zhang W, Li J, Bartley PB. Echinococcosis. *Lancet.* 2003;362:1295-304. doi: 10.1016/S0140-6736(03)14573-4. PubMed PMID: 14575976.
- 9 Shafiei R, Teshnizi SH, Kalantar K, Gholami M, Mirzaee G, Mirzaee F. The Seroprevalence of Human Cystic Echinococcosis in Iran: A Systematic Review and Meta-Analysis Study. *J Parasitol Res.* 2016;2016:1425147. doi: 10.1155/2016/1425147. PubMed PMID: 27830083; PubMed Central PMCID: PMC5086504.
- 10 Argaw F, Abebe E, Tsehay A. Primary chest wall hydatid cyst, case report & review of literature. *Annals of Clinical Case Reports.* 2017;2:1245.
- 11 Thomopoulos T, Naiken S, Rubbia-Brandt L, Mentha G, Toso C. Management of a ruptured hydatid cyst involving the ribs: Dealing with a challenging case and review of the literature. *Int J Surg Case Rep.* 2012;3:253-6. doi: 10.1016/j.ijscr.2012.03.010. PubMed PMID: 22503916; PubMed Central PMCID: PMC3356538.
- 12 Salih AM, Ahmed DM, Kakamad FH, Essa RA, Hunar AH, Ali HM. Primary chest wall Hydatid cyst: Review of literature with report of a new case. *Int J Surg Case Rep.* 2017;41:404-6. doi: 10.1016/j.ijscr.2017.10.051. PubMed PMID: 29546002; PubMed Central PMCID: PMC5699876.
- 13 Salih AM, Kakamad FH, Hammood ZD, Yasin B, Ahmed DM. Abdominal wall Hydatid cyst: A review a literature with a case report. *Int J Surg Case Rep.* 2017;37:154-6. doi: 10.1016/j.ijscr.2017.06.022. PubMed PMID: 28683329; PubMed Central PMCID: PMC5498266.
- 14 Ousadden A, Elboughdouti H, Ibnmajdoub KH, Mazaz K, Aittaleb K. A solitary primary subcutaneous hydatid cyst in the abdominal wall of a 70-year-old woman: a case report. *J Med Case Rep.* 2011;5:270. doi: 10.1186/1752-1947-5-270. PubMed PMID: 21722386; PubMed Central PMCID: PMC3152916.
- 15 Dirican A, Unal B, Kayaalp C, Kirimlioglu V. Subcutaneous hydatid cysts occurring in the palm and the thigh: two case reports. *J Med Case Rep.* 2008;2:273. doi: 10.1186/1752-1947-2-273. PubMed PMID: 18700983; PubMed Central PMCID: PMC2533018.