

Manifestation of Ocular Myasthenia Gravis as an Initial Symptom of Coronavirus Disease 2019: A Case Report

Neda Rahimian¹, MD; Nazanin Alibeik², MD; Elham Pishgar³, MD; Parisa Dini², MD; Meysam Abolmaali⁴, MD; Zahra Mirzaasgari^{4,5}, MD

¹Endocrine Research Center, Institute of Endocrinology and Metabolism, Iran University of Medical Sciences, Tehran, Iran;

²Firoozgar Clinical Research Development Center, Iran University of Medical Sciences, Tehran, Iran;

³Gastrointestinal and Liver Diseases Research Center, Iran University of Medical Sciences, Tehran, Iran;

⁴Shefa Neuroscience Research Center, Khatam Alanbia Hospital, Tehran, Iran;

⁵Department of Neurology, Firoozgar Hospital, School of Medicine, Iran University of Medical Science, Tehran, Iran

Correspondence:

Zahra Mirzaasgari, MD;
Firoozgar Hospital, Behafarin St.,
Karimkhan Ave., Postal code:
593747811, Tehran, Iran
Tel/Fax: +98 21 82141000
Email: Zahra.mirzaasgari@gmail.com
Received: 21 January 2021
Revised: 17 March 2021
Accepted: 05 June 2021

What's Known

- A few studies have reported the flare-up of pre-existing myasthenia gravis (MG) due to COVID-19.
- So far, only three cases with the onset of MG following COVID-19 have been reported.

What's New

- In contrast to previous cases of post-COVID-19 MG, we present the first case of seronegative MG in a patient that developed ocular MG four days prior to exhibiting typical COVID-19 symptoms.
- Despite the cessation of pyridostigmine therapy, the patient was symptom-free following anti-COVID-19 treatment.

Abstract

For a while, coronavirus disease-2019 (COVID-19) has been a major global pandemic. It primarily affects the respiratory system but has extrapulmonary manifestations such as gastrointestinal and neurological symptoms. Data on myasthenia gravis (MG), as a complication of COVID-19, are limited. We herein report the manifestation of ocular MG as an initial symptom of COVID-19.

In November 2020, a 31-year-old healthy woman was referred to Firoozgar Hospital (Tehran, Iran) with left upper eyelid ptosis and diplopia as well as general weakness, myalgia, fever, and nasal congestion for four days prior to admission. Although the acetylcholine receptor antibody in her serum was negative, increased jitter in several muscles led to the diagnosis of ocular MG. Nasal swab reverse transcription-polymerase chain reaction (RT-PCR) assay tested positive for severe acute respiratory syndrome-coronavirus-2 (SARS-CoV-2) infection. Computed tomography (CT) scan of the chest revealed bilateral ground-glass opacities and some foci of consolidation formation, but the thymus was normal. The patient was successfully treated with remdesivir and dexamethasone. The patient was eventually discharged in good condition and with improved neurological symptoms.

A limited number of studies have suggested a possible association between MG and COVID-19. Therefore, further data are required to substantiate the proposed association. Clinicians should be aware of ocular MG during the COVID-19 pandemic to better diagnose and manage patients with SARS-CoV-2 infection.

Please cite this article as: Rahimian N, Alibeik N, Pishgar E, Dini P, Abolmaali M, Mirzaasgari Z. Manifestation of Ocular Myasthenia Gravis as an Initial Symptom of Coronavirus Disease 2019: A Case Report. Iran J Med Sci. 2022;47(4):385-388. doi: 10.30476/IJMS.2021.89841.2061.

Keywords • COVID-19 • Myasthenia gravis • SARS-CoV-2 • Case report

Introduction

Severe acute respiratory syndrome-coronavirus-2 (SARS-CoV-2) is an enveloped positive-strand ribonucleic acid (RNA) virus that infects humans and causes coronavirus disease-2019 (COVID-19). SARS-CoV-2 primarily affects the respiratory system but has also extrapulmonary manifestations such as gastrointestinal and neurological symptoms.¹ Several studies have reported SARS-CoV-2 infection-related neurological involvement such as cranial neuropathy, encephalopathy, and Guillain-Barré syndrome.² However, information about

neuromuscular complications is still limited.³

Myasthenia gravis (MG) is an autoimmune disorder affecting the neuromuscular junction (NMJ) causing skeletal muscle weakness and fatigue. It can be confined to ocular muscles, but may affect extraocular muscles, whereby autoantibodies are directed against nicotinic acetylcholine receptors at the NMJ. These antibodies are detected in 80% and 55% of patients with generalized and ocular MG, respectively. Viral infections are recognized as the cause of the myasthenic crisis in patients with a history of MG. However, there is no clear evidence that viral infections could lead to MG in healthy individuals. We, herein, report the occurrence of ocular MG due to SARS-CoV-2 infection in a patient without a history of neurological disorders.

Case Presentation

In November 2020, a 31-year-old woman was referred to Firoozgar Hospital (Tehran, Iran) with left upper eyelid ptosis as well as general weakness, myalgia, fever, and nasal congestion for four days prior to admission. She had no difficulties in chewing nor showed signs of dysphagia, and her medical history was unremarkable. However, her mother suffered from ulcerative colitis, type II diabetes mellitus, and Hashimoto's thyroiditis, while her father had Graves' disease. She had prior exposure to COVID-19 patients because of her profession as a healthcare worker. Physical examination after applying ice packs improved left upper eyelid ptosis and diminished weakness of the orbicularis oculi muscle (figure 1). Horizontal diplopia occurred on left gaze after 15 sec. Neurological examinations were also unremarkable. The result of slow repetitive nerve stimulation was negative for abductor pollicis brevis, abductor digiti minimi, anconeus, trapezius, and nasalis muscles. Single-fiber electromyography (SFEMG) was also performed using a concentric needle and 18 pairs were collected, in which 12 pairs had increased jitters

and the mean and median jitters were abnormal. Acetylcholine receptor antibody (AChR-Ab) level in the serum was <0.3 nmol/L (normal: <0.4).

Nasal swab reverse transcription-polymerase chain reaction (RT-PCR) assay tested positive for SARS-CoV-2 infection. A spiral computed tomography (CT) scan of the chest showed diffuse bilateral ground-glass opacities and some foci of consolidation formation in the right upper, left, and right lower lobes (figure 2). Notably, the thymus was normal. The patient had lymphopenia (absolute lymphocyte count was 869), and extensive laboratory findings showed elevated inflammatory markers, including serum C-reactive protein (36 mg/L; normal: <10) and serum estimated sedimentation rate (25 mm/h). Furthermore, thyroid function tests and other clinical laboratory examinations of blood or plasma analysis were normal.

Four days after the onset of fever, she was admitted to our hospital with dyspnea, non-productive cough, and severe malaise. The patient was subsequently treated with dexamethasone and remdesivir. Prior to admission, the patient used pyridostigmine 60 mg thrice daily, but her ocular symptoms did not improve, and the treatment with the drug was discontinued after hospitalization. The ocular symptoms of the patient lasted for 14 days. Five days after admission, the patient was discharged in a good condition and stable hemodynamic parameters. Ptosis and muscle weakness were completely resolved. A follow-up examination three months later did not reveal any signs or

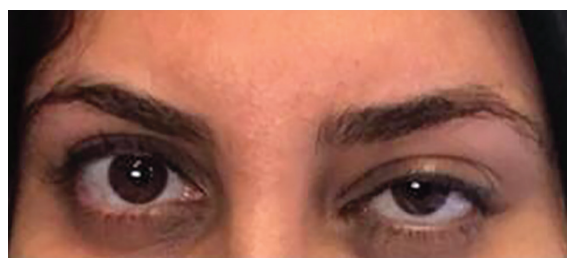


Figure 1: The figure shows the patient with left upper eyelid ptosis.

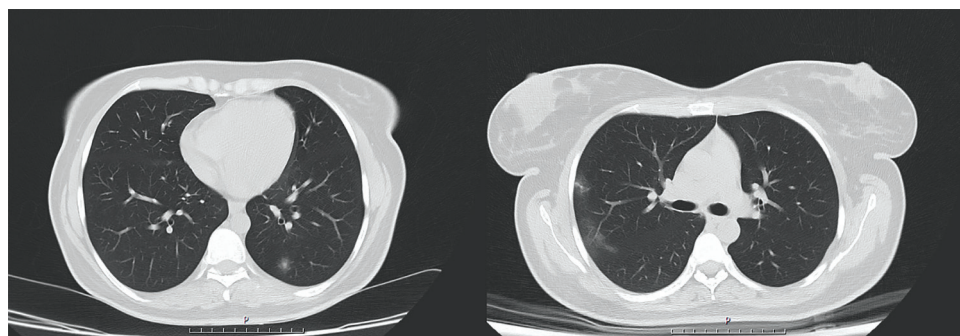


Figure 2: Chest CT imaging shows diffuse bilateral ground-glass opacities with some foci of consolidation formation in the right upper, left, and right lower lobes.

Table 1: Details of myasthenia gravis cases infected with COVID-19

Articles	Sex	Age	Chest involvement	AChR-Ab	oMG/gMG	First presentation	Hx of autoimmune disease in case or family	Response to pyridostigmine	
Sriwastava et al. ⁷	F	65	Yes	Positive	oMG	Diarrhea+ myalgia	Unknown	Yes	
Huber et al. ⁸	F	21	No	Positive	oMG	Rhinitis	Positive	Yes	
Restivo et al. ⁹	Case 1	M	64	No	Positive	oMG	Fever	Unknown	Yes
	Case 2	M	68	Yes	Positive	gMG	Fever	Unknown	Not administered
	Case 3	F	71	Yes	Positive	gMG	Fever+cough	Unknown	Not administered
Current study	F	31	Yes	Negative	oMG	Eyelid ptosis	Positive	No	

Hx: History; oMG: Ocular myasthenia gravis; gMG: Generalized myasthenia gravis; M: Male; F: Female; AChR-Ab: Acetylcholine receptor antibody

symptoms due to the disease despite no specific treatment for MG. Written informed consent was obtained from the patient for publication of medical images and data.

Discussion

Various factors such as infections, drugs, and pollutants play an important role in promoting autoimmune diseases. Considering the autoimmune pathogenesis of MG, infections interfering with the immune system may have an aggravating effect. Several studies have reported the flare-up of pre-existing MG condition due to COVID-19.⁴⁻⁶ However, there are only a few studies on post-COVID-19 MG. A few recent case studies on three patients (two case reports and one case series) have reported the onset of MG following COVID-19 (table 1).⁷⁻⁹

To the best of our knowledge, in contrast to previous cases of post-COVID-19 MG, we present the first case of seronegative MG. Our patient developed typical COVID-19 symptoms several days after developing ptosis and ophthalmoplegia. Therefore, we proposed ocular MG as the initial presentation of COVID-19. None of the previous studies have reported such a finding in patients with COVID-19. Although our patient had no pre-existing illnesses, particularly neuromuscular disorders, her family history was positive for autoimmune disease. Therefore, we believe that our patient may have had subclinical MG triggered by COVID-19.

In contrast to previously reported cases, our patient responded remarkably to anti-COVID-19 treatment (remdesivir and corticosteroid), and her ocular symptoms were significantly ameliorated after recovery from COVID-19. Despite the cessation of anticholinesterase inhibitor drugs, the patient was symptom-free after three months of follow-up. As a limitation of our study, we should have performed SFEMG and AChR-Ab tests during the patient follow-up.

Conclusion

MG, particularly ocular MG, may manifest itself as an initial symptom of SARS-CoV-2 infection. Clinicians should pay attention to this manifestation during the COVID-19 pandemic. Further studies are required to substantiate an association between COVID-19 and MG.

Acknowledgment

We would like to express our gratitude to Dr. F. Fatehi and Dr. B. Haghi Ashtiani for their collaboration and to the patient for her participation.

Authors' Contribution

N.R: History collection and background research, reviewed the results and drafted and revised the manuscript, N.A: Involved in patient management, background research, reviewed results and drafted and revised the manuscript, E.P: Background research, reviewed the results and drafted and revised the manuscript, P.D: Background research, reviewed the results and drafted and revised the manuscript, M.A: Reviewed the results and revised the manuscript Z.M: Involved in patient management, background research and drafted the manuscript. All authors have read and approved the final manuscript and agree to be accountable for all aspects of the work in ensuring that questions related to the accuracy or integrity of any part of the work are appropriately investigated and resolved.

Conflict of Interest: None declared.

References

- Mottaghi A, Roham M, Makiani MJ, Ranjbar M, Laali A, Rahimian NR. Verifying Extra-Pulmonary Manifestation of COVID-19

- in Firoozgar Hospital 2020: An Observational Study. Research Square. 2021. doi: 10.21203/rs.3.rs-147631/v1.
- 2 Abolmaali M, Heidari M, Zeinali M, Moghadam P, Ramezani Ghamsari M, Jamshidi Makiani M, et al. Guillain-Barre syndrome as a parainfectious manifestation of SARS-CoV-2 infection: A case series. *J Clin Neurosci.* 2021;83:119-22. doi: 10.1016/j.jocn.2020.11.013. PubMed PMID: 33281050; PubMed Central PMCID: PMC7666532.
 - 3 Guidon AC, Amato AA. COVID-19 and neuromuscular disorders. *Neurology.* 2020;94:959-69. doi: 10.1212/WNL.00000000000009566. PubMed PMID: 32284362.
 - 4 Rein N, Haham N, Orenbuch-Harroch E, Romain M, Argov Z, Vaknin-Dembinsky A, et al. Description of 3 patients with myasthenia gravis and COVID-19. *J Neurol Sci.* 2020;417:117053. doi: 10.1016/j.jns.2020.117053. PubMed PMID: 32731059; PubMed Central PMCID: PMC7832365.
 - 5 Paliwal VK, Garg RK, Gupta A, Tejan N. Neuromuscular presentations in patients with COVID-19. *Neurol Sci.* 2020;41:3039-56. doi: 10.1007/s10072-020-04708-8. PubMed PMID: 32935156; PubMed Central PMCID: PMC7491599.
 - 6 Hubers A, Lascano AM, Lalive PH. Management of patients with generalised myasthenia gravis and COVID-19: four case reports. *J Neurol Neurosurg Psychiatry.* 2020;91:1124-5. doi: 10.1136/jnnp-2020-323565. PubMed PMID: 32651248.
 - 7 Sriwastava S, Tandon M, Kataria S, Daimee M, Sultan S. New onset of ocular myasthenia gravis in a patient with COVID-19: a novel case report and literature review. *J Neurol.* 2021;268:2690-6. doi: 10.1007/s00415-020-10263-1. PubMed PMID: 33047223; PubMed Central PMCID: PMC7549728.
 - 8 Huber M, Rogozinski S, Puppe W, Framme C, Hoglinger G, Hufendiek K, et al. Postinfectious Onset of Myasthenia Gravis in a COVID-19 Patient. *Front Neurol.* 2020;11:576153. doi: 10.3389/fneur.2020.576153. PubMed PMID: 33123081; PubMed Central PMCID: PMC7573137.
 - 9 Restivo DA, Centonze D, Alesina A, Marchese-Ragona R. Myasthenia Gravis Associated With SARS-CoV-2 Infection. *Ann Intern Med.* 2020;173:1027-8. doi: 10.7326/L20-0845. PubMed PMID: 32776781; PubMed Central PMCID: PMC7429993.