

Pachydermoperiostosis in a Patient with Crohn's Disease: Treatment and Literature Review

Maryam Mobini¹, MD;
Ozra Akha¹, MD;
Hafez Fakheri², MD;
Hadi Majidi³, MD;
Sanam Fattahi⁴, MD

¹Department of Internal Medicine, Diabetes Research Center, Faculty of Medicine, Mazandaran University of Medical Sciences, Sari, Iran;

²Department of Gastroenterology, Inflammatory Gut and Liver Research Center, Mazandaran University of Medical Sciences, Sari, Iran;

³Department of Radiology, Orthopedic Research Center, Faculty of Medicine, Mazandaran University of Medical Sciences, Sari, Iran;

⁴Medical Student, Faculty of Medicine, Mazandaran University of Medical Sciences, Sari, Iran

Correspondence:

Maryam Mobini, MD;
Imam Khomeini Hospital,
Razi Street, Sari, Iran

Tel: +98 11 33350672

Fax: +98 11 33264044

Email: mmobini50@yahoo.com

Received: 09 November 2016

Accepted: 04 December 2016

What's Known

- Pachydermoperiostosis (PDP) is a rare disorder characterized by skin thickening, digital clubbing, proliferation of periosteum with subperiosteal new bone formation, and an excess of affected males.
- PDP usually develops in teenage years and often presents with clubbing and enlargement of the distal extremities. Association of PDP with other disorders is also reported.

What's New

- We report a patient with Crohn's disease associated with PDP.
- To our knowledge, this is the fourth such case report in this field. There are interesting photographs of the patient.

Abstract

Pachydermoperiostosis (PDP) is a rare disorder characterized by pachydermia, digital clubbing, periostitis, and an excess of affected males. It is the primary form of hypertrophic osteoarthropathy (HOA) and there are some rare associations of PDP with other disorders. Here we describe a patient with Crohn's disease associated with PDP. A 26-year-old man, who was a known case of Crohn's disease, referred with diffuse swelling in the upper and lower limbs and cutis verticis gyrata since 7 years ago. PDP was suspected and endocrinological and radiological studies were conducted for the evaluation of underlying disease. He was prescribed celecoxib, low-dose prednisolone, and pamidronate to control the swelling, periostitis, azathiopurine, and mesalazine according to gastrointestinal involvement. In conclusion, it is important to identify this condition since a misdiagnosis might subject the patient to unnecessary investigations.

Please cite this article as: Mobini M, Akha O, Fakheri H, Majidi H, Fattahi S. Pachydermoperiostosis in a Patient with Crohn's Disease: Treatment and Literature Review. *Iran J Med Sci*. 2018;43(1):81-85.

Keywords • Pachydermoperiostosis • Cutis verticis gyrata • Crohn's disease • Pamidronate

Introduction

Pachydermoperiostosis (PDP) is a rare disorder characterized by skin thickening (pachydermia), digital clubbing, proliferation of periosteum (periostitis) with subperiosteal new bone formation, and an excess of affected males. Cutis verticis gyrata is a manifestation of PDP and is characterized by excessive formation of scalp skin and mimicking cerebral gyri. PDP usually develops in teenage years and often presents with clubbing and enlargement of the distal extremities. An autosomal dominant model with incomplete penetrance and variable expression has been proven, but both autosomal recessive and X-linked inheritance have been suggested.¹ PDP is the primary form of hypertrophic osteoarthropathy (HOA) and accounts for 5% of all cases of HOA. Secondary HOA is associated with underlying cardiopulmonary diseases and malignancies, thyroid acropachy, acromegaly, and chronic inflammatory rheumatic diseases. Therefore, an intensive search for the underlying malignant disease, especially of thoracic organs should be done. The principal features of PDP include clubbing of the digits, periosteal new bone formation, furrows and coarse facial features, and cutis verticis gyrata. Arthralgia, hyperhidrosis of the feet and hands, gastric hypertrophy or ulcers, and endocrine abnormalities are also reported. Association of

PDP with other disorders such as myelofibrosis² and Crohn's disease³⁻⁵ is also reported. On the other hand, there is limited experience in the treatment of PDP. Cyclooxygenase 2 (Cox 2) inhibitors and/or bisphosphonates have shown some improvements.^{5,6} In persistent knee arthritis, arthroscopic synovectomy and radiosynoviorthesis were performed consecutively with reduced pain and increased range of motion.

Here we report a patient with Crohn's disease associated with PDP. The clinical manifestation, investigation findings, and treatments are reviewed in this paper.

Case Presentation

A 26-year-old man, a known case of Crohn's disease since 2 years ago, referred to a rheumatologist due to diffuse swelling in the upper and lower limbs since one year earlier. The patient complained about changes in the skin of scalp, hyperhidrosis on both palms and soles, and digital clubbing that was presented since 5 years ago. He had no family history of HOA. He suffered from loose stool for 2 years and had a history of surgery for perforated duodenal ulcer. Esophagogastroduodenoscopy (EGD) was normal, but a thickening of jejunum and ileum with narrowing in distal of ileum was found in small bowel series (SBS). During colonoscopy, many aphthous lesions were seen up to cecum (figure 1). Biopsy from ileum showed moderate lymphocytic infiltration with lymphoid follicle formation in lamina propria and some glands in the rectum showed polymorphonuclear exocytosis that resulted in reparative dysplastic changes, destruction, goblet cell depletion, and crypt abscess formation (figure 2). Severe lymphocytic and neutrophilic infiltration in lamina propria and ulceration with granulation tissue formation were also detected.

Based on a history of chronic diarrhea, imaging of small intestine in SBS, multiple aphthous lesions in the colon, and pathology of biopsy, he was diagnosed with Crohn's disease and treatment started by azathiopurine 100 mg/day, mesalamine 3 g/day and calcium-D daily. In physical examinations, he had cutis verticis gyrata, hypertrichosis of eyelids, clubbing of hands and feet, and diffuse swelling of legs and knees, but the range of motion in joints were full (figure 3). Evaluation of other clinical problems, including endocrine (thyroid function test, insulin-like growth factor 1, brain MRI for pituitary gland), pulmonary (lung HRCT), cardiac problems (echocardiography), and malignancy (physical examination, blood test, and lung/

abdomen/pelvic CT scan) were all negative. There was no evidence of hepatosplenomegaly or extramedullary hematopoiesis. Radiographs of the forearm, legs, and hands showed periosteal irregularity in the distal of radius and tibia, subperiosteal resorption on the radial side of proximal phalanges of the 3rd and 4th fingers of both hands. The MRI of knees showed joint effusion with soft tissue swelling. The whole body bone scan showed diffuse uptake throughout the skeleton (figure 4). Laboratory findings were negative for rheumatoid factor (RF), human leukocyte antigen (HLA) B27, and the antinuclear antibodies, but erythrocyte sedimentation rate and C-reactive protein were elevated (table 1).

The patient was prescribed celecoxib (200 mg/day), low-dose prednisolone (10 mg/day), and pamidronate (60 mg/month) to control the swelling and periostitis. Azathiopurine and mesalazine were continued. Three months

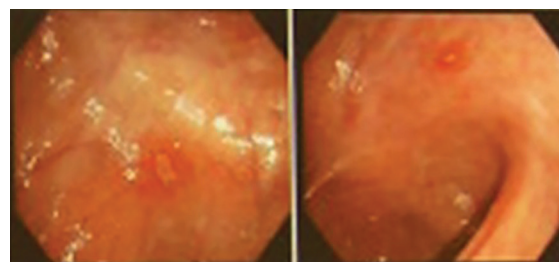


Figure 1: Multiple aphthous lesions were seen in the sigmoid.

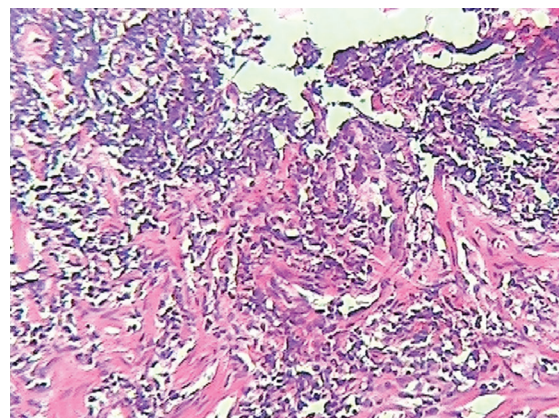


Figure 2: Biopsy of colon demonstrated necrotic material with cell debris and glandular destruction.

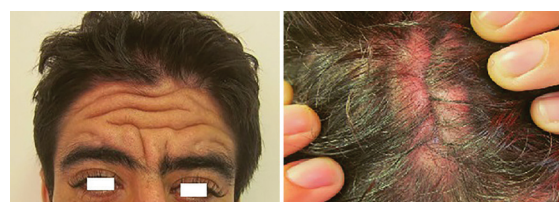

Figure 3: Pronounced forehead skin folds, prominent nasolabial folds, and cutis verticis gyrata in association with lengthened eyelashes.

later, a significant improvement of edema was accorded in both limbs, correction of anemia (Hg: 13.1 g/dl), and decreased ESR (24 mm/h). The patient had no complaints of abdominal pain and diarrhea.

Informed consent was obtained from the patient for the publication of this case report and accompanying images.

Discussion

The diagnosis of PDP is based on the combination of digital clubbing, periostitis, and pachyderma with the absence of any secondary cause, including cardiopulmonary or endocrine diseases and malignancies. Our patient presented with hypertrophic osteoarthropathy and knees swelling. He had Crohn's disease with cutis verticis gyrata, digital clubbing, arthralgia, periosteal new bone formation, and hyperhidrosis. To our knowledge, this is the 4th such case report in this field (table 2).³⁻⁵ In its complete form, PDP is characterized by pachyderma (thickening of the facial skin), skeletal changes (periostosis), excessive sweating (hyperhidrosis), and acropachia (digital clubbing). It is not clear that it is a cutaneous manifestation of Crohn's disease or caused by a shared genetic basis.⁴

Two key challenges in diagnosis were secondary HOA and spondyloarthropathies

associated with inflammatory bowel disease (IBD). For the evaluation of secondary HOA, physical examination, laboratory tests, and investigation of images did not reveal any particular problems. On the other hand, spondyloarthropathies associated with IBD did not match with skin manifestation. Disease inheritance patterns are different.¹ Other family members were not involved in this case and it might be due to autosomal recessive inheritance or incomplete penetrance and variable expression in parents.

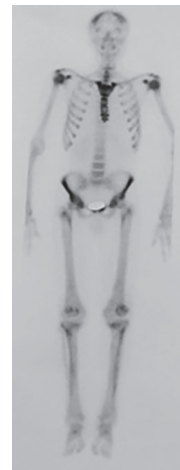

Figure 4: Whole body bone scan, TC 99m-MDP show diffusely uptake throughout the skeleton.

Table 1: Laboratory test results of the patient

Laboratory tests	Results
CBC	WBC: 8,400, Hg: 11.7 g/dl, Plt: 362,000
Acute phase reactants	ESR: 50 mm/h, CRP: 53 mg/l (up to 6)
Biochemical tests	FBS: 83 mg/dl, cholesterol: 121 mg/dl, triglyceride: 64 mg/dl, creatinine: 0.67 mg/dl, ALT: 13 IU/L, ALP: 185 IU/L, albumin: 4.1 g/dl, 25 hydroxy vit D: 13.6 ng/ml
Gastrointestinal tests: result (normal range)	Anti-tissue transglutaminase IgA: 9.8 RU/ML (up to 20), Anti-endomysial Ab IgA: 5.0 RU/ML (up to 20), ASCA-G: 50.7 Au/ml (up to 12)
Rheumatologic tests: result (normal range)	RF: 12 IU/ml (up to 20), ANA: 0.51 U/ml (up to 0.8), Anti-CCP: 4.7 U/ml (up to 12), HLA B 27: negative
Urine biochemistry (24 h)	Urine volume: 2,200 cc, creatinine: 1,548 mg/24 h, protein: 127 mg/24 h, ca: 358 mg/24 h
Endocrinology: result (normal range)	Growth hormone: 3.25 ng/ml (0-5), IGF1: 269.8 ng/ml (188-400), TSH: 2.2 ng/ml (0.4-6)

Table 2: Cases with pachydermoperiostosis and Crohn's disease

Author (year)	Sex (age in years)	Family history	Priority of disorder	Treatment for HOA	Treatment consequences
Shim ³ (1997)	Male (42)	Positive for clubbing	Clubbing	-	-
Ohata ⁴ (2009)	Male (57)	No family history of pachydermoperiostosis	Cutis verticis gyrata and clubbing	-	-
Rhee ⁵ (2014)	Male (27)	No family history of pachydermoperiostosis	Crohn's disease	Celecoxib	Significant improvement
Present case	Male (26)	No family history of pachydermoperiostosis	Clubbing and diffuse limbs edema	Celecoxib, low-dose prednisolone, pamidronate	Significant improvement

The pathophysiology of HOA in Crohn's disease is still unknown and it might be due to secondary HOA related to malignancy that is associated with elevated levels of prostaglandin E2 (PGE2). On the other hand, some evidences showed that inflammation and malignancy led to significantly increased levels of PGE2 and urine PGE-M compared with the normal group.⁷ Impaired metabolism of prostaglandin E2 (PGE2) plays a central role in primary hypertrophic osteoarthropathy pathogenesis. Mutation in the human gene and protein database mutation, gene that encodes the 15-hydroxyprostaglandin dehydrogenase, a key enzyme responsible for the degradation of prostaglandins, leads to high levels of PGs, especially PGE2 and excessive formation of collagen by fibroblast hyper activation.⁸ Circulating factors such as platelet-derived growth factor (PDGF) and vascular endothelial growth factor (VEGF) may have some roles in the pathogenesis of secondary HOA too. The PDGF brings fibroblast proliferation with increased vascularity and permeability, and consequently results in clubbing of the digits and VEGF has a function in angiogenesis and osteoblastic differentiation.⁹ It is suggested that the alteration of extracellular matrix production by fibroblasts might be a possible explanation for the development of PDP. Bisphosphonates have been shown to decrease the level of plasma VEGF in patients with HOA.⁵

Unfortunately, it is difficult to make a standard therapeutic modality for PDP due to the rarity of the condition. The proposed treatment for PDP includes celecoxib and colchicine for articular, folliculitis, pachyderma, pamidronate for rheumatologic manifestations, and isotretinoine for skin symptoms.^{5,10} Taking colchicine could lead to diarrhea and it was not the right choice for this patient because of a possible mistake with Crohn's disease flare up. NSAIDs should be used with caution in Crohn's disease due to flare risk. Thus, we prescribed celecoxib and pamidronate and added prednisolone because of some degree of diarrhea. Our patient had 7 years history of skin and skeletal manifestation. The diagnosis was delayed due to the slow and progressive development of manifestation.

Conclusion

To our knowledge, this is the fourth reported case of Crohn's disease and PDP in the literature. Because of some musculoskeletal manifestation of spondyloarthropathies or malignancies in Crohn's disease that might be mistaken with PDP, it is important to identify this condition

since misdiagnosis might subject the patient to unnecessary investigations or treatments.

Acknowledgement

The authors would like to acknowledge the patient and his family for their cooperation.

Conflict of Interest: None declared.

References

1. Castori M, Sinibaldi L, Mingarelli R, Lachman RS, Rimoin DL, Dallapiccola B. Pachydermoperiostosis: An update. *Clin Genet.* 2005;68:477-86. doi: 10.1111/j.1399-0004.2005.00533.x. PubMed PMID: 16283874.
2. Saghafi M, Azarian A, Nohesara N. Primary hypertrophic osteoarthropathy with myelofibrosis. *Rheumatol Int.* 2008;28:597-600. doi: 10.1007/s00296-007-0477-4. PubMed PMID: 18038138.
3. Shim YW, Suh JS. Primary hypertrophic osteoarthropathy accompanied by Crohn's disease: A case report. *Yonsei Med J.* 1997;38:319-22. doi: 10.3349/ymj.1997.38.5.319. PubMed PMID: 9409195.
4. Ohata K, Niinami C, Ohya T, Inamori M, Nakajima A, Kurose N, et al. Education and imaging: Gastrointestinal: Pachydermoperiostosis associated with Crohn's disease. *J Gastroenterol Hepatol.* 2009;24:1576. doi: 10.1111/j.1440-1746.2009.05991.x. PubMed PMID: 19744004.
5. Rhee SM, Park KJ, Ha YC. Hypertrophic osteoarthropathy in patient with Crohn's disease: A case report. *J Bone Metab.* 2014;21:151-4. doi: 10.11005/jbm.2014.21.2.151. PubMed PMID: 25025001; PubMed Central PMCID: PMC4075269.
6. Guyot-Drouot MH, Solau-Gervais E, Cortet B, Deprez X, Chastanet P, Cotten A, et al. Rheumatologic manifestations of pachydermoperiostosis and preliminary experience with bisphosphonates. *J Rheumatol.* 2000;27:2418-23. PubMed PMID: 11036839.
7. Kozak KR, Milne GL, Morrow JD, Cuiffo BP. Hypertrophic osteoarthropathy pathogenesis: A case highlighting the potential role for cyclo-oxygenase-2-derived prostaglandin E2. *Nat Clin Pract Rheumatol.* 2006;2:452-6; quiz following 6. doi: 10.1038/nclrheum0252. PubMed PMID: 16932737.

8. Zarur FP, d'Almeida LV, Novellino AB, Reis MF. The action of prostaglandins on ciliary hypertrichosis: A case report of pachydermoperiostosis. *Int J Trichology*. 2014;6:25-6. doi: 10.4103/0974-7753.136756. PubMed PMID: 25114451; PubMed Central PMCID: PMC4124691.
9. Atkinson S, Fox SB. Vascular endothelial growth factor (VEGF)-A and platelet-derived growth factor (PDGF) play a central role in the pathogenesis of digital clubbing. *J Pathol*. 2004;203:721-8. doi: 10.1002/path.1565. PubMed PMID: 15141388.
10. Supradeeptha C, Shandilya SM, Vikram Reddy K, Satyaprasad J. Pachydermoperiostosis - a case report of complete form and literature review. *J Clin Orthop Trauma*. 2014;5:27-32. doi: 10.1016/j.jcot.2014.02.003. PubMed PMID: 25983465; PubMed Central PMCID: PMC4009462.