

Limb Loss Caused by Thrombosis led to the Diagnosis of Ulcerative Colitis

Seyed Mohammad Vahid Hosseini¹,
Hamid Reza Foroutan¹, Babak Sabet¹,
Mohammad Nasibi¹,
Seyed Abbas Banani¹

Abstract

Arterial thrombosis associated with ulcerative colitis usually occurs in the postoperative period with a good response to anti-coagulant therapy and embolectomy. Our patient was a 14-year-old girl with ulcerative colitis who presented with bilateral pulseless extremities, which did not respond to medical treatment and embolectomy. Subsequent colectomy did not save her limbs. The repeated thrombosis caused gangrene of extremities in the below knee region leading to bilateral amputation. Thrombosis can be the first presentation of ulcerative colitis.

Iran J Med Sci 2010; 35(1): 69-71.

Keywords • Ulcerative colitis • palate • thrombosis • loss • diarrhea

Introduction

Thromboembolism associated with ulcerative colitis has been reported in 1.2-6.4% of such patients. Arterial thrombosis is a rare complication of ulcerative colitis, which occurs in aortoiliac, femoropopliteal, and digital arteries. It is more common in Crohn's disease than in ulcerative colitis. Thrombosis in arteries can usually be treated by thrombectomy, anticoagulation, and compartment fasciotomy in patients with limb ischemia.^{1,2}

Arterial thrombosis can occur as a postoperative complication and it has never been reported as the first presentation of ulcerative colitis associated with bilateral limb loss as we are to describe in this case report.

Case Report

A 14-year-old girl presented with pulseless lower extremities. She looked pale and ill. Her pulse rate was 110/min, blood pressure 100/70 mmHg, and temperature 37.4°C. Apart from her tender and cold extremities, her physical examination was normal. She had had headaches for one week and also a mild weight loss 3 months earlier. The patient had no history of abdominal pain and bloody diarrhea before admission. History of coagulopathy and drug consumption was negative. She received three units of packed red cells and her blood samples were taken to investigate possible causes of thrombosis and heparin infusion was started. Then she underwent bilateral femoral embolectomy by Fogarty catheter number 3.

Laboratory evaluation showed: white blood cell count: 13×10⁹ /L, hemoglobin: 6 g/L reticulocytes: 2%, erythrocyte sedimentation rate: 80 mm/hr prothrombin time (PT): 11 seconds (control=11.5), activated partial thromboplastin time (APTT): 32 seconds (control 26-38), free protein S activity: <14% (normal: 70-140%), protein C: 130% (normal: 70-140%),

¹Department of Pediatric Surgery,
Shiraz University of Medical Sciences,
Shiraz, Iran.

Correspondence:

Seyed Mohammad Vahid Hosseini MD,
Department of Pediatric Surgery,
Shiraz University of Medical Sciences,
Shiraz, Iran.

Tel: +98 711 6263041

Fax: +98 711 6239105

Email: psrg.sums @yahoo.com

Received: 2 March 2009

Revised: 23 July 2009

Accepted: 13 August 2009

fibrinogen: 4.8 g/L (normal: 2-4), antithrombin III: 80% (normal: 70-150), and both anticardiolipin and lupus anticoagulant antibodies were negative.

Despite repeated embolectomy, thrombosis in arteries of the limbs persisted, which was confirmed by examination of distal pulses, viability of lower limbs, and color doppler sonography.

The patient was evaluated for postoperative bloody diarrhea by colonoscopy and the diagnosis of ulcerative colitis was made by colonic biopsy (figure 1). She received prednisolone (40 mg daily) and sulfasalazine (1 g twice daily) in addition to heparin. Color doppler sonography showed wide-spread thrombosis in common and superficial femoral arteries. She underwent a total colectomy and ileostomy, which resulted in cessation of thrombosis. However, the recurrent thrombosis caused gangrene of extremities in the below knee region leading to bilateral amputation (figures 2,3).

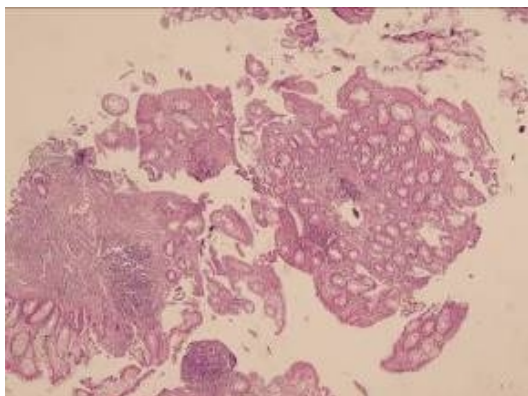


Figure 1: Pathologic findings of ulcerative colitis in resected colon shows neutrophil infiltration of submucosa and crypt abscess (H&E staining $\times 100$)

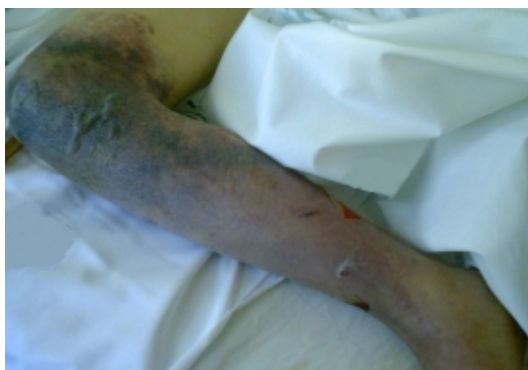

Figure 2: Irreversible ischemia of right limb.

Discussion

Increased coagulability is a rare but well-recognized feature that complicates inflammatory bowel disease. Thrombotic complications are usually the result of pro-coagulant changes

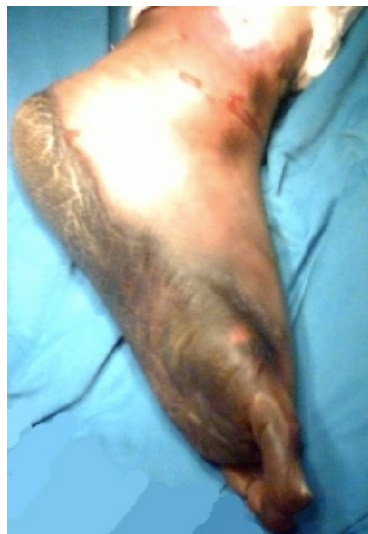

Figure 3: Irreversible ischemia of left limb.

in such patients. However, good clinical improvement can be achieved after treatment with steroids, sulfasalazine, anticoagulation with enoxaparin, and thrombectomy followed by long-term warfarin administration.¹⁻³ Our patient had not only responded to embolectomy and medical treatment but also presented with arterial thrombosis as the first clinical manifestation, which made a lot of confusion in her management. Jackson and co-workers reported 52 patients with ulcerative colitis and thrombosis. Of them, five had thrombotic episodes involving two different sites and three had three different thrombotic events.⁴ Their patients developed recurrent episodes of thrombosis in the same site leading to amputation.

Thrombotic events occurred in young adults with active disease.⁴ Our patient developed thrombotic event as the first presentation of the disease. We administered anticoagulant drugs and performed embolectomy to restore the limbs perfusion with adding sulfasalazine and steroid for cessation of recurrent thrombosis. Finally, the patient underwent a total colectomy for saving her limbs. In some studies, in sudden and refractory thrombosis of the arteries, resection of large bowel in addition to drug therapy with azathioprine has been shown to be effective in patients with warfarin resistance.⁵⁻⁷

Restorative proctocolectomy with ileal pouch-anal anastomosis (IPAA) is the surgical treatment for ulcerative colitis. However, in acute phase subtotal colectomy suffices. In many reports, intravenous cyclosporine (4 mg/kg per day) or oral micro-emulsion cyclosporine or tacrolimus have been used as alternatives to colectomy.⁶⁻¹¹

Conclusion

Ulcerative colitis can be presented with arterial thrombosis as the first sign and may cause limb loss.

Acknowledgment

Many thanks for the help and cooperation of prof. Bitá Geramizadeh in the pathologic evaluation of the samples.

Conflict of Interest: None declared

References

- 1 J. Arnold Barger, Nelson W. Barker. Extensive Arterial And Venous Thrombosis Complicating Chronic Ulcerative Colitis. *Arch Intern Med* 1936; 58: 17-31.
- 2 Graef V, Baggenstoss AH, Sauro WG. Venous thrombosis occurring in nonspecific ulcerative colitis. A necropsy study. *Arch Intern Med* 1966; 117: 377-82.
- 3 Nogami H, Iai T, Maruyama S, et al. Common carotid arterial thrombosis associated with ulcerative colitis. *World J Gastroenterol* 2007; 21;13: 1755-7.
- 4 Jackson LM, O'Gorman PJ, O'Connell J, et al. Thrombosis in inflammatory bowel disease: clinical setting, procoagulant profile and factor V Leiden. *QJM* 1997; 90: 183-8.
- 5 Mikroulis DA, Antypas GD, Fournogerakis SD, et al. Arterial Thrombosis in Ulcerative Colitis: Case Report. *Int J Angiol* 1999; 8: 62-4.
- 6 Pogliani EM, Bozzani A, Radaeli F, et al. Thrombolytic therapy for venous thrombosis in patients with gastro-intestinal diseases. *Pharmatherapeutica* 1982; 3: 268-73.
- 7 Teefy AM, Martin JE, Kovacs MJ. Warfarin resistance due to sulfasalazine. *Ann Pharmacother* 2000; 34: 1265-8.
- 8 Lichtiger S, Present DH, Kornbluth A, et al. Cyclosporine in severe ulcerative colitis refractory to steroid therapy. *N Engl J Med* 1994; 30;330: 1841-5.
- 9 Treem WR, Davis PM, Hyams JS. Cyclosporine treatment of severe ulcerative colitis in children. *J Pediatr* 1991; 119: 994-7.
- 10 Navazo L, Salata H, Morales S, et al. Oral microemulsion cyclosporine in the treatment of steroid-refractory attacks of ulcerative and indeterminate colitis. *Scand J Gastroenterol* 2001; 36: 610-4.
- 11 Bousvaros A, Kirschner BS, Werlin SL, et al. Oral tacrolimus treatment of severe colitis in children. *J Pediatr* 2000; 137: 794-9.