



# Successful Management of Cervical and Tubal Stump Double Pregnancy after Assisted Reproductive Technologies Using Multiple High Doses of Methotrexate: A Case Report

Andrey Gaiday<sup>1</sup>, PhD;  Akylbek Tussupkaliyev<sup>1</sup>, PhD; Abay Nurken<sup>2</sup>, MD; Assel Gaiday<sup>2</sup>, MD; Ainur Primbetova<sup>2</sup>, MD; Moldir Dossimbetova<sup>1</sup>, MD; Assemgul Yeszhanova<sup>2</sup>, MD; Bibigul Karimsakova<sup>3</sup>, PhD; Nurgul Ablakimova<sup>4,5</sup>, PhD candidate 

<sup>1</sup>Department of Obstetrics and Gynecology, West Kazakhstan Marat Ospanov Medical University, Aktobe, Kazakhstan;

<sup>2</sup>Department of Gynecology, Regional Perinatal Center, Aktobe, Kazakhstan;

<sup>3</sup>Department of General Medical Practice, West Kazakhstan Marat Ospanov Medical University, Aktobe, Kazakhstan;

<sup>4</sup>Department of Pharmacology, West Kazakhstan Marat Ospanov Medical University, Aktobe, Kazakhstan;

<sup>5</sup>Department of Hospital Pharmacy, Regional Perinatal Center, Aktobe, Kazakhstan

## Correspondence:

Nurgul Ablakimova, PhD candidate;  
68, Maresyev St., Postal code: 030000,  
Aktobe, Kazakhstan

Tel: +7 70 74753485

Email: n.ablakimova@zkm.kz

Received: 21 March 2024

Revised: 20 May 2024

Accepted: 25 May 2024

## What's Known

- Ectopic pregnancy (EP) is a common obstetric emergency that frequently occurs in the fallopian tubes.
- Its occurrence is rising as a result of pelvic inflammatory diseases and assisted reproductive technologies.
- Methotrexate has been established as a conservative treatment option for EP, particularly in hemodynamically stable patients, aiming to preserve fertility while avoiding surgical intervention.

## What's New

- The successful management of a rare double ectopic pregnancy involving both cervical and tubal stump locations following assisted reproductive technologies (ART), which included multiple high doses of methotrexate (MTX), highlighted the efficacy of conservative treatment approaches in preserving fertility and avoiding surgical intervention in complex ectopic pregnancies.

## Abstract

The incidence of ectopic pregnancy (EP) has increased in recent years, owing to causes such as pelvic inflammatory diseases and assisted reproductive technologies (ART). The present study reported a case of a 33-year-old nulliparous woman with a history of previous ectopic pregnancies, who underwent pelvic ultrasound in August 2022, which revealed a double EP including a cervical pregnancy and a tubal stump pregnancy. Despite known risk factors and elevated beta-human chorionic gonadotropin ( $\beta$ -hCG) levels, a conservative approach, utilizing multiple doses of systemic methotrexate (MTX) injections, was employed to preserve fertility at the Regional Perinatal Center in Aktobe, Kazakhstan. Treatment efficacy was monitored through  $\beta$ -hCG levels and ultrasound imaging, with successful resolution of both EPs and preservation of reproductive function. The present case highlighted the safety and efficacy of MTX therapy in managing complex EP presentations, emphasizing the necessity of individualized treatment approaches in reproductive medicine, particularly in terms of preserving fertility in patients undergoing ART. Multiple high doses of MTX injections were beneficial for pregnancy with two distinct regions, fetal cardiac activity, and elevated serum  $\beta$ -hCG level. Further research is required to explore optimal treatment strategies for EP, considering patient-specific factors and treatment goals.

Please cite this article as: Gaiday A, Tussupkaliyev A, Nurken A, Gaiday A, Primbetova A, Dossimbetova M, Yeszhanova A, Karimsakova B, Ablakimova N. Successful Management of Cervical and Tubal Stump Double Pregnancy after Assisted Reproductive Technologies Using Multiple High Doses of Methotrexate: A Case Report. Iran J Med Sci. 2024;49(7):461-466. doi: 10.30476/IJMS.2024.102119.3487.

**Keywords** • Pregnancy, ectopic • Methotrexate • Reproductive techniques, assisted

## Introduction

An ectopic pregnancy (EP) develops when a growing embryo implants outside of the endometrial cavity.<sup>1</sup> Ectopic pregnancy ruptures are the leading cause of maternal mortality in the first trimester, accounting for 9%-14% of these deaths and 5%-10% of all pregnancy-related fatalities.<sup>1</sup> Risk factors for ectopic pregnancy included a history of prior EP, fallopian tube damage, previous pelvic or fallopian tube surgery, complications from ascending pelvic infections, infertility, smoking, age over 35, pelvic inflammatory disease, endometriosis, abnormal reproductive system anatomy, pregnancy occurring with an intrauterine device in place, or

the use of assisted reproductive technology (ART).<sup>2</sup> Specific risk factors associated with ART included transferring a higher number of embryos, using fresh embryos instead of cryo-thawed ones, and choosing cleavage-stage transfers instead of blastocyst transfers.<sup>3</sup> Heterotopic EPs are highly complex, and their incidence is increasing due to an association with ART. They frequently occurred in one out of 100 pregnancies with *in vitro* fertilization (IVF) and in one out of 7,000 pregnancies with ART, which involved ovulation induction.<sup>4</sup> The rate of EP among IVF pregnancies ranged from 2.1% to 8.6% following embryo transfer, compared to 2% in natural conceptions.<sup>5</sup>

When women are in a clinically stable condition, systemic and local methotrexate (MTX) injections, a viable treatment option, should be considered.<sup>6</sup> Strategic management approaches are particularly essential in the context of ART, as patients frequently express a strong desire for future fertility.<sup>7</sup>

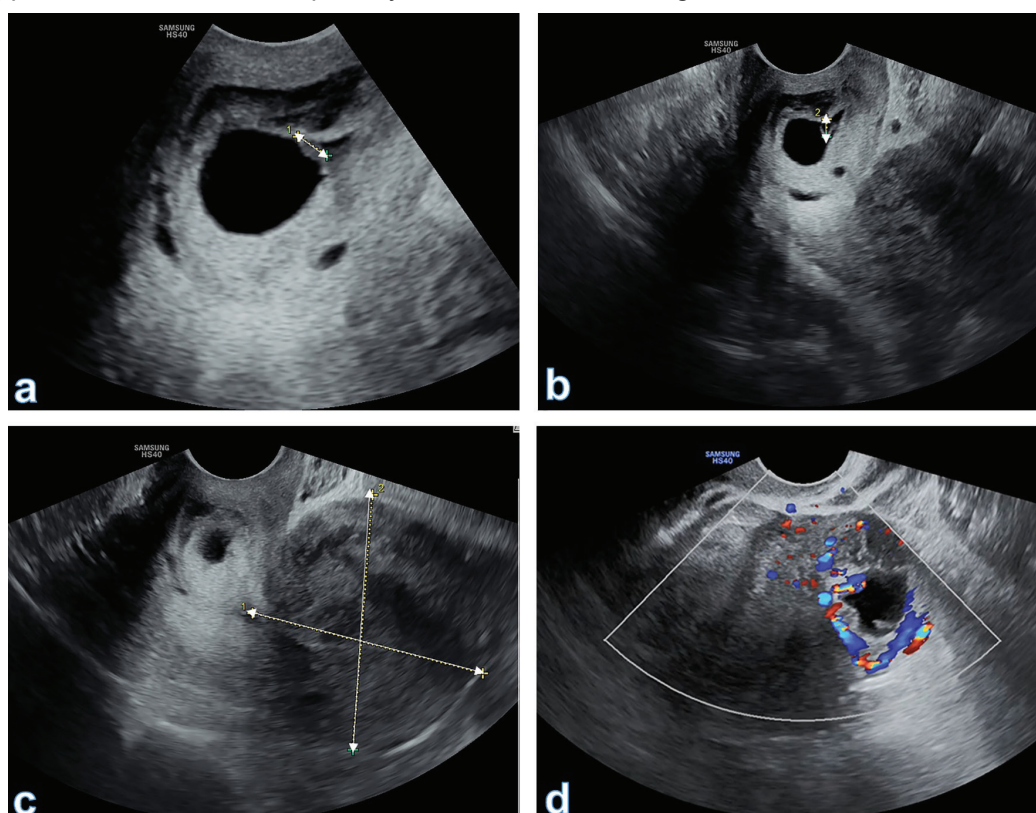
MTX is used to treat early ectopic EP and various gynecological neoplasms. Treatment plans encompass both single and multiple doses. The initial preferred protocol involves a single intramuscular injection of MTX, at a suggested dosage of 1 mg/Kg or 50 mg/m<sup>2</sup>. This approach is considered the primary course

of action.<sup>6</sup> When serum beta-human chorionic gonadotropin ( $\beta$ -hCG) levels are below 2,000 mIU/mL, the diagnosis has an effectiveness of above 90%.<sup>8</sup>

To the best of our knowledge, there were no cases in the literature of utilizing MTX for double ectopic pregnancy after IVF. Herein, we presented a case of a rare double EP following ART that was successfully treated with MTX at the Regional Perinatal Center in Aktobe, Kazakhstan. This case was prepared in line with SCARE guideline.<sup>9</sup>

### Case Presentation

A 33-year-old, pregnant Asian woman underwent a pelvic ultrasound 21 days after embryo transfer. The examination revealed a 6-week cervical pregnancy and a tubal stump pregnancy, leading to her admission to the reception ward of the Regional Perinatal Center in Aktobe, Kazakhstan in August 2022. In 2017, the woman underwent a right-sided salpingectomy due to an ectopic pregnancy, followed by a left-sided salpingectomy in 2020 for the same reason. In 2018, she underwent hysteroscopy and polypectomy. In 2021, her IVF attempt was unsuccessful, which resulted in a miscarriage in the 7<sup>th</sup> week.



**Figure 1:** The transvaginal ultrasound images revealed a double pregnancy involving the tubal stump and cervical canal. a: Embryo in the cervical canal; b: Measuring the yolk sac; c: Empty uterine cavity; d: Fetal egg in the left tubal stump with pronounced peripheral blood flow.

The woman had no extragenital pathology. At the time of examination, her general health condition was satisfactory. She complained of a pulling pain in her lower abdomen. Her blood pressure was 110/70 mmHg, the pulse rate was 81 bpm, the oxygen saturation was 98%, and the body temperature was 36.2 °C.

The pelvic ultrasound was done using Samsung HS-40 (Samsung Medison, South Korea), and the results were as follows: The uterus was in the midline position with a forward tilt, exhibiting clear and smooth contours and a homogeneous structure. A hypoechoic rounded formation measuring 30×28 mm with cystic content and a diameter of 15 mm was observed on the left margin of the uterus. The embryo and yolk sac were not distinctly located. The uterine cavity was not deformed. In the cervical canal, a gestational sac with a mean sac diameter (MSD) of 11 mm, containing a viable embryo with a crown-rump length (CRL) of 3.2 mm, a positive heartbeat, as well as a yolk sac of 4 mm, were identified. There was a significant blood flow (2 vessels on the anterior and posterior walls). No free fluid was

observed behind the uterus (figure 1).

During the vaginal examination, smearing bloody discharges were noted. On the day of hospitalization, the patient's β-hCG level was 30.000 mIU/mL, and the hematocrit level was 35% (table 1). The table shows the dynamics of parameters from the complete blood count, coagulogram, and biochemical blood analysis.

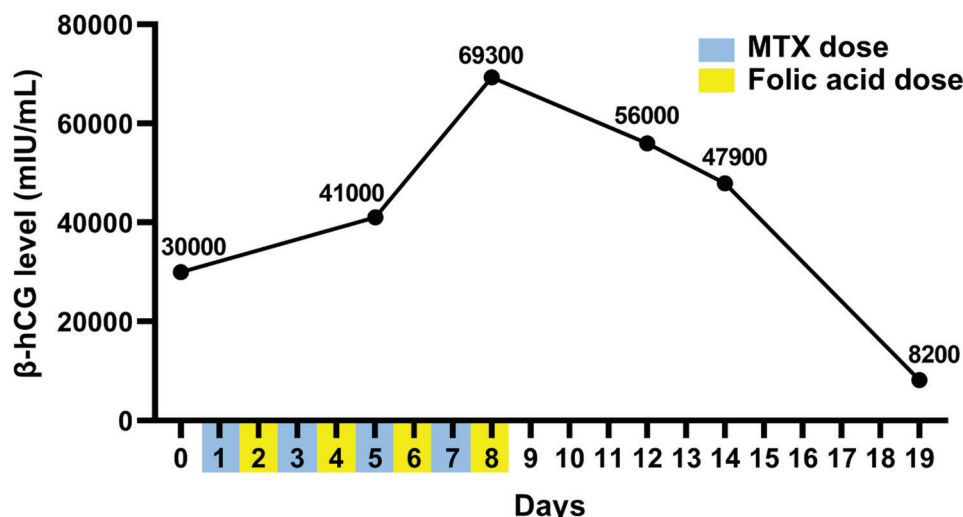
The patient and her husband discussed treatment options, potential risks, and the severity of the condition. Given the patient's nulliparous status and her desire to maintain fertility, the medical team recommended a conservative treatment approach involving transvaginal ultrasound-guided systemic methotrexate injections.

Methotrexate-Ebewe (MTX, Sandoz Co., Germany) was prescribed at a dose of 1 mg/Kg, with a total dose of 90 mg intramuscularly (day 1), followed by the administration of oral folic acid (Marbiofarm Co., Russia) at a dose of 0.1 mg/Kg (day 2). MTX was administered on days 3, 5, and 7, with alternating doses of folic acid. On the fourth day, a follow-up ultrasound revealed that there was no fetal heartbeat. However, the

**Table 1:** The patient's complete blood count, Coagulogram, and biochemical blood analysis results during hospitalization

Parameters		Day 0	Day 7	Day 9	Day 10	Day 11	Day 12	Day 19
Complete Blood Count	Color index	0.9	0.9	0.9	0.9	0.9	0.9	0.9
	Monocytes (MON%)	3	4	3	2	2	2	8
	Eosinophils (EO%)	3	2	2	2	1	3	3
	Lymphocytes (LYM%)	13	29	26	31	24	21	32
	Neutrophils (NEUT%)	81	65	69	63	73	74	57
	Hematocrit (HCT)	36	35	29	30	28	30	31
	Platelets (PLT)	309/μL	379/μL	231/μL	238/μL	256/μL	228/μL	415/μL
	Red blood cells (RBC)	3.9/μL	3.4/μL	3.1/μL	3.1/μL	3.1/μL	3.2/μL	3.3/μL
	White blood cells (WBC)	13.3/μL	7.4/μL	7.8/μL	12.3/μL	11.1/μL	8.8/μL	7.2/μL
Coagulogram	Hemoglobin (HGB)	113 g/L	111 g/L	94 g/L	93 g/L	93 g/L	97 g/L	101g/L
	International Normalized Ratio (INR)	1.3	1.07	1.32	1.18	ND	1.1	1.18
	Prothrombin Time Index (PTI), %	67.6	98	67	81.3	ND	88.2	81.3
	Prothrombin Time (PT), sec	15.8	13.5	15.9	14.4	ND	13.7	14.4
	Thrombin Time (TT), sec	13.8	13.5	25.1	27.6	ND	14.2	12.8
	Activated Partial Thromboplastin Time (APTT), sec	27.6	26	28.7	27.8	ND	28	25.7
Biochemical Blood Analysis	Fibrinogen, g/L	4.3	3.9	3.6	2.9	ND	3	2.8
	Alanine Aminotransferase (ALT), U/L	33	33	52.3	42	37	27	18
	Aspartate Aminotransferase (AST), U/L	22	22	26	21	17	18	12
	Total Protein, g/L	79	74	68	61	72	68	65
	Urea, mmol/L	6.8	5.2	4.8	5.7	4.1	4	5.9
	Direct Bilirubin, μmol/L	1.2	9.8	2.7	1.2	1.2	2.6	3.7
	Total Bilirubin, μmol/L	3.8	21.8	6.7	14	6.4	8	12.7
	Total α-Amylase, U/L	91	75	29	49	52	40	58
	Glucose, mmol/L	6.2	7.6	3.7	6	4.1	4.2	4.9
	Creatinine, μmol/L	101	80	60	80	77	60	53
	C-Reactive Protein (CRP), mg/L	ND	6.5	6.6	6.5	ND	ND	5
	Alkaline Phosphatase (ALP), U/L	ND	160	207	200	ND	ND	99
	Magnesium (Mg), mmol/L	ND	0.7	0.88	0.82	ND	ND	0.85
	Potassium (K), mmol/L	ND	4.5	4.8	3.9	ND	ND	3.9
Chlorides (Cl), mmol/L	ND	98	100	100	ND	ND	102	
Sodium (Na), mmol/L	ND	140	139	137	ND	ND	138	

ND: No Data



**Figure 2:** The treatment was associated with a decline in the level of β-hCG.

level of β-hCG increased to 41.000 mIU/mL and continued to rise until the administration of the final dose of MTX. The woman was monitored until the decrease of β-hCG to 8200 mIU/mL. She was hospitalized for a total of 20 days (figure 2). She was discharged with recommendations and instructed to check her serum β-hCG level weekly. The pregnancy ended with the loss of both fetuses. After two months of follow-up, there were no pathological findings in the uterine cavity or cervical canal as determined by control hysteroscopy data.

Written informed consent was obtained from the patient to publish this case report and any accompanying images.

## Discussion

In the past few years, the occurrence of ectopic pregnancy has risen due to a higher frequency of pelvic inflammatory diseases and the expanded utilization of assisted reproductive technologies.<sup>3, 10</sup> Several factors are associated with EP after ART, necessitating a simultaneous examination of all these factors. However, there was scarcity of studies employing multivariate analysis with substantial sample sizes to investigate the combined impact of multiple factors on EP.

While traditional salpingectomy is a reliable treatment method for ectopic pregnancy, it comes with the drawback of losing the fallopian tubes and the inherent risks associated with surgery. Advances in diagnostic technology now allow for the early detection of most ectopic pregnancies, enabling the use of conservative treatment options.<sup>10</sup> Opting for medical management not only preserves the fallopian tubes but also mitigates the risks of

pain and the high costs of surgical procedures. MTX has been extensively validated and is widely employed for the conservative treatment of ectopic pregnancy.<sup>11</sup> However, the treatment protocol recommended specific cutoff values for the initial β-hCG level and the size of the adnexal mass. However, the question of whether surgery can be avoided through conservative treatment for certain hemodynamically stable patients who want to avoid surgery but do not meet the aforementioned criteria, remains unanswered.

Factors indicative of MTX treatment ineffectiveness included an elevated initial serum βhCG level (>5,000 mIU/mL), a gestational mass volume (≥3.5 cm),<sup>12</sup> the existence of fetal cardiac activity or free peritoneal blood in the adnexa, and a rapid increase in βhCG (>50%/48 h) before the initiation of MTX treatment.<sup>8</sup> Despite the presence of these factors in the present case, the treatment procedure was found to be successful. However, when the pretreatment βhCG level exceeded 5000 mIU/mL, the likelihood of MTX therapy failure increased to 14.3% or higher, in contrast to a 3.7% failure rate with β-hCG levels below 5000 mIU/mL.<sup>13</sup>

In this case, due to diligent monitoring, despite its unusual locations, the EP was diagnosed early. Furthermore, the patient had known risk factors for EP, such as a history of ART, salpingectomy, hysteroscopy, and polypectomy. Individuals undergoing ART frequently receive extensive prospective monitoring, allowing for early detection and timely intervention in cases of abnormal pregnancies. Detecting EP after the 10<sup>th</sup> week of gestation poses an increased risk of hemorrhage, hypovolemic shock, and the potential necessity for an emergency hysterectomy.<sup>14</sup>

Even a little dose of MTX might have side

effects. The most prevalent adverse reactions involved gastrointestinal symptoms, such as nausea, vomiting, mucosal ulcers, and anorexia, which were observed in the majority of patients and were easily controlled.<sup>15</sup> These side effects bear resemblance to folate deficiency and can be mitigated by supplementing methotrexate with folic acid.<sup>15</sup> Additional potential life-threatening side effects included alopecia, fatigue, fever, an increased risk of infection, low white cell count, gastrointestinal bleeding, pancreatitis, bone marrow suppression, malignancies, infections, and renal failure.<sup>15</sup> Despite receiving high doses of MTX, our patient did not have the aforementioned complaints. Nonetheless, laboratory tests indicated a slight increase in alanine aminotransferase levels to 52.3 on days 9-10.

In the context of fertility treatment, it is crucial to investigate noninvasive interventions for fertility preservation. Although there was no unanimous consensus on the optimal treatment, this case underscored the safety and efficacy of an intramuscular administration of MTX. This marked the first instance of a successful resolution of double EP, located in the cervical canal and stump at the site of tubectomy, using multiple methotrexate doses in a patient undergoing ART.

However, it should be noted that the present study was limited by the lack of access to post-discharge follow-up data provided by inpatient setting physicians, which could have provided useful insights into the long-term outcomes.

## Conclusion

Multiple high doses of MTX injections could be effective for cases where the pregnancy was located in two distinct areas, with fetal cardiac activity and elevated serum  $\beta$ -hCG level.

## Authors' Contribution

A.G: Study concept, Study design, and drafting; A.T: Study concept; Supervision, drafting, and reviewing; A.N: Study design, data gathering, drafting, and reviewing; A.G: Data gathering, data interpretation, drafting, and reviewing, A.P: Data gathering; drafting, and reviewing; M.D: Study design, data analysis, drafting, and reviewing; A.Y: Data gathering, data interpretation, drafting, and reviewing; B.K: Study design, data interpretation, drafting, and reviewing; A.N: Study concept, Study design, data gathering, drafting, and reviewing; All authors have read and approved the final manuscript and agree to be accountable for all aspects of the work in

ensuring that questions related to the accuracy or integrity of any part of the work are appropriately investigated and resolved.

**Conflict of Interest:** None declared.

## References

- 1 Tonick S, Conageski C. Ectopic Pregnancy. *Obstet Gynecol Clin North Am.* 2022;49:537-49. doi: 10.1016/j.ogc.2022.02.018. PubMed PMID: 36122984.
- 2 Mullany K, Minneci M, Monjazeb R, O CC. Overview of ectopic pregnancy diagnosis, management, and innovation. *Womens Health (Lond).* 2023;19:17455057231160349. doi: 10.1177/17455057231160349. PubMed PMID: 36999281; PubMed Central PMCID: PMCPMC10071153.
- 3 Brady PC. New Evidence to Guide Ectopic Pregnancy Diagnosis and Management. *Obstet Gynecol Surv.* 2017;72:618-25. doi: 10.1097/OGX.0000000000000492. PubMed PMID: 29059454.
- 4 Houser M, Kandalaf N, Khati NJ. Ectopic pregnancy: a resident's guide to imaging findings and diagnostic pitfalls. *Emerg Radiol.* 2022;29:161-72. doi: 10.1007/s10140-021-01974-7. PubMed PMID: 34618256.
- 5 Cheng LY, Lin PY, Huang FJ, Kung FT, Chiang HJ, Lin YJ, et al. Ectopic pregnancy following in vitro fertilization with embryo transfer: A single-center experience during 15 years. *Taiwan J Obstet Gynecol.* 2015;54:541-5. doi: 10.1016/j.tjog.2015.08.004. PubMed PMID: 26522107.
- 6 Zikopoulos A, Loukopoulos T, Galani A, Kechagias K, Skentou C, Zikopoulos K, et al. Methotrexate treatment of very high beta-HCG ectopic pregnancy on previous cesarean scar: A case report. *Radiol Case Rep.* 2023;18:4106-9. doi: 10.1016/j.radcr.2023.08.051. PubMed PMID: 37720917; PubMed Central PMCID: PMCPMC10504459.
- 7 Dilday E, Douglas C, Brennan K. Single-dose intramuscular methotrexate for treatment of cervical ectopic pregnancy: A case report. *Case Rep Womens Health.* 2021;31:e00340. doi: 10.1016/j.crwh.2021.e00340. PubMed PMID: 34336601; PubMed Central PMCID: PMCPMC8313574.
- 8 Naveed AK, Anjum MU, Hassan A, Mahmood SN. Methotrexate versus expectant management in ectopic pregnancy: a meta-analysis. *Arch Gynecol Obstet.* 2022;305:547-53. doi: 10.1007/s00404-021-06236-y. PubMed PMID: 34524502.

- 9 Agha RA, Franchi T, Sohrabi C, Mathew G, Kerwan A, Group S. The SCARE 2020 Guideline: Updating Consensus Surgical CAse REport (SCARE) Guidelines. *Int J Surg.* 2020;84:226-30. doi: 10.1016/j.ijvsu.2020.10.034. PubMed PMID: 33181358.
- 10 American College of O, Gynecologists' Committee on Practice B-G. ACOG Practice Bulletin No. 193: Tubal Ectopic Pregnancy. *Obstet Gynecol.* 2018;131:e91-e103. doi: 10.1097/AOG.0000000000002560. PubMed PMID: 29470343.
- 11 Stabile G, Romano F, Buonomo F, Zinicola G, Ricci G. Conservative Treatment of Interstitial Ectopic Pregnancy with the Combination of Mifepristone and Methotrexate: Our Experience and Review of the Literature. *Biomed Res Int.* 2020;2020:8703496. doi: 10.1155/2020/8703496. PubMed PMID: 32802882; PubMed Central PMCID: PMC67421079.
- 12 Alfiya R, Sabu ST, Dharan SS. A detailed study of methotrexate treatment in ectopic pregnancy. *Int J Res Hosp Clin Pharm.* 2020;2:85-92. doi: 10.33974/ijrhcp.v2i4.252.
- 13 Vrees RA, Frishman GN. Nontubal Ectopic Pregnancy. In: Keder L, Olsen ME, editors. *Gynecologic Care.* Cambridge: Cambridge University; 2018. p. 162-74. doi: 10.1017/9781108178594.018.
- 14 Drezett J, Marques D, Ottoboni R, Dzik A, Cavagna M. Cervical ectopic pregnancy after in vitro fertilization: case report successfully treated with cervical electric aspiration. *JBRA Assist Reprod.* 2019;23:434-8. doi: 10.5935/1518-0557.20190036. PubMed PMID: 31251012; PubMed Central PMCID: PMC6798596.
- 15 Onda K, Honma T, Masuyama K. Methotrexate-related adverse events and impact of concomitant treatment with folic acid and tumor necrosis factor-alpha inhibitors: An assessment using the FDA adverse event reporting system. *Front Pharmacol.* 2023;14:1030832. doi: 10.3389/fphar.2023.1030832. PubMed PMID: 36909171; PubMed Central PMCID: PMC67992735.