




Quadruplet Heterotopic Pregnancy Following *In Vitro* Fertilization and Embryo Transfer with Laparotomic Removal of Ruptured Twin Tubal Ectopic Pregnancy: A Case Report

Mehran Anjomrooz¹, MD;  Maryam Farid Mojtahedi², MD;  Mahboubeh Abedi³, MD 

¹Department of Radiology, Shariati Hospital, Tehran University of Medical Sciences, Tehran, Iran;

²Department of Obstetrics and Gynecology, Endocrinology and Female Infertility Unit, Arash Women's Hospital, Tehran University of Medical Sciences, Tehran, Iran;

³Department of Radiology, Arash Women's Hospital, Tehran University of Medical Sciences, Tehran, Iran

Correspondence:

Maryam Farid Mojtahedi, MD;

Email: m_fmjtahedi@tums.ac.ir

Mahboubeh Abedi, MD;

Email: m-abedi@tums.ac.ir

No. 98, Arash Women's Hospital, Baghdarnia St., Resalat Hwy., Tehranpars, Postal code: 16539-15981, Tehran, Iran

Tel: +98 21 77883195

Fax: +98 21 77883196

Received: 27 February 2022

Revised: 01 June 2022

Accepted: 27 June 2022

Abstract

Heterotopic pregnancy (HP) is a rare occurrence in natural pregnancies. However, it can be a life-threatening condition and should be taken into account in all assisted reproductive treatments. Diagnosis and treatment of ectopic pregnancy are challenging issues in patients with HP. Here, we report a rare case of quadruplet HP following an *in vitro* fertilization-embryo transfer with a viable twin intrauterine pregnancy and ruptured live twin left tubal ectopic pregnancy. A 35-year-old woman (gravida 5, para 1, ectopic pregnancies 2, and abortion 1) was presented to the Emergency Department of Arash Women's Hospital (Tehran, Iran) in March 2021 with abdominal pain. The patient was at six weeks and five days of pregnancy following *in vitro* fertilization-embryo transfer. Transvaginal sonography (TVS) revealed a live twin intrauterine pregnancy with a ruptured live twin left tubal ectopic pregnancy. The latter was removed via laparotomy to preserve the intrauterine pregnancy. The patient subsequently delivered a female infant at 38 weeks of pregnancy.

Please cite this article as: Anjomrooz M, Farid Mojtahedi M, Abedi M. Quadruplet Heterotopic Pregnancy Following *In Vitro* Fertilization and Embryo Transfer with Laparotomic Removal of Ruptured Twin Tubal Ectopic Pregnancy: A Case Report. Iran J Med Sci. 2023;48(4):425-429. doi: 10.30476/IJMS.2022.94399.2574.

Keywords • Reproductive techniques • Assisted • Embryo transfer • Fertilization *in vitro* • Quadruplets

What's Known

- Heterotopic pregnancy (HP) is a recognized phenomenon in natural and assisted pregnancies. Surgical treatment is a safe option for tubal HP with a viable intrauterine pregnancy (IUP).
- Injection of potassium chloride into the heart of an ectopic fetus is another treatment option. Laparoscopic surgery may be a potential risk factor for abortion.

What's New

- To our knowledge, this is the first reported case of quadruplet HP (a twin intrauterine pregnancy plus a twin ectopic pregnancy) in Iran.
- Our findings will assist clinicians in the diagnosis and timely management of HP *in vitro* fertilization/intracytoplasmic sperm injection (IVF/ICSI) patients.

Introduction

Heterotopic pregnancy (HP) is a simultaneous intrauterine pregnancy (IUP) and ectopic pregnancy (EP). HPs occur naturally at an estimated rate of 1:4,000 to 1:300,000 pregnancies. In comparison, in pregnancies conceived by assisted reproductive technology (ART), the incidence is higher than 1:100.^{1, 2} The growing incidence of HP following an ART is a major concern, since the diagnosis and management of HP are highly complicated issues. In particular, the presence of an IUP may lead many physicians to neglect the coexisting EP,³ and laboratory tests for beta-human chorionic gonadotropin (β -HCG) levels are not sufficiently sensitive or specific to predict HP.^{3, 4}

We report a rare case of HP in a patient who became pregnant as a result of *in vitro* fertilization and embryo transfer (IVF-ET). To the best of our knowledge, this is the first report of quadruplet HP with viable twin IUP and ruptured live twin left tubal EP.

Case Presentation

The study was approved by the Ethics Committee of Tehran University of Medical Sciences, Tehran, Iran (code: IR.TUMS.MEDICINE.REC.1400.338). Written informed consent was obtained from the patient for publication of this case report and any accompanying images.

A 35-year-old woman (gravida 5, para 1, ectopic pregnancies 2, and abortion 1) was presented to the Emergency Department of Arash Women's Hospital (Tehran, Iran) in March 2021 at an estimated six weeks and five days of gestation, based on the time of embryo transfer. She complained of lower abdominal pain and vaginal spotting for a day prior to admission. Her obstetric and gynecologic history was notable. She had undergone right salpingectomy by laparotomy due to a right tubal EP following a prior IVF-ET procedure one year earlier. Three months before admission, due to ovulatory factor infertility, the patient underwent intracytoplasmic sperm injection (ICSI) treatment after being treated with a daily dose of 150 IU recombinant follicle-stimulating hormone (FSH) (Cinnal-f, CinnaGen, Iran) and 150 IU human menopausal gonadotropin (HMG) for 10 days. She further received gonadotropin-releasing hormone (GnRH) antagonist (Cetrotide 0.25 mg; Merck Serono, France) starting on day six of stimulation. The final oocyte maturation was triggered with 10,000 IU of human chorionic gonadotropin (HCG). After 36 hours, 21 oocytes were retrieved from her ovaries of which 20 were metaphase 2 (M2) oocytes. Nineteen oocytes were injected, and there were 10 embryos (blastocysts) including day four embryos (n=3) and day six embryos (n=6). All embryos

were frozen due to the high risk of ovarian hyperstimulation syndrome (OHSS). About two months later, the patient underwent a frozen embryo transfer cycle with a Letrozole+HMG regimen. There were two 19 mm follicles at cycle day 12, at which time 5,000 IU HCG was injected. Five days later, transvaginal embryo transfer of two three-day embryos (7AB and compA) into the patient's uterus was performed. At the time of her admission, the patient's physical examination showed abdominal tenderness. Besides, the patient was expected to become hemodynamically unstable. The patient's hemoglobin (Hb) and hematocrit (Hct) levels at the time of admission were 11 g/dL and 39%, respectively. These levels fell to 9/8 g/dL and 28% after four hours. Transvaginal ultrasonography revealed two intrauterine gestations with cardiac activity, each with its own gestational sac (figure 1). A left adnexal mass measuring approximately 47×32 mm was detected, which contained two ectopic gestations with cardiac activity in separate gestational sacs (figure 2). Furthermore, a substantial amount of intraperitoneal free fluid was noted. Ultrasonographic findings were characteristic of quadruplet HP with viable twin IUP coexisting with live twin left tubal EP.

The patient underwent an emergency laparotomy via a low transverse abdominal incision under spinal anesthesia. Left salpingectomy was performed, and a ruptured left fallopian tube measuring approximately 7×3.5 cm containing two embryos was removed. A histological assessment revealed the anticipated ruptured tubal EP containing twin embryos. On the first postoperative day, ultrasonography revealed live twin IUP with a

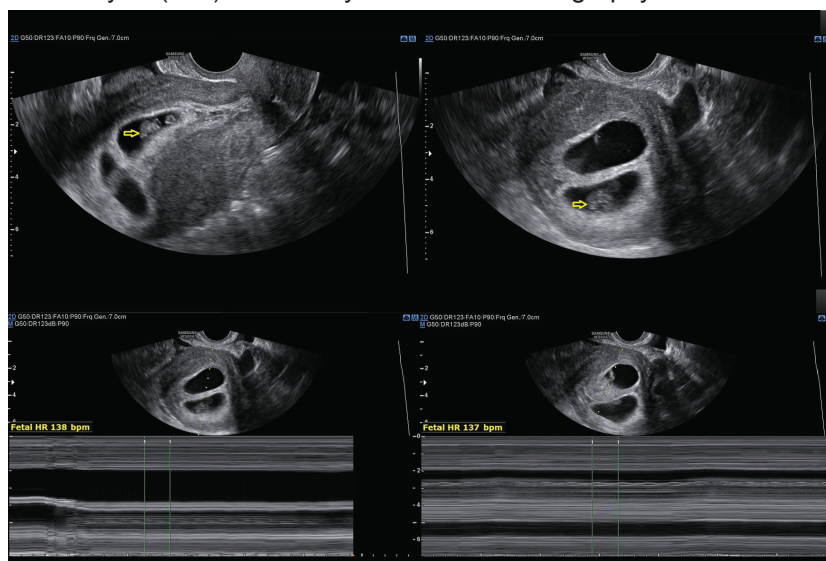


Figure 1: Transvaginal ultrasound showed live twin intrauterine pregnancies in separate gestational sacs. Yellow arrows show the two intrauterine fetal poles with cardiac activity.

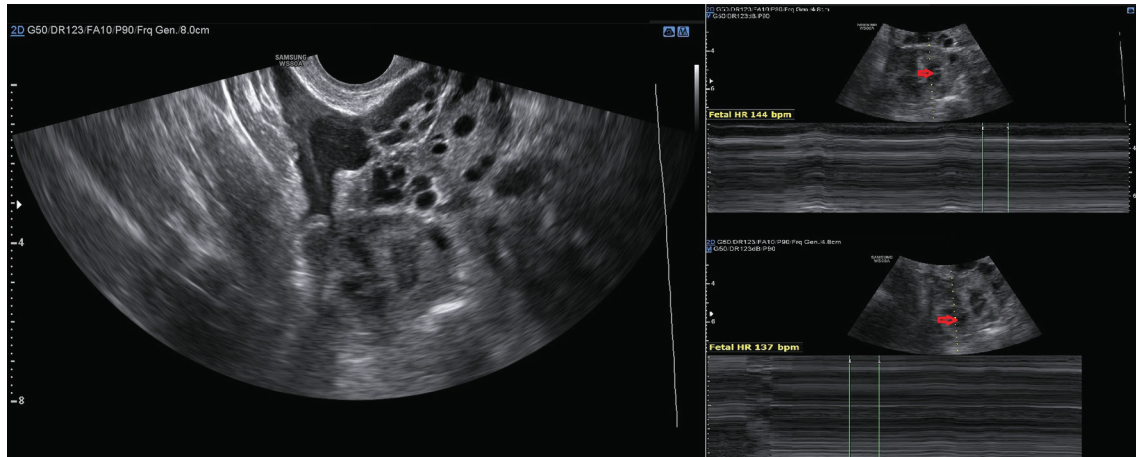


Figure 2: Transvaginal ultrasound showed left adnexal mass containing live twin ectopic pregnancies in separate gestational sacs. Red arrows show the two live fetuses within the mass of ectopic pregnancy.

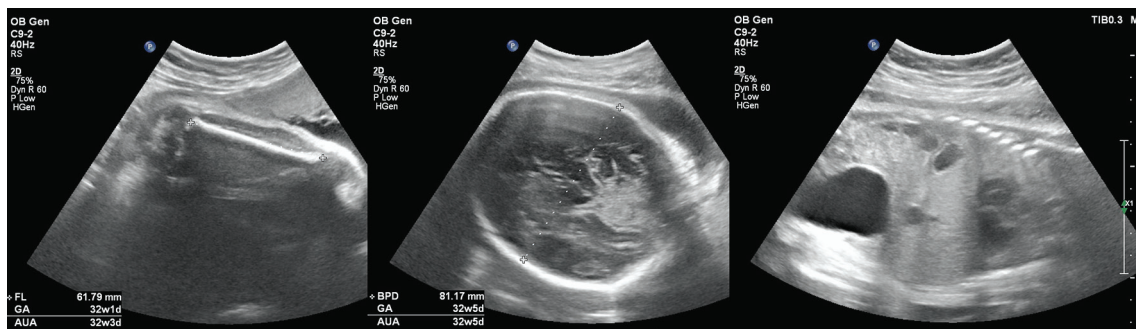

Figure 3: Transabdominal ultrasound in the third trimester showed a live fetus with normal growth.

crown-rump length of approximately 10 mm and 9 mm, which was compatible with a gestational age of 7±1 weeks. The patient had an uneventful postoperative period. During the first trimester, an ultrasound revealed one viable fetus with a crown-rump length of 44 mm compatible with the gestational age of 11 week and one day and a fetus with a gestational age of seven week and four day without any cardiac activity. The patient's pregnancy proceeded without any further complications, and the live fetus continued to grow naturally (figure 3). The patient delivered a healthy female infant weighing 3,150 grams with an APGAR score of 9 at 5- and 10-minute at 38 weeks of pregnancy.

Discussion

Tubal ectopic gestations can occur during natural conception or after IVF-ET. The literature shows that the main pathogenic mechanism acting as a predisposing factor for EP/HP (following either natural conception or IVF-ET) is a tubal malfunction, which leads to tubal implantation. Consequently, patients with underlying tubal damage are at a greater risk of EP/HP for both tubal damage and superovulation during the IVF-ET cycle.⁵ Our patient presented such risk

factors as her obstetric and gynecologic history revealed two tubal ectopic gestations and right salpingectomy following an episode of tubal EP. Due to several technical issues, some patients become predisposed to EP/HP following ART cycles.⁶ Refaat and colleagues reviewed IVF-ET technical issues and concluded that many of them are significant predisposing factors.⁵ These technical risk factors include altered endocrine milieu after controlled ovarian hyperstimulation, stage and day of embryo transfer, transfer media volume, multiple embryo transfer, and catheter position. Since there is a significant positive correlation between the number of transferred embryos and the risk of HP,⁵ the standard procedure in our hospital is to transfer one or two embryos in an IVF cycle to reduce the incidence of multiple implantations. In our patient, two embryos were transferred. However, as mentioned before, there were only two 19 mm follicles in our frozen cycle, and one of the probable causes of multiple gestations, in this case, could be due to natural conception. Our patient stated later that she had intercourse the day before the transfer. However, division of the embryos cannot be excluded either.

HP is a life-threatening condition that should be considered in all IVF-ET patients

irrespective of the presence or absence of predisposing pathology. HP diagnosis is mainly based on TVS and the physician's clinical suspicion. This is because the simultaneous existence of an EP with a live IUP can lead to a sufficient increase in β -hCG level, therefore, β -hCG measurement has little diagnostic value in HP.^{7, 8}

A retrospective analysis revealed that the sensitivity and specificity of TVS findings for HP diagnosis were 92.4% and 100%, respectively, with positive and negative predictive values of 100% and 99.9%.⁹ In our patient, identifying normal IUP with adnexal mass and intraperitoneal free fluid raised the clinical suspicion of HP. HP management techniques involve removing EP while preserving viable IUP. Surgical management, minimally invasive interventions for uncommon implantation sites of EP, and expectant management have all been assessed in various studies. The appropriate treatment depends on the clinical condition of the mother and fetus, gestational age at diagnosis, and the EP implantation site.¹⁰⁻¹² Surgery is an essential treatment modality for tubal HP with viable IUP. It could be an initial treatment or a second-line treatment when the first-line treatment has failed. Surgery could be performed by laparotomy in ruptured EP and hemodynamically unstable patients or by laparoscopy and EP removal by salpingectomy or salpingostomy. Several retrospective studies indicated a relatively low risk of adverse birth outcomes associated with surgical procedures during pregnancy. It was confirmed that surgery was a safe treatment modality for tubal HP with a live IUP.¹²⁻¹⁵ Considering the ruptured EP with extensive tubal damage in our patient, we chose to proceed with salpingectomy via laparotomy to preserve IUP. Compared with a singleton IUP achieved by ART, HP following ART is 30% less likely to end in a live birth. The risks of spontaneous and induced abortion in HP are two and ten times higher, respectively, than in intrauterine-only pregnancies.¹⁶ Future studies should compare pregnancy outcomes between different ectopic gestation sites and different treatment modalities.

The main finding of our study is that the occurrence of HP is extremely rare in natural pregnancies, and it is therefore highly unlikely that when an IUP is found in patients with positive β -hCG, an EP is simultaneously present. However, in patients who underwent ART, HP is not uncommon and careful ultrasound scanning of the adnexa and monitoring of β -hCG levels should be performed, even in asymptomatic cases.

Conclusion

Recently, the incidence of HP has increased in line with the increased use of ART. It is recommended to perform focused ultrasound scanning of the adnexa and monitor β -hCG levels in patients with IVF-ET even in the case of asymptomatic individuals. Future studies should be designed to develop pregnancy management protocols for uncommon implantation sites, while preserving viable IUP.

Authors' Contribution

M.A: Conception and design of the study, drafting; M.FM: Acquisition of data, critical revision; M.A: Conception and study design, data acquisition, and critical revision; All authors have read and approved the final manuscript and agree to be accountable for all aspects of the work in ensuring that questions related to the accuracy or integrity of any part of the work are appropriately investigated and resolved.

Conflict of Interest: None declared.

References

- Hewlett K, Howell CM. Heterotopic pregnancy: Simultaneous viable and nonviable pregnancies. *JAAPA*. 2020;33:35-8. doi: 10.1097/01.JAA.0000654012.56086.97. PubMed PMID: 32097214.
- Park HR, Moon MJ, Ahn EH, Baek MJ, Choi DH. Heterotopic quadruplet pregnancy: conservative management with ultrasonographically-guided KCl injection of cornual pregnancy and laparoscopic operation of tubal pregnancy. *Fetal Diagn Ther*. 2009;26:227-30. doi: 10.1159/000238109. PubMed PMID: 19752514.
- Talbot K, Simpson R, Price N, Jackson SR. Heterotopic pregnancy. *J Obstet Gynaecol*. 2011;31:7-12. doi: 10.3109/01443615.2010.522749. PubMed PMID: 21280985.
- Elson CJ, Salim R, Potdar N, Chetty M, Ross JA, Kirk EJ, et al. Diagnosis and Management of Ectopic Pregnancy: Green-top Guideline No. 21. *BJOG*. 2016;123:e15-e55. doi: 10.1111/1471-0528.14189. PubMed PMID: 27813249.
- Refaat B, Dalton E, Ledger WL. Ectopic pregnancy secondary to in vitro fertilisation-embryo transfer: pathogenic mechanisms and management strategies. *Reprod Biol Endocrinol*. 2015;13:30. doi: 10.1186/s12958-015-0025-0. PubMed PMID: 25884617; PubMed

- Central PMCID: PMC4403912.
- 6 Chang HJ, Suh CS. Ectopic pregnancy after assisted reproductive technology: what are the risk factors? *Curr Opin Obstet Gynecol.* 2010;22:202-7. doi: 10.1097/GCO.0b013e32833848fd. PubMed PMID: 20216415.
 - 7 Zhu L, Ren YY. The value of color Doppler ultrasonography in the diagnosis of heterotopic pregnancy (HP). *Fudan University Journal of Medical Sciences.* 2019;46:58-63.
 - 8 Lyu J, Ye H, Wang W, Lin Y, Sun W, Lei L, et al. Diagnosis and management of heterotopic pregnancy following embryo transfer: clinical analysis of 55 cases from a single institution. *Arch Gynecol Obstet.* 2017;296:85-92. doi: 10.1007/s00404-017-4384-y. PubMed PMID: 28540574.
 - 9 Li XH, Ouyang Y, Lu GX. Value of transvaginal sonography in diagnosing heterotopic pregnancy after in-vitro fertilization with embryo transfer. *Ultrasound Obstet Gynecol.* 2013;41:563-9. doi: 10.1002/uog.12341. PubMed PMID: 23610036.
 - 10 Yu Y, Xu W, Xie Z, Huang Q, Li S. Management and outcome of 25 heterotopic pregnancies in Zhejiang, China. *Eur J Obstet Gynecol Reprod Biol.* 2014;180:157-61. doi: 10.1016/j.ejogrb.2014.04.046. PubMed PMID: 25012396.
 - 11 Li JB, Kong LZ, Yang JB, Niu G, Fan L, Huang JZ, et al. Management of Heterotopic Pregnancy: Experience From 1 Tertiary Medical Center. *Medicine (Baltimore).* 2016;95:e2570. doi: 10.1097/MD.0000000000002570. PubMed PMID: 26844463; PubMed Central PMCID: PMC4748880.
 - 12 Li J, Luo X, Yang J, Chen S. Treatment of tubal heterotopic pregnancy with viable intrauterine pregnancy: Analysis of 81 cases from one tertiary care center. *Eur J Obstet Gynecol Reprod Biol.* 2020;252:56-61. doi: 10.1016/j.ejogrb.2020.06.005. PubMed PMID: 32563925.
 - 13 Shang J, Peng R, Zheng J, Lin M. The indicator of clinical outcomes for patients with heterotopic pregnancy following in-vitro fertilization with embryo transfer. *Taiwan J Obstet Gynecol.* 2019;58:827-32. doi: 10.1016/j.tjog.2019.09.018. PubMed PMID: 31759536.
 - 14 Lv S, Wang Z, Liu H, Peng J, Song J, Liu W, et al. Management strategies of heterotopic pregnancy following in vitro fertilization-embryo transfer. *Taiwan J Obstet Gynecol.* 2020;59:67-72. doi: 10.1016/j.tjog.2019.11.010. PubMed PMID: 32039803.
 - 15 Balinskaite V, Bottle A, Sodhi V, Rivers A, Bennett PR, Brett SJ, et al. The Risk of Adverse Pregnancy Outcomes Following Nonobstetric Surgery During Pregnancy: Estimates From a Retrospective Cohort Study of 6.5 Million Pregnancies. *Ann Surg.* 2017;266:260-6. doi: 10.1097/SLA.0000000000001976. PubMed PMID: 27617856.
 - 16 Clayton HB, Schieve LA, Peterson HB, Jamieson DJ, Reynolds MA, Wright VC. A comparison of heterotopic and intrauterine-only pregnancy outcomes after assisted reproductive technologies in the United States from 1999 to 2002. *Fertil Steril.* 2007;87:303-9. doi: 10.1016/j.fertnstert.2006.06.037. PubMed PMID: 17113092.