

The World's First Implantation of a Personalized Microporous Titanium Sternum with Motile Costal Clip Connections: A Case Report

Ilya V. Kolobaev¹, PhD; Denis Baranovskii^{1,2}, MD, PhD; Vladimir Usachev¹, MD; Grigoriy Afonin¹, MD; Oleg Aleksandrov³, PhD; Anna Usacheva¹, MD; Ilya D. Klabukov^{2,4}, PhD; Peter Shegay⁴, PhD; Sergei Ivanov¹, PhD; Andrey Kaprin^{2,4}, PhD

¹A. Tsyb Medical Radiological Research Center, Branch of the National Medical Research Radiological Center, Obninsk, Russia;

²Peoples' Friendship University of Russia (RUDN University), Moscow, Russia;

³P.A. Herten Moscow Oncology Research Institute, Branch of the National Medical Research Radiological Center of the Ministry of Health of Russia, Moscow, Russia;

⁴National Medical Research Radiological Center, Obninsk, Russia

Correspondence:

Oleg Aleksandrov, PhD;
2nd Botkinsky pr 2, 125284, Moscow, Russia
Tel: +7 9032753320

Email: Oleg.alexandrov@lcloud.com

Received: 25 October 2022

Revised: 14 February 2023

Accepted: 04 March 2023

Abstract

Extensive chest wall defects occur in 28% of all sternal resection cases and are a major challenge in thoracic surgery. These cases are generally considered “critical defects” requiring primary or secondary reconstruction using various types of flaps, mesh repairs, bone autografts, or endoprosthesis. The past decade witnessed rapid advances in the application of personalized endoprostheses in thoracic surgery. Surgeons began to use carbon or titanium grafts for personalized sternum replacement. The main advantages of these implants are superior cosmetic effect, biocompatibility, and low risk of infection. Herein, we present a case of a 55-year-old patient with an indication for extended sternum resection due to metastatic thyroid cancer. The patient underwent extended sternum resection, followed by the implantation of a personalized microporous titanium sternum equipped with graspers for atraumatic rib fixation.

Please cite this article as: Kolobaev IV, Baranovskii D, Usachev V, Afonin G, Aleksandrov O, Usacheva A, Klabukov ID, Shegay P, Ivanov S, Kaprin A. The World's First Implantation of a Personalized Microporous Titanium Sternum with Motile Costal Clip Connections: A Case Report. *Iran J Med Sci.* 2024;49(4): 268-271. doi: 10.30476/ijms.2023.97060.2873.

Keywords • Thoracic surgery • Sternum • Titanium • Bone replacement

What's Known

- There is increased surgical use of personalized carbon or titanium grafts for sternum replacement. The main advantages of these implants are superior cosmetic effect, biocompatibility, and low risk of infection.
- To date, there are few studies on the application of personalized sternum prostheses.

What's New

- Implantation of a personalized microporous titanium sternum with motile costal clip connections is safe and effective.
- The proposed novel endoprosthesis provides good functional results in long-term follow-up.

Introduction

On average, extensive chest wall defects occur in 28% of all sternal resection cases and are a major challenge in thoracic surgery.¹ These cases are generally considered “critical defects” requiring primary or secondary reconstruction using various types of flaps, mesh repairs, bone autografts, or endoprosthesis.² Recent studies have reported postoperative osteomyelitis as the leading cause of non-neoplastic disease after sternal resection and closure of the defect.³ However, extended resections (total or subtotal sternotomy) exceeding the limits of primary reconstruction often occur due to malignant neoplasms.⁴

The past decade has witnessed rapid advances in the application of personalized endoprostheses in thoracic surgery. Surgeons have begun to use personalized carbon or titanium grafts for sternum implantation.⁵ The main advantages of these novel implants are superior cosmetic effect, biocompatibility, and low risk of infection.⁶ However, the implantation of mesh and titanium plates may involve sternal plate fracture, sternoclavicular dislocation, and chronic chest pain.⁷ The failure rate can reach up to 11%, and in some cases bone damage may occur, leading to malunion with the development of false joints.

Herein, we report a case of extended sternum resection,

followed by the implantation of a personalized microporous titanium sternum equipped with graspers for atraumatic rib fixation.

Case Presentation

A 55-year-old Caucasian man with a history of thyroid cancer was admitted to the Thoracic Surgery Clinic of National Medical Radiology Research Centre (NMRRC; Obninsk, Russia) in September 2020. Computed tomography (CT) scan revealed metastatic lesions in the proximal left femur and manubrium sterni. The patient had already undergone thyroidectomy and femoral resection with endoprosthetic reconstruction. However, sternum pain restricted his arm movements. Chest CT scan revealed a soft tissue mass measuring approximately 60×45 mm associated with extensive destruction of sternal manubrium (figure 1a). The tumor extended from the jugular notch to the retrosternal space, located close to the left brachiocephalic vein (figure 1b). The tumor board of our clinic recommended extended sternal resection with primary reconstruction using personalized titanium endoprosthesis. The personalized treatment approach, study, and publication of the case report were approved by the Institutional Review Board (number: 067-B, dated: 10-05-2022). Written informed consent was obtained from the patient for the publication

of all pictures and data.

Based on a preoperative CT scan, the shape and size of the expected chest wall defect were determined. A custom endoprosthesis was modeled according to the anthropometric data under the supervision of the surgeon. The endoprosthesis was manufactured through layer-by-layer fusion of titanium powder, resulting in a microporous structure with connected internal cavities. The device was crab-shaped with two perforated pincers on each side for attachment to costal stumps (figure 2a). The lower part of each pincer was fixed to the body, while the upper part pivoted from a fixed rivet, allowing easy attachment to the rib end with a simple grip (figure 2b).

Prior to the surgery, a three-dimensional model was simulated to mark the exact resection area of the ribs and sternum (figure 3a). This ensured the accurate selection of tumor-free margins and the exact fit of the endoprosthesis in the sternal defect. Sternal resection was performed, followed by a crosscut of the first and second pairs of ribs and a clavicle dislocation on both sides. A defect in the anterior chest wall measuring approximately 10×7 cm was observed. The endoprosthesis was fixed to the sternum, and the sternoclavicular and sternocostal joints were reconstructed. The ribs were clipped quickly and easily in pincers. The implant was finally covered by the omental flap.

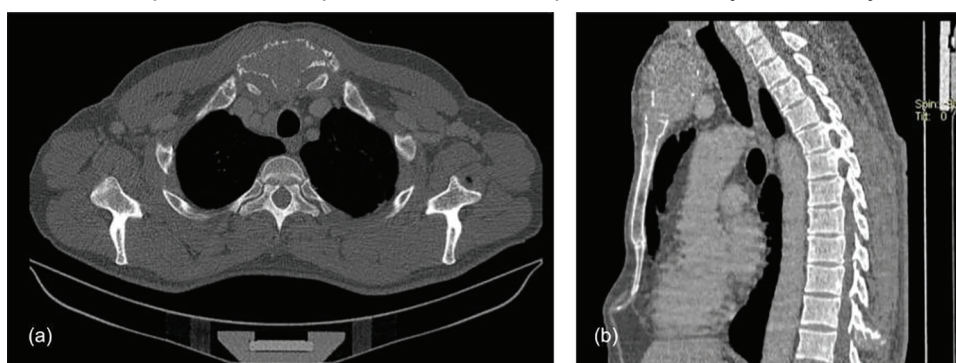


Figure 1: CT scan of the patient before surgery is illustrated. (a): Axial view of the anterior chest wall deformed by a massive tumor located in the manubrium sternum. (b): Sagittal view of the tumor soft tissue mass involving the jugular notch and expanding to the retrosternal.




Figure 2: The personalized microporous titanium sternum designed for sternum replacement of the patient. (a): General view of the crab-shaped prosthesis with two perforated pincers on each side. (b): The lower part of each pincer is fixed to the prosthesis, while the upper part pivoted from a fixed rivet, allowing easy clip on the rib end after implantation.

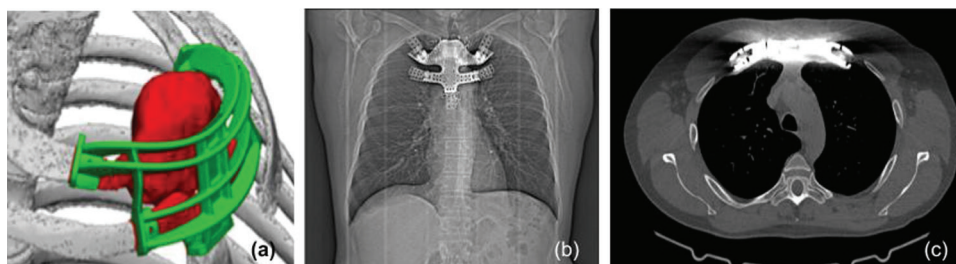


Figure 3: Three-dimensional simulation of the implant and the chest CT scan of the patient two years after surgery. (a): The model (green color) marks the exact resection area of the ribs and sternum (red color). (b): Overall appearance of the implant shows no evidence of deformation. (c) An axial view of the rib ends shows that the implant has remained fully fixed.

The early postoperative period was uneventful, and the patient was discharged 10 days after surgery. A chest CT scan was performed every six months to monitor the progress. The implant did not cause any pain or discomfort during the 24-month follow-up, and the patient was able to conduct daily activities. At the end of the follow-up, the CT scan showed that the implant remained fully fixed without any evidence of deformation (figures 3b and 3c). Physical examination of the patients showed excellent functional and cosmetic results.

Discussion

Primary malignant sternal tumors are rare and are mostly sarcomas of the bone or soft tissues of the sternum. The majority of surgeries are performed in patients with breast cancer, chondrosarcoma, and metastatic lesions.⁸ In particular, metastatic chest wall tumors are observed in 29% of these patients.⁹ Materials used to repair sternal defects are not standardized, and none are considered the gold standard for chest wall reconstruction.¹⁰ In addition, due to the rarity of sternal neoplasms, current studies are generally published in the form of case reports or case series. Carvajal and colleagues retrospectively reviewed the clinical records of 77 patients with primary or secondary chest wall neoplasms. Over 60% of these patients were treated with subtotal or total sternectomy. Prosthetic materials were used in only 18% of the patients, while the majority of reconstructions were limited to muscle flaps or skin grafts.¹¹ Since 1980, surgeons have used materials such as polytetrafluoroethylene, polypropylene mesh, and methyl methacrylate composites combined with myocutaneous flaps. Despite acceptable morbidity and mortality rates, accurate anatomical reconstruction is not achieved, leading to poor functional and physiological outcomes as well as respiratory complications.

The main goals of reconstruction are the

structural integrity of the thoracic cage and the protection of the pleural cavity. It is important to prevent abnormal breathing and restore normal morphology of the thorax without affecting postoperative recovery and treatment. In many cases of metastasis to the sternum, consolidation chemotherapy is indicated even after radical resection. Currently, due to the lack of consensus, various types of prosthetic materials are used for sternal reconstruction. Titanium implants have clear advantages over other materials in terms of personalization and optimal cosmetic effect. However, as a limitation, titanium mesh is expensive and attenuates radiotherapy.¹⁰ In addition, fluid accumulation around the transplant is one of its most common complications,¹² although it did not occur in our patient. Microporous metal structures have an optimal strength-to-weight ratio, which is important for massive grafts.¹² Moreover, microporous titanium acts as a scaffold for bone tissue integration and promotes local tissue regeneration.¹³

Overall, the proposed novel pincer clip system allows easy connection and provides secure fixation of the implant on the ribs. Gripping the rib end with a movable part of the pincer avoids pressure on intercostal nerves and reduces the risk of rib fracture as a result of excessive tension. The proposed system is well-suited to human physiology.

Conclusion

Implantation of a personalized microporous titanium sternum with motile costal clip connections was safe and effective. It provided good functional results in long-term follow-up.

Acknowledgment

We thank our partners at Logeeks Medical Systems, LLC (Novosibirsk, Russia) for elaborating and manufacturing the 3D-printed titanium graft.

Authors' Contribution

V.U, GA: Surgical procedure and operation, data collection. IV.K: Supervising the manufacture of the implant, supervising the surgeon, and postoperative treatment. D.B: Study design, data collection, and analysis. P.S., S.I, A.K: Supporting the research team, supervising surgeon. D.B, A.U, ID.K, O.A: Data analysis, writing the manuscript. All authors revised the manuscript and approved the final version for publication.

Conflict of Interest: None declared.

References

- 1 Salo JTK, Tukiainen EJ. Oncologic Resection and Reconstruction of the Chest Wall: A 19-Year Experience in a Single Center. *Plast Reconstr Surg.* 2018;142:536-47. doi: 10.1097/PRS.0000000000004597. PubMed PMID: 29889739.
- 2 Divisi D, Tosi D, Zaccagna G, De Vico A, Diotti C, Crisci R. Case Report: A New Tool for Anterior Chest Wall Reconstruction After Sternal Resection for Primary Or Secondary Tumors. *Front Surg.* 2021;8:691945. doi: 10.3389/fsurg.2021.691945. PubMed PMID: 34355015; PubMed Central PMCID: PMC68331331.
- 3 Gokce A, Babaroglu S, Ergani H. Multidisciplinary Surgery In Thoracic Wall Reconstruction For Sternal Osteomyelitis. *Authorea.* 2020. doi: 10.22541/au.160736489.93339258/v1.
- 4 Dell'Amore A, Kalab M, Miller AS, 3rd, Dolci G, Liparulo V, Beigee FS, et al. Indications and Results of Sternal Allograft Transplantation: Learning From a Worldwide Experience. *Ann Thorac Surg.* 2021;112:238-47. doi: 10.1016/j.athoracsur.2020.08.032. PubMed PMID: 33080234.
- 5 Wang B, Guo Y, Tang J, Yu F. Three-dimensional custom-made carbon-fiber prosthesis for sternal reconstruction after sarcoma resection. *Thorac Cancer.* 2019;10:1500-2. doi: 10.1111/1759-7714.13084. PubMed PMID: 31094079; PubMed Central PMCID: PMC6558465.
- 6 Motono N, Shimada K, Kamata T, Uramoto H. Sternal resection and reconstruction for metastasis due to breast cancer: the Marlex sandwich technique and implantation of a pedicled latissimus dorsi musculocutaneous flap. *J Cardiothorac Surg.* 2019;14:79. doi: 10.1186/s13019-019-0905-z. PubMed PMID: 30999925; PubMed Central PMCID: PMC6471832.
- 7 Elahi L, Zellweger M, Abdelnour-Berchtold E, Gonzalez M, Ris HB, Krueger T, et al. The size and sternal involvement of chest wall resections for malignant disease predict postoperative morbidity. *Transl Cancer Res.* 2022;11:1162-72. doi: 10.21037/tcr-21-2143. PubMed PMID: 35706797; PubMed Central PMCID: PMC9189217.
- 8 Sanna S, Ciarrocchi A, Campisi A, Mazzarra S, Argnani D, Davoli F, et al. Chest Wall Reconstruction after Surgical Resection: An Approach towards Various Techniques and Materials. *Highlights on Medicine and Medical Science Vol 12.* 2021:72-92. doi: 10.9734/bpi/hmms/v12/9702D.
- 9 Carvajal C, Ramirez AM, Guerrero-Macias S, Beltran R, Buitrago R, Carreno J. A South American Experience With Postoperative Complications Following Chest Wall Reconstruction for Neoplasms. *World J Surg.* 2021;45:2982-92. doi: 10.1007/s00268-021-06215-z. PubMed PMID: 34180010.
- 10 Zhang Y, Li JZ, Hao YJ, Lu XC, Shi HL, Liu Y, et al. Sternal tumor resection and reconstruction with titanium mesh: a preliminary study. *Orthop Surg.* 2015;7:155-60. doi: 10.1111/os.12169. PubMed PMID: 26033997; PubMed Central PMCID: PMC6583156.
- 11 Carvajal C, Ramirez AM, Guerrero-Macias S, Beltran R, Buitrago R, Carreno J. A South American Experience With Postoperative Complications Following Chest Wall Reconstruction for Neoplasms. *World J Surg.* 2021;45:2982-92. doi: 10.1007/s00268-021-06215-z. PubMed PMID: 34180010.
- 12 Thelen S, Barthelat F, Brinson LC. Mechanics considerations for microporous titanium as an orthopedic implant material. *J Biomed Mater Res A.* 2004;69:601-10. doi: 10.1002/jbm.a.20100. PubMed PMID: 15162401.
- 13 Baranovskii DS, Akhmedov BG, Demchenko AG, Krashennikov ME, Balyasin MV, Pavlova OY, et al. Minimally Manipulated Bone Marrow-Derived Cells Can Be Used for Tissue Engineering In Situ and Simultaneous Formation of Personalized Tissue Models. *Bull Exp Biol Med.* 2022;173:139-45. doi: 10.1007/s10517-022-05509-z. PubMed PMID: 35622254.