

# Sclerosing Hemangioma of the Lung: Report of a Case

V. Montazeri \*, M. Sokouti \*, A. Fakhrujii \*\*

## Abstract

Sclerosing hemangioma of the lung is extremely rare. Herein, a case of sclerosing hemangioma of the lung in a 44-year-old woman is reported. On admission, the patient complained of pain in the left lower neck and upper chest. Chest x-ray revealed a mass in lingular lobe of the left lung. The patient underwent surgery and a mass was removed through left posterolateral thoracotomy. Pathologic findings confirmed sclerosing hemangioma. Sclerosing hemangioma of the lung should be considered in asymptomatic patients or those with symptoms in chest or lower neck.

**Iran J Med Sci 2003; 28 (3):151-153.**

**Keywords** • Hemangioma • lung • surgery

## Introduction

**S**clerosing hemangioma of the lung (SHL) is generally solitary and considered a benign lesion. It grows slowly<sup>1</sup> and lymph node metastasis is rarely reported.<sup>2</sup> In 1956 Liebow and Hubbel defined pulmonary fibrosing hemangioma as a markedly vascular proliferation with a tendency to fibrosis, and associated with papillary vegetation, extensive histiocytic infiltration and hemorrhages at various stages of organization. Currently, it is considered as a tumor proliferation which, on the basis of data from electron microscopy and histochemistry, is felt by some authors to be of vascular while others underscore an epithelial origin which develops apparently from immature type 2 pneumocytes. However, the designation " Benign Fibrosing Pneumocytoma " suggested by Chan seem to be more appropriate.<sup>1,3</sup> This lesion occurs most often in the middle-aged women.<sup>3,4</sup> Herein, we describe a case of benign sclerosing hemangioma of the lung presenting with pain in the left lower neck and upper chest and good surgical outcome.

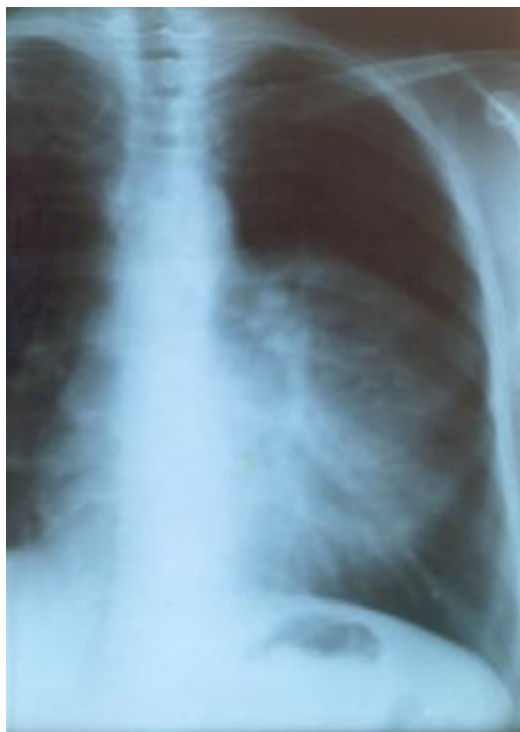## Case Presentation

A 44-year-old female was admitted to thoracic surgical ward with a history of pain in the left lower neck and left upper chest of two months duration. There was no history of cough, fever, or weight loss. On general physical examination, there were decreased respiratory sounds in the left upper chest. She was otherwise completely well. Chest x-ray showed a well-defined opacification in the lingula and left upper lobe (Fig 1). On CT scan, a stricture of the lingular bronchus with a well-defined consolidation was noticed. In bronchoscopic examination compression of the left upper lobe bronchus was detected. Pathologic examination of bronchoscopic biopsies was negative for malignancy. The patient underwent a left posterolateral

\*Departments of Thoracic Surgery, Tabriz University of Medical Sciences, Tabriz, Iran

\*\* Departments of Pathology, Tabriz University of Medical Sciences, Tabriz, Iran

**Correspondence:** V. Montazeri M.D., Department of Thoracic Surgery, Imam Khomeini Hospital, Tabriz University of Medical Science, Tabriz, Iran  
**Tel :** +98-411-3363232  
**Email :** [aaayda@hotmail.com](mailto:aaayda@hotmail.com)

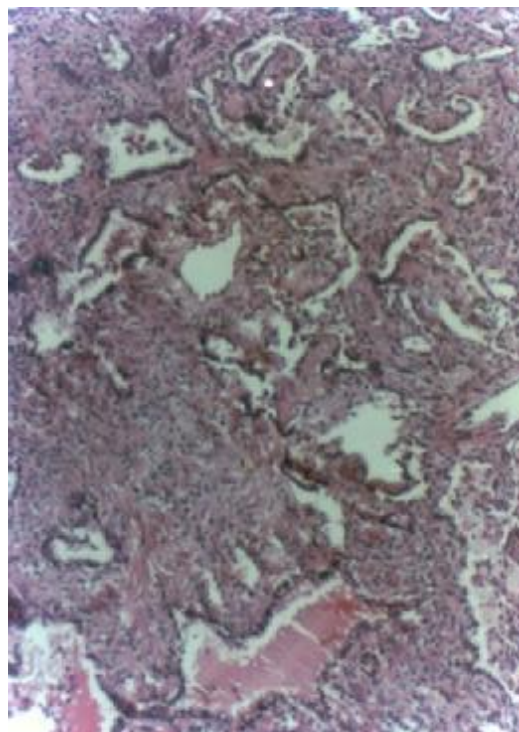


**Fig 1:** Chest X-ray showing opacification in the lingual and left upper lobe

thoracotomy and a LUL with lingula lobectomy. Pathologic examination of the mass revealed benign sclerosing hemangioma of the lung. (Fig 2)

### Discussion

Sclerosing hemangioma proposed by Liebow and Hubbel defines a subset of benign tumor and tumor-like lesions of the lung. This subset differs from plasma cell granuloma and pseudolymphoma and may include cases of xanthomatous pseudotumor, post-inflammatory pseudotumor, fibrous histiocytoma, alveolar angioblastoma, and pneumocytoma. The cells of origin were initially considered to be endothelial akin to a tumor of the dermis of the skin.<sup>3</sup> Macroscopic appearance of the tumor was white to yellowish-brown in color and fleshy to fibrous in consistency. A thin fibrous pseudocapsule separated the tumor from adjacent pulmonary parenchyma and the surface of the tumor was hypervascular, tending to bulge out on sectioning. Subsequent electron microscopic studies suggested either alveolar pneumocytes or mesothelium as the origin. Multiple authors utilizing immunologic studies have supported the hypothesis that both bronchioles and alveolar type 2 pneumocytes



**Fig 2:** Sclerosing hemangioma, with cuboidal cells arranged in a papillary fashion and sheets. Small vessels with hyalinized walls and small spaces lined by cuboidal cells are scattered in sclerotic area and angiomatous areas (10x10, H&E)

constitute simultaneously the cells of origin.<sup>3,5,6</sup> However other investigators now consider this tumor to be primarily a proliferation of the epithelial cells. The results of staining were positive for epithelial membrane antigen and subsequent apoprotein, which are the markers of epithelial cells, and negative for factor 8 related antigens of endothelial cells suggested that the origin of the SHL might be type 2 pneumocytes.<sup>4</sup> Anti-lung surfactant apoprotein monoclonal antibody was detected in the rough endoplasmic reticulum in some of the cells in the solid areas. In spite of these studies the exact histogenesis of SHL remains uncertain as was also the case in some previous studies.<sup>2,7</sup> Microscopically the histologic features of SHL varied and four major histologic patterns were found in the same histological section: solid, papillary, hemangiomatous and sclerotic patterns.<sup>4,8,6</sup>

Sclerosing hemangioma of the lung is recognized as a distinct clinicopathological entity. It is a benign neoplasm, probably of epithelial origin.

### Sclerosing hemangioma of the lung

Clinically the tumor is asymptomatic and is mostly seen in middle aged women.<sup>9</sup>

Chest pain, hemoptysis, fever, and productive cough are rarely seen.<sup>1</sup> SHL is often detected incidentally as a round, well-defined homogenous mass on routine chest radiography.<sup>1,9</sup> Sometimes an air trapping zone surrounding SHL or air meniscus sign is observed. A paranchymal mass without calcification on chest X-ray is suggestive of benign SHL.<sup>10</sup> Bilaterality is a rare finding.<sup>1</sup> Metastasis to multiple lymph nodes and contralateral lung is also rarely seen.<sup>1,11</sup> The lesion usually presents as a solitary mass or nodules. The greatest diameter of the tumor on chest roentgenogram has ranged from 13 to 82 mm.

The diagnosis is based on histo-pathohistologic examination of the biopsy material. Therapy is surgical and prognosis is excellent.<sup>9</sup> In our case, pathologic findings were of solid and papillary type in accordance with the findings reported elsewhere.<sup>4</sup>

### Acknowledgement

We thank Dr. M. Bahadori for his help in reviewing pathologic examinations.

### References

- 1 Lee ST, Lee YC, Hsu CY, Lin CC: Bilateral multiple sclerosing hemangioma of the lung. *Chest* 1992;**101**(2):572-3 .
- 2 Tanaka I, Inoue M, Oritsu S, et al: A case of pneumocytoma (so-called sclerosing hemangioma) with lymph node metastasis. *Jpn J Clin Oncol* 1986;**16**(1):77-86.
- 3 Gaucher L, Patra P, Despins P, et al: A rare tumor: benign sclerosing pneumocytoma with an intrascissural development. *Poumon Coeur* 1983;**39**(6):321-6.
- 4 Sugio K, Yokoyama H, Kaneko S, et al: Sclerosing hemangioma of the lung: radiographic and pathological study. *Ann Thorac Surg* 1992; **53**(2):295-300.
- 5 Shimosato Y: Lung tumors of uncertain histogenesis. *Semin Diag Pathol* 1995;**12**(2):185-92.
- 6 Yousem SA, Wick MR, Singh G, et al: So-called sclerosing hemangioma of lung. An Immunohistochemical study supporting a respiratory epithelial origin. *Am J Surg Pathol* 1988; **12**(8):582-90 .
- 7 Satoh Y, Tsuchiya E, Weng SY, et al: Pulmonary sclerosing hemangioma of the lung. A type 2 pneumocytoma by immunohistochemical and immunoelectron microscopic studies. *Cancer* 1989;**64**(6):1310- 7.
- 8 Heikkila P, Salminen US: Papillary pneumocytoma of the lung. An immunohistochemical and electron microscopic study. *Pathol Res Pract* 1994;**190**(2):194-200.
- 9 Batinica S, Gunek G, Raos M, et al: Sclerosing hemangioma of the lung in a 4- years-old child. *Eur J Pediatr Surg* 2002;**12**(3):192-4.
- 10 Nam JE, Ryu YH, Cho SH, et al: Air-trapping zone surrounding sclerosing hemangioma of the lung. *J Comput Assist Tomogr* 2002; **26**(3):358-61.
- 11 Yano M, Yamakawa Y, Kiriya M, et al: Sclerosing hemangioma with metastases to multiple nodal stations. *Ann Thorac Surg* 2002; **73**(3):981- 3.