

# The Use of Feature Tracking Technique for the Quantification of Ventricular Strain Pattern in Patients with Ebstein's Anomaly: A Case-Control Study

Marzieh Motevalli<sup>1</sup>, MD;  Ali Allameh<sup>2</sup>, MD; Ghazale Tefagh<sup>3</sup>, MD, MPH; Hamidreza Pouraliakbar<sup>1</sup>, MD; Parham Rabiei<sup>1</sup>, MD; Sanaz Asadian<sup>1</sup>, MD; Kasra Kiani Amin<sup>1</sup>, MD; Golnaz Houshmand<sup>1</sup>, MD; Mohammad-Ali Mohammadi-Vajari<sup>4</sup>, MD 

<sup>1</sup>Rajaie Cardiovascular, Medical and Research Center, School of Medicine, Iran University of Medical Sciences, Tehran, Iran;

<sup>2</sup>Department of Radiology, School of Medicine, Iran University of Medical Sciences, Tehran, Iran;

<sup>3</sup>Department of Radiology, Advanced Diagnostic and Interventional Radiology Research Center, Imam Khomeini Hospital, School of Medicine, Tehran University of Medical Sciences Tehran, Iran;

<sup>4</sup>Department of Radiology, Hazrat Rasoul Akram Hospital, School of Medicine, Iran University of Medical Sciences, Tehran, Iran

## Correspondence:

Mohammad-Ali Mohammadi-Vajari, MD; Hazrate Rasool Akram Hospital, Niayesh St., Satar Khan Ave., Postal code: 14665-354, Tehran, Iran  
Tel/Fax: +98 21 64351000

Email: malimv71@yahoo.com

Received: 13 February 2021

Revised: 17 April 2021

Accepted: 08 July 2021

## What's Known

- Cardiac magnetic resonance imaging (CMR) provides complete ventricular coverage and allows strain measurements to indicate changes in contraction patterns for early diagnosis of Ebstein's anomaly (EA).
- Controversy exists on the pattern of changes in ventricular strain in patients with EA.

## What's New

- Markers such as left ventricular (LV) longitudinal strain and right ventricular global longitudinal strain (RV-GLS) are the most suitable parameters for the early diagnosis of heart dysfunction.
- A significantly lower LV radial strain and RV-GLS were found in EA patients compared to healthy individuals.

## Abstract

**Background:** Ebstein's anomaly (EA) is a congenital heart disorder characterized by abnormal function of the tricuspid valve. There are several ways to study tissue composition using magnetic resonance imaging (MRI). One of the most accurate methods is strain calculation using the feature tracking (FT) technique. Due to the novelty of the FT technique in cardiac magnetic resonance (CMR) imaging, there is a lack of comprehensive guidelines to conduct FT-MRI and to present a quantitative report. The current study is aimed to evaluate the FT technique in EA patients and to compare the obtained numerical values with those of healthy individuals.

**Methods:** A total of 33 individuals were enrolled in a study conducted in 2018-2019 at Shahid Rajaei Hospital, Tehran, Iran. Radial, longitudinal, and circumferential strain patterns of the left and right ventricles were determined in both the patients and controls using the FT technique. Data were analyzed using SPSS software, version 22.0.

**Results:** The results showed a significantly lower left ventricular (LV) radial strain in EA patients compared to the control group ( $P=0.002$ ). In addition, the right ventricular (RV) global longitudinal strain (GLS) in EA patients was significantly lower than in the controls ( $P=0.001$ ). Other parameters (LV global longitudinal strain, RV radial strain, LV circumferential strain, and RV circumferential strain) did not differ significantly between the two groups.

**Conclusion:** Determination of strain patterns using cardiac MRI is a promising method for the diagnosis of EA. Markers such as LV longitudinal strain and RV-GLS are the most suitable parameters for the early diagnosis of heart dysfunction.

Please cite this article as: Motevalli M, Allameh A, Tefagh G, Pouraliakbar H, Rabiei P, Asadian S, Kiani Amin K, Houshmand G, Mohammadi-Vajari MA. The Use of Feature Tracking Technique for the Quantification of Ventricular Strain Pattern in Patients with Ebstein's Anomaly: A Case-Control Study. Iran J Med Sci. doi: 10.30476/IJMS.2021.90064.2088.

**Keywords** • Ebstein anomaly • Cardiovascular abnormalities • Cardiac imaging techniques • Magnetic resonance imaging • Diagnostic imaging

## Introduction

Ebstein's anomaly (EA) is a congenital heart disorder that occurs in one per 200,000 live births and accounts for up to

1% of all critical congenital heart defects.<sup>1</sup> The main characteristic of EA is abnormal apical displacement and function of the tricuspid valve, which may result in cardiomegaly or heart failure.<sup>2</sup> Clinical characteristics of the disease vary depending on its severity and presence of other related abnormalities. In patients with EA, symptoms such as heart failure, cyanosis, arrhythmia, and sudden cardiac death are common.<sup>3</sup> Typical criteria for EA include adherence of the septal and posterior leaflet of the tricuspid valve to the underlying myocardium (failure of delamination), downward displacement of the tricuspid valve, dilatation of the atrialized portion of the right ventricle and tethering, redundancy of anterior valve, and dilation of true tricuspid annulus.<sup>4, 5</sup>

EA is usually diagnosed based on echocardiographic findings. However, it has been reported that cardiac magnetic resonance (CMR) imaging can provide more detailed visualization to assess this abnormality and is an accurate method for physiological evaluations.<sup>6</sup> Magnetic resonance imaging (MRI) measures the water content of body tissues by resonating the nucleus of a hydrogen atom. The measured signal is then processed to produce a black and white image depending on the signal intensity. Several methods have been developed to study tissue composition using MRI including T2 mapping, T2\* mapping, T1 mapping, late gadolinium enhancement (LGE) imaging, and perfusion and diffusion imaging. Unfortunately, the results of gadolinium, late gadolinium, and short-tau inversion-recovery (STIR) imaging are not reproducible in CMR due to the risk of gadolinium retention and numerous artifacts. Despite the availability of various detection methods, there are no powerful diagnostic and prognostic tools to detect changes in mechanical and tensile patterns in various cardiovascular diseases.<sup>7</sup> One of the most accurate and new methods in cardiovascular imaging is the calculation of strain using the feature tracking (FT) technique. This imaging technique has been proposed as the only MRI technique capable of diagnosing cardiac diseases in their subclinical stage. The technique involves calculating all longitudinal, axial, and radial myocardial strains to predict the occurrence of cardiac tensile changes.<sup>8</sup>

Due to the novelty of the FT technique in cardiovascular MRI, there is a lack of comprehensive guidelines on how to conduct FT-MRI and to present a quantitative report. The current study is aimed to evaluate the use of FT in EA patients and to compare the obtained numerical values with those of healthy individuals.

## Patients and Methods

A case-control study was conducted in 2018-2019 at Shahid Rajaei Hospital, Tehran, Iran. The study was approved by the Ethics Committee of Iran University of Medical Sciences (IR.IUMS. FMD.REC.1397.231). The participants were informed about the research methodology and voluntary participation was emphasized. Written informed consent was obtained from all participants. Possible withdrawal from the study did not interfere with patients' optimal treatment course and care.

A total of 33 individuals (18 patients and 15 healthy controls) were enrolled in the study. The inclusion criteria for the patient group were confirmed diagnosis of EA and no cardiovascular abnormalities. For the participants in the control group, it was a prerequisite not to have any cardiovascular issues. The exclusion criteria for both groups were unwillingness to participate and unavailability for the MRI scan.

In accordance with a guideline proposed in a previous study,<sup>9</sup> CMR imaging was performed by an expert radiologist using the 1.5 Tesla MR system (Magnetom Avanto, Siemens Medical Systems, Germany). The CMR sequences are listed below.

- 2-, 3-, and 4-chamber view, short-axis, right ventricular outflow tract, retrospective cine 2D true fast imaging with steady-state free precession (true-FISP) MRI
- 4- and 2-chamber view, short-axis STIR, and T1-weighted imaging
- 4- and 2-chamber view, short-axis 8-echo gradient recalled echo (GRE) MRI
- Dynamic T1-weighted, fast low angle shot contrast-enhanced perfusion short-axis MRI
- Early true-FISP post-gadolinium MRI
- Measuring flow quantification aorta and pulmonary artery flow using phase-contrast through-plane imaging in the aorta and main pulmonary artery just above the aortic and pulmonary valves
- Late phase-sensitive inversion-recovery post-gadolinium MRI (TI from 200 to 500)

Subsequently, longitudinal, radial, and circumferential strain patterns in both the patients and control groups were determined with FT using a commercially available semi-automatic software (CVi42; Circle cardiovascular imaging Inc., Calgary, Canada).

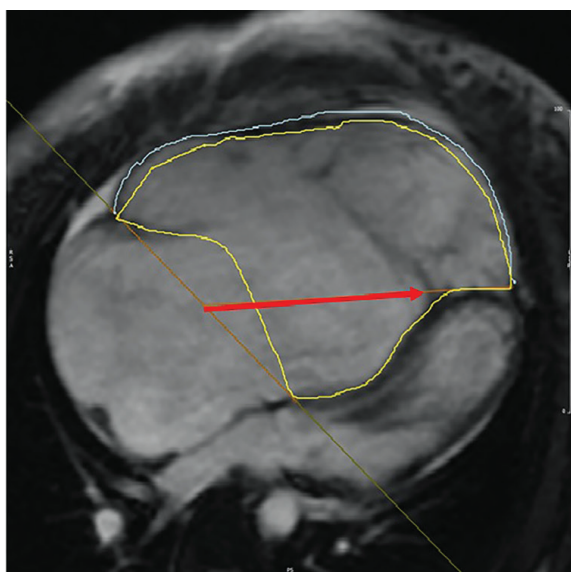
### Statistical Analysis

Data were analyzed using SPSS software for Windows, version 22.0 (IBM Corp., Armonk, N.Y., USA). The Shapiro-Wilk test was used to examine the normal distribution of data. Data

with normal distribution were analyzed using *t* test, and those not normally distributed were compared using the Mann-Whitney U test. *P*<0.05 was considered statistically significant.

## Results

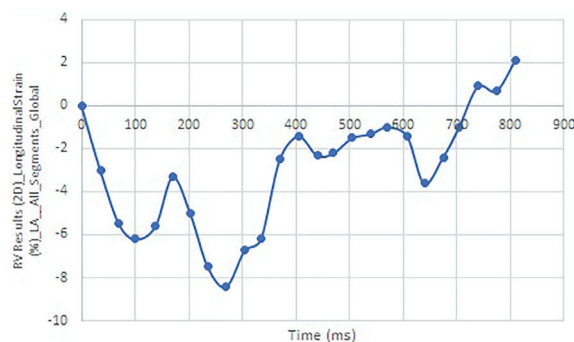
The patient group included 18 patients (8 men and 10 women) with a mean age of 24.83±13.34 and the control group included 15 healthy individuals (seven men and eight women) with a mean age of 29.27±12.54. A comparison of echocardiographic indices showed a significant difference in all variables between the patient and control groups (table 1). The measurement and analysis of longitudinal, radial, and circumferential) strain patterns are presented in figures 1-4 and table 2, respectively. The results showed a significantly lower left ventricular (LV) radial strain and right ventricular (RV) global longitudinal strain (GLS) in the patient group compared to the control group. Other parameters (LV-GLS, RV radial strain, LV circumferential strain, and RV circumferential strain) did not differ significantly between the two groups.



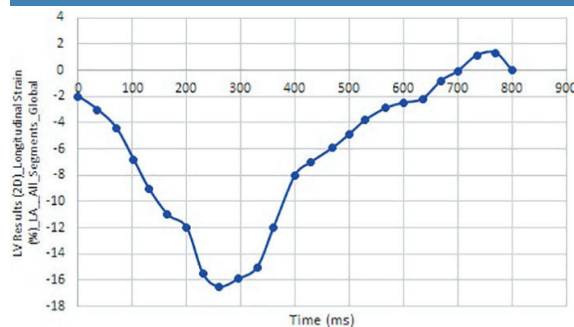
**Figure 1:** The figure shows the right ventricular strain measurement including the sum of functional and atrialized right ventricle. Yellow line: The endocardial border of the right ventricle; Blue line: Right ventricular myocardium; Red arrow: The anatomy of the right ventricle annulus; Oblique orange: The displaced septal tricuspid leaflet attachment

## Discussion

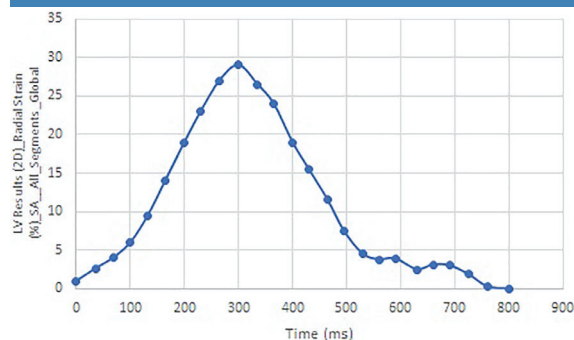
Echocardiography is commonly used to diagnose EA by determining abnormalities of the tricuspid valve and heart ventricles. However, recent advances in MRI technology and subsequent CMR imaging technique have greatly facilitated accurate non-invasive



**Figure 2:** Right ventricular global longitudinal strain pattern reveals reduced values in the functional and atrialized right ventricle (normal RV-GLS: -24.3±4.7).



**Figure 3:** Left ventricular global longitudinal strain patterns were shown to be below-normal (normal LV-GLS range: from -15.9% to -22.1%)



**Figure 4:** Left ventricular global radial strain patterns were shown to be reduced in Ebstein's anomaly (normal LV GRS range: from 35.1% to 59.0%)

**Table 1:** Echocardiographic indices of the right and left ventricles in the patient and control groups

Features	Patients (n=18)	Control (n=15)	P value
LVEF (%)	47.11	56.15	0.038
RVEDVI (range in mL/m <sup>2</sup> )	110.54±36.10	80.13±5.97	0.021
RVESVI (range in mL/m <sup>2</sup> )	70.85±40.00	36.22±12.09	<0.010
RVEF (%)	40.77±6.33	50.99±6.23	0.034

LVEF: Left ventricular ejection fraction; RVEDVI: Right ventricular end-diastolic volume index; RVESVI: Right ventricular end-systolic volume index; RVEF: Right ventricular ejection fraction; Data with normal distribution were analyzed using *t* test and those not normally distributed were compared using the Mann-Whitney U test. *P*<0.05 was considered statistically significant.

**Table 2:** Comparison of the radial, longitudinal, and circumferential strain of the left and right ventricles between the case and control groups

Variables	Groups	Mean±SD	P value
LV-GLS	Case	15.71±3.26	0.091
	Control	13.92±2.49	
LV radial strain	Case	30.71±9.34	0.002
	Control	41.60±9.81	
LV circumferential strain	Case	16.29±5.08	0.293
	Control	17.79±2.20	
RV-GLS	Case	15.62±1.98	0.001
	Control	26.19±3.63	
RV radial strain	Case	28.01±9.19	0.147
	Control	22.86±10.06	
RV circumferential strain	Case	14.14±11.30	0.718
	Control	12.96±5.25	

RV: Right ventricular; LV: Left ventricular; GLS: Global longitudinal strain; Data with normal distribution were analyzed using t test and those not normally distributed were compared using the Mann-Whitney U test. P<0.05 was considered statistically significant.

assessment of the cardiovascular system. Compared to echocardiography, CMR can provide high-resolution images, rendering both accurate and reproducible measurements of the RV and LV anatomy. CMR not only provides complete coverage of the heart ventricles but also allows the measurement of strain that can show changes in contraction patterns for early diagnosis of EA. Nowadays, CMR is considered an ideal technique for detecting EA.<sup>10</sup> The present study was instigated to determine the diagnostic value of CMR findings in patients with EA.

Strain is a suitable and sensitive marker for the diagnosis of functional disorders of the heart for which CMR is of great clinical value. Moreover, changes to this marker precede changes detected by the commonly used parameter ejection fraction (EF).<sup>11</sup> This has been confirmed by some studies reporting a reduction in strain values prior to the detection of a decrease in EF in patients with ischemic heart disease and arrhythmogenic right ventricular cardiomyopathy.<sup>12, 13</sup> Besides, another study reported that both RV and LV longitudinal and circumferential strains were significantly lower in patients with tetralogy of Fallot (TOF) and abnormal EF, compared to controls with TOF and normal EF. Moreover, the mean RV longitudinal strain did not differ between patients with TOF and normal EF and healthy individuals.<sup>14</sup>

Our results showed that the mean range of LV-GLS in patients with EA was higher than in the control group, but the difference was not statistically significant. However, the mean range of LV radial circumferential strain was significantly lower than in the control group. In contrast to our findings, a previous study reported a good agreement between LV-GLS measured using CMR and transthoracic echocardiography (TTE), while the agreement

was poor for circumferential strain and all strain rate measurements.<sup>15</sup> They concluded that since cardiac echocardiography is limited by inadequate acoustic windows, CMR can be an acceptable alternative in assessing myocardial strain patterns as a predictor of early systolic dysfunction. However, in line with our results, another study showed that LV-GLS and LV interventricular dyssynchrony did not differ significantly between EA patients and controls.<sup>16</sup> Further studies with a larger sample size are required to determine the best strain parameter for evaluating LV strain and function in EA patients. We also found a significant decrease in RV-GLS in EA patients compared to the controls. Similarly, Steinmetz and colleagues showed that RV-GLS was significantly lower in EA patients than in the controls. They also reported a significantly higher RV interventricular dyssynchrony in EA patients compared to healthy controls.<sup>16</sup> It seems that RV-GLS can be confidently used in EA patients to evaluate RV function and to predict a decline in EF.

The main limitations of the study were the small sample size and the lack of clinical evaluation of the patients. Further studies with large samples and evaluation of both CMR and clinical characteristics of the patients are recommended. The latter allows a better understanding of the required criteria and identification of the optimum LV strain parameter to determine LV function in EA patients. In addition, it is recommended to evaluate the significance of strain patterns in predicting the clinical course of EA.

## Conclusion

Detection and determination of strain patterns using CMR can be considered as a reproducible

and non-invasive method for the diagnosis of EA. Of the different parameters, LV longitudinal strain and RV-GLS were the most important parameters for early diagnosis of heart dysfunction.

### Acknowledgment

We would like to thank all the staff of the Radiology Department of Shahid Rajaei Hospital for their proactive collaboration.

**Conflict of Interest:** None declared.

### References

- 1 Ports TA, Silverman NH, Schiller NB. Two-dimensional echocardiographic assessment of Ebstein's anomaly. *Circulation*. 1978;58:336-43. doi: 10.1161/01.cir.58.2.336. PubMed PMID: 668083.
- 2 Anderson KR, Lie JT. Pathologic anatomy of Ebstein's anomaly of the heart revisited. *Am J Cardiol*. 1978;41:739-45. doi: 10.1016/0002-9149(78)90826-3. PubMed PMID: 645580.
- 3 Perdreau E, Tsang V, Hughes ML, Ibrahim M, Kataria S, Janagarajan K, et al. Change in biventricular function after cone reconstruction of Ebstein's anomaly: an echocardiographic study. *Eur Heart J Cardiovasc Imaging*. 2018;19:808-15. doi: 10.1093/ehjci/jex186. PubMed PMID: 28950308.
- 4 Malhotra A, Agrawal V, Patel K, Shah M, Sharma K, Sharma P, et al. Ebstein's Anomaly: "The One and a Half Ventricle Heart". *Braz J Cardiovasc Surg*. 2018;33:353-61. doi: 10.21470/1678-9741-2018-0100. PubMed PMID: 30184032; PubMed Central PMCID: PMC6122759.
- 5 Attenhofer Jost CH, Connolly HM, Edwards WD, Hayes D, Warnes CA, Danielson GK. Ebstein's anomaly - review of a multifaceted congenital cardiac condition. *Swiss Med Wkly*. 2005;135:269-81. doi: 2005/19/smw-10985. PubMed PMID: 15986264.
- 6 Cantinotti M, Bell A, Razavi R. Role of magnetic resonance imaging in different ways of presentation of Ebstein's anomaly. *J Cardiovasc Med (Hagerstown)*. 2008;9:628-30. doi: 10.2459/JCM.0b013e3282f21654. PubMed PMID: 18475134.
- 7 Choi YH, Park JH, Choe YH, Yoo SJ. MR imaging of Ebstein's anomaly of the tricuspid valve. *AJR Am J Roentgenol*. 1994;163:539-43. doi: 10.2214/ajr.163.3.8079839. PubMed PMID: 8079839.
- 8 Attenhofer Jost CH, Edmister WD, Julsrud PR, Dearani JA, Savas Tepe M, Warnes CA, et al. Prospective comparison of echocardiography versus cardiac magnetic resonance imaging in patients with Ebstein's anomaly. *Int J Cardiovasc Imaging*. 2012;28:1147-59. doi: 10.1007/s10554-011-9923-1. PubMed PMID: 21822629.
- 9 Yoon YE, Hong YJ, Kim HK, Kim JA, Na JO, Yang DH, et al. 2014 Korean guidelines for appropriate utilization of cardiovascular magnetic resonance imaging: a joint report of the Korean Society of Cardiology and the Korean Society of Radiology. *Korean J Radiol*. 2014;15:659-88. doi: 10.3348/kjr.2014.15.6.659. PubMed PMID: 25469078; PubMed Central PMCID: PMC4248622.
- 10 Afonso L, Hari P, Pidlaoan V, Kondur A, Jacob S, Khetarpal V. Acute myocarditis: can novel echocardiographic techniques assist with diagnosis? *Eur J Echocardiogr*. 2010;11:E5. doi: 10.1093/ejehocardi/jep183. PubMed PMID: 19939815.
- 11 Hor KN, Baumann R, Pedrizzetti G, Tonti G, Gottliebson WM, Taylor M, et al. Magnetic resonance derived myocardial strain assessment using feature tracking. *J Vis Exp*. 2011. doi: 10.3791/2356. PubMed PMID: 21372778; PubMed Central PMCID: PMC3074463.
- 12 Reant P, Labrousse L, Lafitte S, Bordachar P, Pillois X, Tariosse L, et al. Experimental validation of circumferential, longitudinal, and radial 2-dimensional strain during dobutamine stress echocardiography in ischemic conditions. *J Am Coll Cardiol*. 2008;51:149-57. doi: 10.1016/j.jacc.2007.07.088. PubMed PMID: 18191740.
- 13 Cimino S, Canali E, Petronilli V, Cicogna F, De Luca L, Francone M, et al. Global and regional longitudinal strain assessed by two-dimensional speckle tracking echocardiography identifies early myocardial dysfunction and transmural extent of myocardial scar in patients with acute ST elevation myocardial infarction and relatively preserved LV function. *Eur Heart J Cardiovasc Imaging*. 2013;14:805-11. doi: 10.1093/ehjci/jes295. PubMed PMID: 23258316.
- 14 Taylor MD, Hor KN, Mazur W, Benson DW, Gottliebson WM. Right ventricular strain in patients with tetralogy of Fallot. *Journal of Cardiovascular Magnetic Resonance*. 2011;13:1-2. doi: 10.1186/1532-429X-13-S1-P204.
- 15 Orwat S, Kempny A, Diller GP, Bauerschmitz P, Bunck A, Maintz D, et al. Cardiac magnetic resonance feature tracking: a novel method to assess myocardial strain. Comparison with echocardiographic speckle tracking in healthy volunteers and

- in patients with left ventricular hypertrophy. *Kardiol Pol.* 2014;72:363-71. doi: 10.5603/KP.a2013.0319. PubMed PMID: 24293146.
- 16 Steinmetz M, Alt S-C, Kutty S, Sohns JM, Unterberg-Buchwald C, Paul T, et al. Quantification of intra and inter-ventricular dyssynchrony in Ebstein's anomaly using cardiovascular magnetic resonance myocardial feature tracking. *Journal of Cardiovascular Magnetic Resonance.* 2014;16:1-2. doi: 10.1186/1532-429X-16-S1-O108.