

Suprapubic Fecal Fistula Due To Richter's Inguinal Hernia: A Case Report and Review of Literature

Shahbaz Habib Faridi¹, MS; Bushra Siddiqui², MD; Mohd Amanullah Khan¹, MS, FICS; Afzal Anees¹, MS, FICS; Syed Asmat Ali¹, MS, MRCS

Abstract

We encountered a 55-year-old man, who presented with an orifice in the suprapubic region, through which fecal material was discharged. On physical examination, the patient was unstable. After resuscitation, thorough evaluation, and laboratory and imaging investigations, he underwent an exploratory laparotomy. The ileum was entrapped at the deep inguinal ring, and there was some pus in the pelvic cavity. The purulent material was cleaned, and anastomosis was done after the resection of the defective ileal segment. In view of the rarity of this presentation and the paucity of published articles, this case is reported here.

Please cite this article as: Habib Faridi Sh, Siddiqui B, Amanullah Khan M, Anees A, Ali SA. Suprapubic Fecal Fistula Due To Richter's Inguinal Hernia: A Case Report and Review of Literature. *Iran J Med Sci.* 2013;38(2): 129-131.

Keywords • Inguinal ring • Hernia • Cellulitis

Introduction

A Richter's hernia is a type of hernia in which only a part of the circumference of the bowel is entrapped and strangulated in the hernial orifice, leading to ischemia, gangrene, and perforation of the hollow viscus.¹ The portion of the bowel which is usually involved is the distal ileum; however, any part of the intestinal tract, from the stomach to the colon, may become incarcerated. A Richter's hernia occurs when the size of the hernial orifice is large enough to entrap the partial circumference of the bowel wall, but it should be small enough to prevent protrusion of a loop of the intestine, and there should be a firm margin of the hernial ring. A Richter's hernia progresses more rapidly to gangrene due to compromised blood supply. This may be explained by the firm constricting ring that exerts direct pressure on the bowel wall. When less than two thirds of the circumference of the bowel wall is involved, the signs and symptoms of intestinal obstruction are absent. This leads to late diagnosis or even misdiagnosis, and thus it allows bowel necrosis to develop.

The common sites of Richter's hernias are the femoral ring and at trocar sites after laparoscopic procedures.² The trocar site is closed routinely nowadays to prevent the development of hernia.

Unusual occurrences are at the insertion site of the drainage tube following open abdominal surgery, as a Spigelian's hernia, through the sacral foramen. A spontaneous fecal fistula is an extremely rare complication in a long standing abdominal wall hernia.³

This 55-year-old male patient with unnoticed inguinal hernia presented to us with a complication (fecal fistula) as a first symptom. In view of the extreme rarity of this presentation of an inguinal hernia, a case report pertaining to a spontaneous fecal

¹Department of Surgery, Jawaharlal Nehru Medical College, Aligarh Muslim University, Aligarh, Uttar Pradesh, India;

²Department of Pathology, Jawaharlal Nehru Medical College, Aligarh Muslim University, Aligarh, Uttar Pradesh, India

Correspondence:

Shahbaz Habib Faridi, MS;
Department of Surgery,
C/o Prof Muzaffer Ahmed Siddiqui,
4/1308, New S.S. Nagar,
PIN Code 202002; Aligarh,
Uttar Pradesh, India.
Tel: +91 98 97127431
Fax: +91 57 12721127
Email: shahbazfaridi@yahoo.com

Received: 21 April 2012

Revised: 2 June 2012

Accepted: 15 July 2012

fistula in an adult is presented here.

Case Report

A 55-year-old man presented to the emergency department of J.N. Medical College in February 2012, with a history of discharge of fecal matter along with pain and redness at the left extreme of the suprapubic region of 5 days' duration (figures 1 and 2). There was no history suggestive of an inguinal hernia in the past, and nor was there a history of any type of surgical intervention.

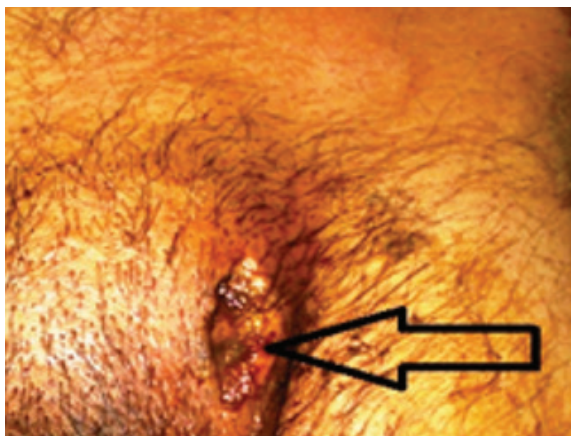

Figure 1: fecal fistula in the left suprapubic region.

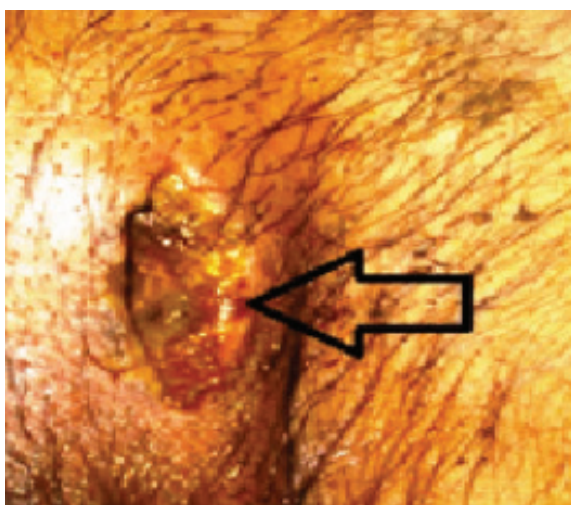


Figure 2: The fecal fistula in the left suprapubic region (2)

On examination, the patient was in shock with a blood pressure of 80/56 mm Hg. His hemoglobin was 8% gm. There was tenderness in the left iliac fossa and left suprapubic region. Ultrasonography of the whole abdomen was suggestive of echogenic collection in the pelvis. Radiographs of the chest and abdomen were normal.

Midline emergency exploratory laparotomy was performed after resuscitation of the patient. Intraoperatively, the partial circumference of a segment of the terminal ileum, about 2 feet from the ileocecal junction, was adhered to the deep

inguinal ring; and when it was separated from the deep inguinal ring, there was a perforation in the ileum (one cm in diameter) (figure 3). About 100 ml of pus was present in the peritoneal cavity. Resection and anastomosis of the involved segment with proximal diverting stoma in the right iliac fossa was performed.

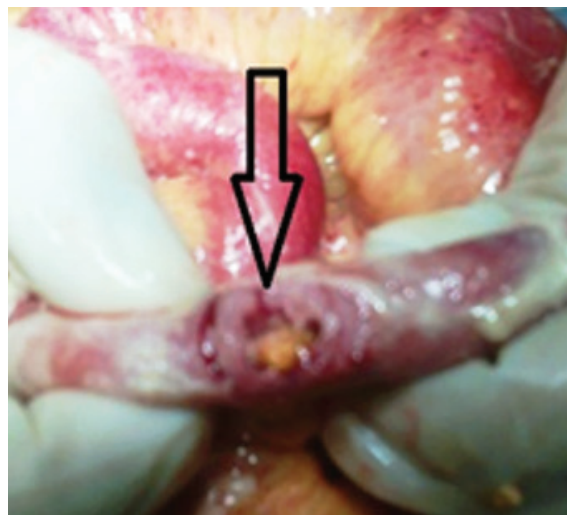


Figure 3: Perforation in the terminal ileum when it was separated from the deep inguinal ring.

Thorough washing of the peritoneal cavity was done, and a single abdominal drain was placed in the pelvis. The diagnosis of a strangulated Richter's hernia at the deep inguinal ring was confirmed.

As there was cellulitis involving the inguinal canal, it was laid open and later on, daily cleaning and dressing was done. Secondary suturing was done after 2 weeks, when the wound was healthy. The patient was discharged in a satisfactory condition, and stoma closure was done after 6 weeks. Follow-up was uneventful.

Discussion

In 1598, Fabricius Hildanus¹ reported the earliest known case of a Richter's hernia. Richter's hernia is named after the German surgeon, August Gottlieb Richter, who gave the first description of this type of hernia in 1778.

In 1986, Horbach found 45 Richter's hernias among 146 strangulated hernias. Among 45 patients with Richter's hernias, he found necrosis of the bowel wall in 31 patients; and among 101 ordinary strangulated hernias, he found bowel necrosis in only 25 patients.⁴

Majority of fecal fistulae occur because of surgical intervention. The development of spontaneous scrotal fecal fistulae secondary to incarcerated inguinal hernias is much rarer among the adult population as compared to the

pediatric age group. Most of these spontaneous fecal fistulae have been reported from developing countries like India and Nigeria.⁵

Onakpoya et al.⁶ from Nigeria reported the case of a neglected Richter's inguinal hernia presenting with perforation and Fournier's gangrene. Three cases of spontaneous perforation of Richter's inguinal hernia with Fournier's gangrene were reported by Guzzo et al.⁷ in 2007 from the United States of America.

A case of port site Richter's hernia presenting with intestinal obstruction following laparoscopic surgery for the inguinal hernia was reported by Wegener et al.⁸ from the United States of America.

Fecal fistulae may also result from the placement of a prosthetic material in the peritoneal cavity.⁹ Leslie et al.¹⁰ from the United Kingdom reported the case of a spontaneous fecal fistula secondary to a Littre's hernia. Repeated treatment of scrotal hernias by native doctors has also been reported as a cause of multiple urinary and fecal fistulae in one study from Nigeria.¹¹

Our case report of a 55-year-old man with no prior history suggestive of an inguinal hernia emphasizes that inguinal hernia can present with complications without any preceding symptoms like groin swelling.

Conclusion

From this study, we conclude that Richter's hernia is prone to strangulation, ischemia, gangrene, and bowel perforation. Also, no history of an inguinal hernia was evident in this case; consequently, an inguinal hernia may present firstly by a hollow viscus fistula.

Conflict of Interest: None declared.

References

- 1 Steinke W, Zellweger R. Richter's hernia and Sir Frederick Treves: an original clinical experience, review, and historical overview. *Ann Surg.* 2000;232:710-8. doi: 10.1097/00000658-200011000-00014. PubMed PMID: 11066144; PubMed Central

PMCID: PMC1421226.

- 2 Boughey JC, Nottingham JM, Walls AC. Richter's hernia in the laparoscopic era: four case reports and review of the literature. *Surg Laparosc Endosc Percutan Tech.* 2003;13:55-8. doi: 10.1097/00129689-200302000-00014. PubMed PMID: 12598762.
- 3 Samad A, Sheikh GM. Spontaneous fecal fistula: a rare presentation of inguinal hernia. *J Ayub Med Coll Abbottabad.* 2005;17:77-9. PubMed PMID: 16599044.
- 4 Horbach JM. Invagination for Richter-type strangulated hernias. *Trop Doct* 1986;16:163-8. PubMed PMID: 3775845.
- 5 Rattan KN, Garg P. Neonatal scrotal faecal fistula. *Pediatr Surg Int.* 1998;13:440-1. doi: 10.1007/s003830050363. PubMed PMID: 9639641.
- 6 Onakpoya UU, Lawal OO, Onovo OD, Oribabor FO. Fournier's gangrene complicating ruptured Richter's inguinal hernia. *West Afr J Med.* 2007;26:316-8. doi: 10.4314/wajm.v26i4.28334. PubMed PMID: 18705434.
- 7 Guzzo JL, Bochicchio GV, Henry S, Keller E, Scalea TM. Incarcerated inguinal hernia in the presence of Fournier's gangrene: a novel approach to a complex problem. *Am Surg.* 2007;73:93-5. PubMed PMID: 17249467.
- 8 Wegener ME, Chung D, Crans C, Chung D. Small bowel obstruction secondary to incarcerated Richter's hernia from laparoscopic hernia repair. *J Laparoendosc Surg.* 1993;3:173-6. doi: 10.1089/lps.1993.3.173. PubMed PMID: 8518473.
- 9 Klein AM, Banever TC. Enterocutaneous fistula as a postoperative complication of laparoscopic inguinal hernia repair. *Surg Laparosc Endosc.* 1999;9:60-2. PubMed PMID: 9950132.
- 10 Leslie MD, Slater ND, Smallwood CJ. Small bowel fistula from a Littre's hernia. *Br J Surg.* 1983;70:244. doi: 10.1002/bjs.1800700421. PubMed PMID: 6831182.
- 11 Udofot SU. Multiple faecal and urinary fistulae as a complication of native treatment of inguinal hernia. *Trop Geogr Med.* 1991;43:105-7. PubMed PMID: 1750097.