

# Ellis-van Creveld with an Unusual Dental Anomaly: A Case Report

Suzanne Tanya Nethan, MDS;  
Shruti Sinha, MDS;  
Sunira Chandra, MDS

Department of Oral Medicine and  
Radiology, Saraswati Dental College,  
Lucknow, Uttar Pradesh, India

## Correspondence:

Suzanne Tanya Nethan, MDS;  
C201 Santushti Apartments,  
7A Vivekanand Marg, Lucknow,  
Uttar Pradesh, 226001, India  
Tel: +91 94 53013152, +91 80 52005703  
Email: [suzanne.nethan@gmail.com](mailto:suzanne.nethan@gmail.com)  
Received: 14 June 2016  
Revised: 02 July 2016  
Accepted: 17 July 2016

## Abstract

The Ellis-van Creveld (EVC) syndrome is a chondroectodermal dysplasia and is characterized by the cardinal features of disproportionate short stature, polydactyly, hidrotic ectodermal dysplasia, and congenital heart malformations, along with other skeletal and dental abnormalities. It is a rare condition, with very few cases reported in the medical literature. It is inherited as an autosomal recessive disorder with variable expressions, due to the mutation of the EVC syndrome 1 and 2 genes, which are located on chromosome 4p16. The present case report describes the EVC syndrome in a 14-year-old girl, who presented with a tetrad of all the cardinal features and other associated features. Additional unusual dental findings such as single-rooted funnel-shaped molars, reduced crown size, enamel hypoplasia, supernumerary teeth, dental fusion, taurodontism, abnormal occlusal anatomy with wide grooves, and atypical cusps have been reported in most previous cases of this syndrome. However, in our patient, surprisingly, the teeth present were relatively non-anomalous, both clinically and radiographically (i.e., with none of the usually found abnormalities mentioned above). The only abnormal dental findings were those of absent maxillary and mandibular incisors (including impacted permanent incisors) and mild malocclusion, a novel point of this case.

Please cite this article as: Nethan ST, Sinha S, Chandra S. Ellis-van Creveld with an Unusual Dental Anomaly: A Case Report. *Iran J Med Sci.* 2017;42(5):501-504.

**Keywords** • Syndrome • Dwarfism • Polydactyly • Ectodermal dysplasia • Cardiac defect

## What's Known

- Additional unusual dental findings such as single-rooted funnel-shaped molars, reduced crown size, enamel hypoplasia, supernumerary teeth, dental fusion, dysmorphic roots, taurodontism, abnormal occlusal anatomy with wide grooves, and atypical cusps have been reported in most previous cases of the Ellis-van Creveld syndrome.

## What's New

- However, in our patient, surprisingly the teeth present were non-anomalous, both clinically and radiographically (i.e. with none of the above-mentioned common abnormalities). The only abnormal dental findings were those of absent maxillary and mandibular incisors (including impacted permanent incisors) and mild malocclusion.

## Introduction

The Ellis-van Creveld (EVC) syndrome is an autosomal recessive disorder, mainly characterized by short height, polydactyly, ectodermal dysplasia, and congenital cardiac defects.<sup>1</sup> For a definitive diagnosis, usually 3 out of the 4 cardinal features must be present.<sup>2</sup> It is a result of mutations in the EVC syndrome 1 and 2 genes on chromosome 4p16 and is a relatively rare disease with approximately 150 cases reported worldwide (more prevalent among the Amish community).<sup>3</sup>

## Case Presentation

A 14-year-old female patient reported to the department of oral medicine and radiology, dental college, on October 9, 2014, with the chief complaint of missing upper and lower front teeth since childhood. There was history of the presence of a natal maxillary anterior tooth, which exfoliated spontaneously within 10 to 15 days of birth, followed by non-eruption of both deciduous and

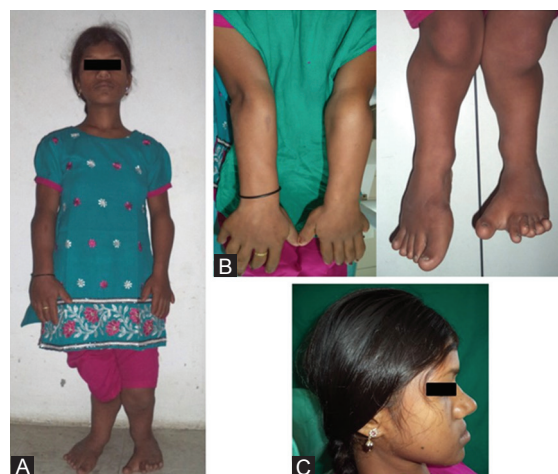permanent maxillary and mandibular anterior teeth. However, the teeth in other regions erupted normally.

The patient's family history revealed the birth of 2 female children previously, who also presented with 2 maxillary anterior natal teeth each and similar abnormal findings (multiple extra digits), and death within 15 days of birth.

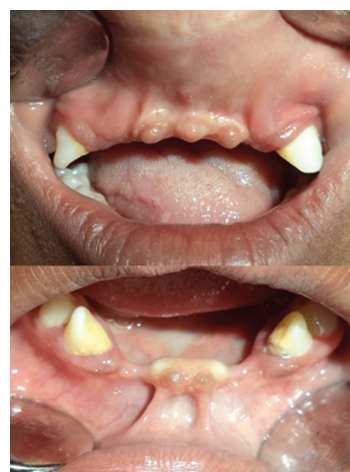The patient was of short stature (117.5 cm), mesomorphic (in proportion to her height, weighing 28 kg) and had a relatively narrow thorax (figure 1A). Both upper and lower limbs showed progressive shortening from the proximal to the distal portions, with bowing of the arms and legs and development of "knock-knees" (genu valgum), with the absence of hair on the arms and legs; there was, however, no insufficiency or absence of the same in relation to the head, eyebrows, eyelashes, and pubic and axillary regions (figure 1B). The digits of both hands and the great toe of the right foot were clinodactyl; the digits of both hands were also "sausage-shaped" (figure 1B). Postaxial polydactyly (hexadactyly) was seen in relation to both hands and left foot, and all the nails (of both upper and lower extremities) were short and dystrophic (figure 1B). Extraoral examination revealed a normal head morphology with mild maxillary hypoplasia with resultant relative mandibular prognathism (figure 1C).

Intraoral examination revealed multiple accessory maxillary and mandibular labial frenula with upper (class III) and lower lip tie along with the absence of the mucobuccal fold with the resultant reduced sulcus depth in the maxillary and mandibular labial sulcus region (figure 2). Also, multiple longitudinal serrations, traversing the width of the maxillary and mandibular anterior alveolar ridges, could be appreciated (figure 2). Both maxillary and mandibular incisors were found to be missing (figure 2). During occlusion, the molars on the right side displayed an edge-to-edge relation, while those on the left displayed cross-bite. Based on these multiple clinical features, a provisional diagnosis of the EVC syndrome was given.

Thereafter, numerous radiographic investigations were carried out for the patient, comprised of orthopantomography and lateral cephalography, along with radiography of the upper and lower limbs and a posteroanterior view of the chest. The orthopantomograph revealed the absence of maxillary and mandibular incisors with the absence of developing/developed permanent teeth buds of the same. The lateral cephalogram confirmed the hypoplasia of the mid-facial region along with

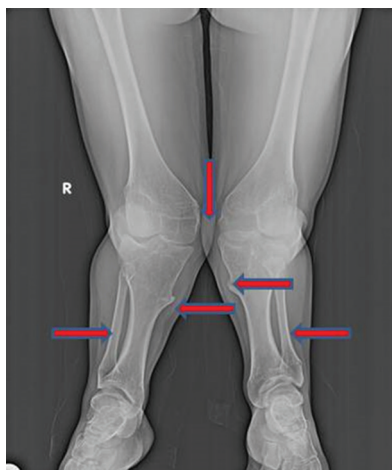


**Figure 1:** Shows general features of the patient. A) Short stature, mesomorphism, and narrow thorax. B) Upper and lower limbs show progressive shortening (from the proximal to the distal portions), with bowing of the arms and legs and "knock-knees" (genu valgum), along with the absence of hair on the arms and legs. Clinodactyly of the digits of both hands and the great toe of the right foot, sausage-shaped digits of both hands, postaxial polydactyly (hexadactyly) in both hands and left foot, and short and dystrophic nails (of both hands and toes). C) Normal head morphology with mild maxillary hypoplasia and the resultant relative mandibular prognathism.



**Figure 2:** Shows intraoral findings of the patient. Multiple accessory maxillary and mandibular labial frenula with upper (class III) and lower lip tie, absence of the mucobuccal fold and the resultant reduced maxillary and mandibular labial sulcular depth. Multiple longitudinal serrations, traversing the width of the maxillary and mandibular anterior alveolar ridges. Missing maxillary and mandibular incisors.

the associated relative mandibular prognathism. The radiographs of the upper limbs displayed the following features: curving of the humerus bones bilaterally, underdeveloped styloid process of the ulna bilaterally, postaxial polydactyly and clinodactyly bilaterally, hyperplastic capitae of the left wrist, undeveloped metacarpal for the extra digit in the left hand, and hypoplastic hamate of the right wrist. The radiographs of the lower limbs showed the following features: short



**Figure 3:** Shows radiographic findings. Radiograph of the lower limbs displays short tibia (with exostosis) and fibula bones bilaterally and bowed legs with “knock knees” (genu valgum).

tibia (with exostosis) and fibula bones bilaterally (figure 3), bowed legs with “knock knees” (genu valgum) (figure 3), postaxial polydactyly in the left foot with the absence of the terminal phalange in the extra digit, and a clinodactyl right great toe. The narrowing of the thorax and marginal cardiomegaly could be appreciated via the posteroanterior chest radiograph. The cardiac condition of the patient was also analyzed with the help of an ECG, which revealed right atrial and ventricular enlargement and right bundle branch block.

Thus, after thorough examination and multiple investigations, the diagnosis of the EVC syndrome was confirmed.

The patient was then referred to the department of pedodontics for the management of her chief complaint (i.e., for the replacement of the missing maxillary and mandibular incisors). Also, the patient’s written consent was taken in advance, allowing the subsequent reporting of this case on a scientific portal.

## Discussion

The EVC syndrome, a rare genetic disorder, was first described by Richard Ellis and Simon van Creveld in 1940 and is characterized by short stature, polydactyly, ectodermal dysplasia, and congenital heart defects.<sup>4,5</sup> It is more prevalent among the Amish community.<sup>1</sup> Our patient, however, was of Indian origin and resided in the state of Uttar Pradesh.

The EVC syndrome affects multiple organs. Prenatal abnormalities may be discovered as early as after the 18th gestation week, characterized by a narrow thorax, marked shortening of the long bones, hexadactyly

of the hands and feet, and cardiac defects.<sup>5</sup> Postnatally, the following cardinal features (tetrad) of the syndrome are observed: short stature (along with a pattern of progressive shortening of the limbs from their proximal to distal phalanges); polydactyly affecting the hands (usually bilaterally) and occasionally, the feet; ectodermal dysplasia (hidrotic) of the nails, hair, and teeth; and congenital cardiac defects (seen in about 50% to 60% individuals), which mainly affect the longevity of the individual.<sup>6,7</sup> For the diagnosis of the syndrome, 3 out of the 4 cardinal features must be present.<sup>2</sup> Our patient showed all 4 features.

Oral manifestations which may be seen include malocclusion, labi gingival adhesences, gingival hypertrophy, accessory labi gingival frenula, serrated incisal margins, dental transposition, diastema, conical teeth, enamel hypoplasia, hypodontia, and teeth erupted or exfoliated prematurely, which were present in our patient too.<sup>8</sup>

Rarely, additional clinical findings like strabismus, epi- and hypospadias, cryptorchidism, thoracic wall and pulmonary malformations, and renal and hematological abnormalities may be seen; these were, however, absent in our patient.<sup>3</sup>

Various skeletal anomalies can be appreciated radiographically such as delayed bone growth and maturation, clinodactyl 5th finger and/or toe, fused carpals (usually the hamate and capitate), fused 5th and 6th metacarpals, defect on the lateral surface of the proximal part of the tibia (or knock-knees), cubitus valgus, and hypoplastic cubitus, most of which were found in our patient too.<sup>1</sup>

Based on the clinical features (short stature, polydactyly, and orofacial abnormalities), the differential diagnoses of the McKusick Kauffman syndrome, Jeune dystrophy, and Weyers acrofacial dysostosis can be considered. The Jeune dystrophy has no specific constant features, and the McKusick Kaufman syndrome also presents with hydrometrocolpos and is caused by mutations in a gene on chromosome 20p12. Nevertheless, in the Weyers acrofacial dysostosis, features such as disproportionate dwarfism, heart defect, and thoracic dysplasia are absent.<sup>1</sup>

The diagnosis of the EVC syndrome is done based on the history, clinical examination, and skeletal survey of the individual. The direct sequencing of the EVC syndrome 1 and 2 genes may also be performed. Prenatally, ultrasonography can be utilized for diagnosis.<sup>1</sup>

The management of this syndrome involves a multidisciplinary approach (e.g., managing

the symptoms by treating respiratory distress due to narrow chest and heart failure, removing the neonatal teeth which may impair feeding, providing general and specialized pediatric care later, and regular orthopedic follow-up due to the higher possibility of bone deformity). Dentists play an important role in the control of the dental and oral manifestations. Before dental treatment, prophylaxis with antibiotics must be carried out to prevent any complications in patients with the EVC syndrome with cardiac malformations.

### Conclusion

Additional unusual dental findings such as single-rooted funnel-shaped molars, reduced crown size, enamel hypoplasia, supernumerary teeth, dental fusion, taurodontism, abnormal occlusal anatomy with wide grooves, and atypical cusps have been reported in most previous cases of this syndrome. However, in our patient, surprisingly, the teeth present were relatively non-anomalous, both clinically and radiographically (i.e., with none of the usually found abnormalities mentioned above). The only abnormal dental findings were those of absent maxillary and mandibular incisors (including impacted permanent incisors) and mild malocclusion, a novel point of this case. We have, thus, presented an unusual case of this extremely rare syndrome.

**Conflict of Interest:** None declared.

### References

1. Baujat G, Le Merrer M. Ellis-van Creveld syndrome. *Orphanet J Rare Dis.* 2007;2:27. doi: 10.1186/1750-1172-2-27. PubMed PMID: 17547743; PubMed Central PMCID: PMC1891277.
2. Ferrero NA, Pozo OO, Morresi ES. Chondro-Ectodermal Dysplasia (Ellis-van Creveld Syndrome). *JBJS Case Connector.* 1961;43:1230-6.
3. McKusick VA. Ellis-van Creveld syndrome and the Amish. *Nat Genet.* 2000;24:203-4. doi: 10.1038/73389. PubMed PMID: 10700162.
4. Vinay C, Reddy RS, Uloopi KS, Sekhar RC. Clinical manifestations of Ellis-van Creveld syndrome. *J Indian Soc Pedod Prev Dent.* 2009;27:256-9. doi: 10.4103/0970-4388.57663. PubMed PMID: 19915279.
5. Horigome H, Hamada H, Sohda S, Oyake Y, Kurosaki Y. Prenatal ultrasonic diagnosis of a case of Ellis-van Creveld syndrome with a single atrium. *Pediatr Radiol.* 1997;27:942-4. doi: 10.1007/s002470050277. PubMed PMID: 9388288.
6. Blackburn MG, Belliveau RE. Ellis-van Creveld syndrome. A report of previously undescribed anomalies in two siblings. *Am J Dis Child.* 1971;122:267-70. PubMed PMID: 5568596.
7. Digilio MC, Marino B, Ammirati A, Borzaga U, Giannotti A, Dallapiccola B. Cardiac malformations in patients with oral-facial-skeletal syndromes: clinical similarities with heterotaxia. *Am J Med Genet.* 1999;84:350-6. PubMed PMID: 10340650.
8. Winter GB, Geddes M. Oral manifestations of chondroectodermal dysplasia (Ellis-Van Creveld Syndrome). Report of a case. *Br Dent J.* 1967;122:103-7. PubMed PMID: 5226625.