

Balanced Reciprocal Translocation t(X;1) in a Girl with Tall Stature and Primary Amenorrhea

Zahra Razavi, MD;
Hossein Emad Momtaz, MD

Department of Pediatrics, Besat
Hospital, Hamadan University of Medical
Sciences, Hamadan, Iran

Correspondence:

Hossein Emad Momtaz, MD;
Department of Pediatrics, Besat
Hospital, Motahari Boulevard,
Hamadan, Iran

Tel: +98 918 3339843

Fax: +98 81 32640064

Email: hemmtz@yahoo.com

Received: 8 June 2015

Revised: 27 October 2015

Accepted: 22 November 2015

Abstract

Chromosomal translocations constitute one of the most important, yet uncommon, causes of primary amenorrhea and gonadal dysgenesis. Although X-autosome translocations are frequently associated with streak gonads and clinical features of the Turner syndrome, the majority of X-autosome carriers may present with a variable phenotype, developmental delay, and recognizable X-linked syndrome due to nonrandom X-inactivation. In this article, we describe a healthy 15.5-year-old girl with primary amenorrhea, gonadal dysgenesis, and tall stature without other manifestations of the Turner syndrome. Relevant clinical, biochemical, endocrinological, and cytogenetical evaluations were performed. Initial investigations revealed hypergonadotropic hypogonadism (FSH=134 mIU/mL [normal=10–15 mIU/mL], LH=47.5 [normal=10–15 mIU/mL], and estradiol=24.3 pmol/L). On ultrasound examination of the pelvis, streak ovaries with a hypoplastic uterus were noted. Chromosome study, performed according to routine procedures, revealed an apparently balanced reciprocal translocation involving the short arm of chromosome 1(p2) and the long arm of the X chromosome (q2) in all the cells with the following karyotype: 46,X,t(1;X)(p13;q22). She was placed on hormone replacement therapy. In our patient, X-autosome translocation was associated with gonadal dysgenesis and tall stature. We conclude that t(X;1) may be associated with gonadal dysgenesis without other congenital abnormalities. To our knowledge, normal phenotype with gonadal dysgenesis and tall stature in association with t(X;1) translocation has not been previously reported.

Please cite this article as: Razavi Z, Emad Momtaz H. Balanced Reciprocal Translocation t(X;1) in a Girl with Tall Stature and Primary Amenorrhea. Iran J Med Sci. 2017;42(2):210-214.

Keywords • Genetic translocation • Gonadal dysgenesis
• Turner syndrome

What's Known

- Structural abnormalities of the X chromosome, including X-autosome translocations, are frequently associated with streak gonads and clinical features of Turner's syndrome.
- Most X; autosome carriers may present with a variable phenotype, developmental delay, and recognizable X-linked syndrome due to nonrandom X-inactivation.

What's New

- Tall stature with a normal phenotype may be one of the main clinical features of X chromosome translocation. This symptom has not been previously reported in the literature.

Introduction

Structural abnormalities in the X chromosome are usually associated with the Turner syndrome phenotype. The Turner syndrome is caused by the absence of 1 set of genes from the short arm of 1 X chromosome and presents with characteristic physical abnormalities such as short stature, amenorrhea due to ovarian failure, retruded mandible, ptosis, low hair line, low-set ears, webbed necks, renal structural anomalies, and other congenital malformations usually without mental retardation.¹ However, the most consistent findings with this syndrome are short stature and gonadal dysgenesis. Although X monosomy is

the most frequent chromosomal finding, in some patients with the Turner syndrome the karyotype shows variants of X-chromosome abnormalities such as deletions, duplications, inversions, X/autosomal balanced translocations, and rings.² Thus, the phenotypic features vary significantly among affected individuals.

Translocations involving autosomes and the X chromosome with gonadal dysgenesis have been described by a few studies.^{3,4} Nonetheless, the coexistence of balanced translocation, gonadal dysgenesis, and tall stature in association with t(X;1) translocation has been rarely described in the literature. In this paper, we describe a 15.5-year-old girl with primary amenorrhea, gonadal dysgenesis, and tall stature without dysmorphic features.

Case Presentation

Written consent was obtained from the patient and her parents. A 15.5-year-old girl was referred to the outpatient endocrinology clinic with primary amenorrhea without a significant past medical history. She was the first offspring of non-consanguineous parents. She was born at 38 gestational weeks with a length of 52 cm (+1.5 SD score) and a weight of 2,800 g. Physical examination at birth was unremarkable. No positive family history was noted regarding delayed puberty, primary amenorrhea, and infertility. Her mental development was normal. At the age of 14 years, she was referred to a gynecologist because of delayed puberty. On physical examination, the patient was phenotypically normal. She had proportional tall stature. There were no stigmata of the Turner syndrome. Her weight was 71 kg (90th percentile), her height was 177 cm (height z score +2.5 SD above the 50th percentile of the NCHS growth chart), and her body mass index was 22.68 kg/m². Blood pressure was 115/65 mm Hg. She had female external genitalia. The patient did not attain breast pubertal development, and the pubic hair was at stage 3 according to the Tanner staging. Bone age was 13.5 years. Final height prognosis was 183.0 cm, according to the method of Bailey and Pinneau.⁵ Initial investigations revealed hypergonadotropic hypogonadism FSH=134 mIU/mL [normal=10–15 mIU/mL], LH=47.5 [normal=10–15 mIU/mL], and estradiol=24.3 pmol/L. T4, TSH, prolactin, and liver enzymes were all normal. On ultrasound examination of the pelvis, streak ovaries with a hypoplastic uterus (measuring 4.4×2.4×1.5 cm) were noted. Kidney ultrasound and echocardiogram were normal. Chromosomal analysis was

performed on the patient according to standard cytogenetical procedures. Cytogenetical study of 25 conventionally stained metaphases from 450-band resolution on the basis of GTG-banding technique revealed an apparently balanced reciprocal translocation involving the short arm of chromosome 1(p2) and the long arm of the X chromosome (q2) in all the cells with the following karyotype: 46,X, t(1; X)(p13;q22) (figure 1). Given the patient's age, estrogen replacement therapy was started. Breast development was initiated with 0.6 mg of exogenous conjugated estrogens per day. Then, continuous low-dose estrogen was cycled in a 3-week-on/1-week-off regimen. Medroxyprogesterone acetate (5 mg daily) for 12 days each month was prescribed 7 months after estrogen therapy when vaginal spotting occurred. This treatment was effective in inducing regular withdrawal bleeding. She has been continued on hormone replacement therapy.

Discussion

We present a variant of the X-autosome translocation of the Turner syndrome in a 15.5-year-old girl with primary amenorrhea, gonadal dysfunction, and tall stature not associated with the phenotypic abnormalities of this syndrome. A few cases with reciprocal translocations and structural abnormalities of the X chromosome have been previously reported by other investigators.^{6,7} Nevertheless, to the best of our knowledge, this is the first known report of a balanced translocation involving 1;X in a phenotypically normal girl with primary amenorrhea and tall stature.

In normal female fetuses with 2 large gene-rich X chromosomes, random X-inactivation occurs in somatic cells early in embryogenesis and, therefore, transcriptionally silences the majority of the genes on 1 of the 2 X chromosomes (Lyon 1961). The clinical consequences of having 1 normal and 1 structurally defective X chromosomes may result in the deleterious expression of X chromosome genes, which are normally silenced or inactivated in the second X chromosome (known to escape inactivation on normal inactive X chromosomes). Structural sex chromosome rearrangements are generally without obvious significant clinical conditions due to the preferential inactivation of the abnormal X, which can contribute to a balanced genetic arrangement. Even so, patients who carry X-autosome translocations face significantly higher facial dysmorphism, mental retardation, multiple congenital abnormalities, or acquired abnormalities than those with

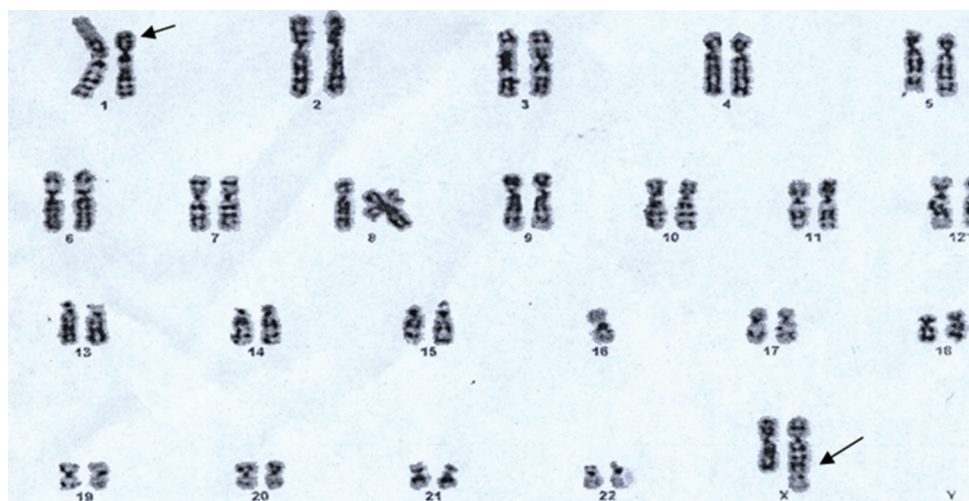


Figure 1: Karyotype shows a balanced reciprocal translocation between the short arm of chromosome 1 and the long arm of chromosome X:46,X,t(1;X)(p13;q22).

the Turner syndrome.⁷ These abnormal phenotypes can be ascribed to the escape from X-inactivation or the partial X-inactivation of an abnormal X chromosome. Many features of X-chromosome structural abnormalities such as short stature arise from haploinsufficiency in the short stature homeobox-containing gene (*SHOX*),^{3,4,7} whereas candidate genes for the control of normal ovarian function are postulated to be on Xp. However, additional studies have demonstrated that 2 other genes on Xq are also involved in normal ovarian function.⁸ Since the 2 copies of the X chromosome are necessary for ovarian development and integrity, the gonadal dysgenesis in our patient can be attributed to the partial loss of Xq, which contains various genes necessary for a normal ovarian reproductive function.⁹ The tall stature in our patient is noteworthy. In line with previous case reports by other authors, one possible explanation for our patient's tall stature is estrogen deficiency caused by untreated gonadal dysgenesis because gonadal estrogen deficiency contributes to sustained growth.¹⁰ The other explanation may be the presence of a second intact *SHOX*. With respect to tall stature, our literature review yielded a few similar cases. Seo et al.⁶ (2015) described a Korean patient with the Turner syndrome with primary amenorrhea and tall stature caused by *SHOX* overdosage. Binder et al.¹¹ (2001) described a tall 14-year-old girl with gonadal dysgenesis and some stigmata of the Turner syndrome due to the duplication of the short arm in a monocentric X chromosome with the partial loss of Xq. Ogata et al.¹⁰ (2002) identified a female patient with 45,X[40]/46,X,der(X), primary amenorrhea, and tall stature and confirmed that she had duplication in roughly the distal half of Xp, including *SHOX* and deletion

of most of Xq. The authors proposed that tall stature in the described patient was caused by the combined effects of *SHOX* duplication on the der(X) chromosome and gonadal estrogen deficiency. Considering t(1;X) in our patient, we reviewed similar reported cases in the literature. Tullu et al.⁸ (2001) described an 18-year-old female patient with primary amenorrhea who was found to have balanced autosomal translocations 46XX,t(1;11)(q31;q25). Waters et al.¹² (2001) carried out a retrospective survey on 104 patients with X-autosome translocations from different laboratories in the UK during a 15-year period (1983–1997) and found 5 cases with t(X;1) presenting with various clinical features such as recurrent miscarriages, learning difficulties, and multiple congenital anomalies/developmental delays (table 1). A point to note is that none of the reported patients was tall. Consistent with our study, Venkateshwari et al.¹³ (2015) reported a balanced sex autosome translocation t(X;1)(q21;p32) in a female patient who presented with primary amenorrhea without dysmorphic features or developmental delay. She was found to have a hypoplastic uterus and streak gonads with normal biochemical and hormonal study. In contrast to our patient, however, she was not tall. Apart from tall stature, our findings are broadly consistent with those in the study by Venkateshwari et al. Overall, it can be assumed that normal phenotype, lack of short stature, or other stigmata of the Turner syndrome in our patient may have been caused by the intact presence of a second *SHOX* gene on the short arm of an X chromosome. Our data are consistent with the findings of the study by Venkateshwari et al.,¹³ who hypothesized that the effect of X;1 translocation might be limited to ovarian anatomy and function.

Table 1: Previously reported cases of balanced X;1 translocations

Symptoms	Karyotypes	Data by
Developmental delay	46, X, t (X; 1)(p22.1;p31) <i>de novo</i>	Waters et al. ¹² (2001)
Recurrent miscarriages	46, X, t (X; 1)(p22.1;p32) <i>de novo</i>	
Learning difficulties	46, X, t (X; 1)(p11.4;p36.3) <i>de novo</i>	
Mother: abnormal scan	46, X, t (X; 1)(q26;p22) <i>de novo</i>	
Multiple congenital anomalies/developmental delay	46, X, t (X; 1)(q26;p22) <i>mat</i>	
Primary amenorrhea	46X: t (X; 1) (q21;p32)	Venkateshwari et al. ¹³ (2015)

To summarize, most of the patients previously described had translocations between the X chromosome and autosomes 4, 6, 9, 12, 15, and 18.⁸ Our report emphasizes the clinical presentation of a balanced reciprocal translocation t(X;1). This abnormality was associated with ovarian dysgenesis but an otherwise normal female phenotype. Here, we propose that the X;1 translocation effect is rarely evident in prepubertal girls as there are no physically obvious stigmata.

Acknowledgment

We gratefully thank Dr. Mohammad Jafari and Safiye Ghahremani for the cytogenetical analysis of the case reported. We thank the patient and her family for participation in this study.

Conflict of Interest: None declared.

References

- Leppig KA, Disteche CM. Ring X and other structural X chromosome abnormalities: X inactivation and phenotype. *Semin Reprod Med.* 2001;19:147-57. doi: 10.1055/s-2001-15395. PubMed PMID: 11480912.
- Marozzi A, Manfredini E, Tibiletti MG, Furlan D, Villa N, Vegetti W, et al. Molecular definition of Xq common-deleted region in patients affected by premature ovarian failure. *Hum Genet.* 2000;107:304-11. doi: 10.1007/s004390000364. PubMed PMID: 11129329.
- Vasu VR, Chandra N, Santhiya ST. X;7 translocation in an Indian woman with hypergonadotropic amenorrhea-a case report. *Genet Test Mol Biomarkers.* 2009;13:533-6. doi: 10.1089/gtmb.2009.0051. PubMed PMID: 19663602.
- Sills ES, Cotter PD, Marron KD, Shkrobot LV, Walsh HM, Salem RD. Ovarian dysgenesis associated with an unbalanced X;6 translocation: first characterisation of reproductive anatomy and cytogenetic evaluation in partial trisomy 6 with breakpoints at Xq22 and 6p23. *Mol Med Rep.* 2012;5:29-31. doi: 10.3892/mmr.2011.589. PubMed PMID: 21931936.
- Bayley N, Pinneau SR. Tables for predicting adult height from skeletal age: revised for use with the Greulich-Pyle hand standards. *J Pediatr.* 1952;40:423-41. doi: 10.1016/S0022-3476(52)80205-7. PubMed PMID: 14918032.
- Seo GH, Kang E, Cho JH, Lee BH, Choi JH, Kim GH, et al. Turner syndrome presented with tall stature due to overdosage of the SHOX gene. *Ann Pediatr Endocrinol Metab.* 2015;20:110-3. doi: 10.6065/apem.2015.20.2.110. PubMed PMID: 26191517; PubMed Central PMCID: PMC4504991.
- Bouayed Abdelmoula N, Portnoi MF, Amouri A, Arladan A, Chakroun M, Saad A, et al. Turner syndrome female with a small ring X chromosome lacking the XIST, an unexpectedly mild phenotype and an atypical association with alopecia universalis. *Ann Genet.* 2004;47:305-13. doi: 10.1016/j.anngen.2004.03.008. PubMed PMID: 15337477.
- Tullu MS, Arora P, Parmar RC, Muranjan MN, Bharucha BA. Ovarian dysgenesis with balanced autosomal translocation. *J Postgrad Med.* 2001;47:113-5. PubMed PMID: 11832602.
- Lissoni S, Baronchelli S, Villa N, Lucchini V, Betri E, Cavalli P, et al. Chromosome territories, X;Y translocation and Premature Ovarian Failure: is there a relationship? *Mol Cytogenet.* 2009;2:19. doi: 10.1186/1755-8166-2-19. PubMed PMID: 19781104; PubMed Central PMCID: PMC2761935.
- Ogata T, Inokuchi M, Ogawa M. Growth pattern and body proportion in a female with short stature homeobox-containing gene overdosage and gonadal estrogen deficiency. *Eur J Endocrinol.* 2002;147:249-54. doi: 10.1530/eje.0.1470249. PubMed PMID: 12153748.
- Binder G, Eggermann T, Enders H, Ranke MB, Dufke A. Tall stature, gonadal dysgenesis, and stigmata of Turner's

- syndrome caused by a structurally altered X chromosome. *J Pediatr.* 2001;138:285-7. doi: 10.1067/mpd.2001.110277. PubMed PMID: 11174634.
12. Waters JJ, Campbell PL, Crocker AJ, Campbell CM. Phenotypic effects of balanced X-autosome translocations in females: a retrospective survey of 104 cases reported from UK laboratories. *Hum Genet.* 2001;108:318-27. doi: 10.1007/s004390100465. PubMed PMID: 11379878.
13. Venkateshwari A, Srilekha A, Veena K, Sujatha M, Jyothy A. A Rare De Novo Balanced X; 1 Translocation in an Indian Female with Primary Amenorrhea. *J Reprod Infertil.* 2015;16:171-3. PubMed PMID: 26913237; PubMed Central PMCID: PMC4508357.