

Creutzfeldt-Jacob Disease in an Iranian Patient Confirmed By Brain Autopsy

K. Nikkhah, M. Saiedi, R. Sadrenabavi,
E. Poorakbar

Abstract

Creutzfeldt-Jacob disease is the most common form of prion diseases, which have become public health problems in the last two decades because of the high number of reported cases of mad cow disease in Great Britain and other countries. Creutzfeldt-Jacob disease is a fatal situation with known cardinal clinical features including progressive memory loss and myoclonic seizure disorder. In this report, we present a case of Creutzfeldt-Jacob disease with characteristic clinical signs such as progressive memory loss, myoclonic jerks, and focal and generalized seizures. We also discuss the pathologic findings of the brain autopsy confirmed by Gottingen center (Germany) for spongiform encephalopathy.

Iran J Med Sci 2008; 33(2): 124-126.

Keywords • Creutzfeldt-Jacob disease • prion • pathology

Introduction

In the last years, prion diseases have become public health concerns because of the epidemic of mad cow disease (bovine spongiform encephalopathy) in Great Britain.¹ Prion diseases include several rare conditions such as Creutzfeldt-Jacob disease (CJD) that represents the most common form of such diseases.^{1,2}

Prion is a transmissible virus-like pathogenic agent, however, its molecules do not have any detectable nucleic acid.^{1,3} The CJD occurs throughout the world with an annual incidence of about one per one million people.^{1,3} The average age at the onset of diseases is 60 years in 90% of the patients.^{2,4} The disease is fatal within one year and has no specific treatment.^{5,6}

In this report we present the first case of CJD in Iran that was documented by brain autopsy and confirmed by Gottingen center for spongiform encephalopathy.

Case Report

The patient was a 70-year-old woman who admitted to the neurological emergency ward in 1996 because of lethargy, speech disturbance, generalized weakness, and myoclonic jerks.

In her history, six months before admission, unusual behavior, emotional incontinence, inappropriate crying, recent memory loss, and myoclonic jerks were detected. Medical history of the patient showed ischemic heart disease and atrial fibrillation with no specific treatment.

Routine blood counts and other laboratory examinations were normal. Analysis of the cerebrospinal fluid (CSF) showed no cell, normal glucose concentration (65 mg/dl), and normal protein level (30 mg/dl). Electrocardiography (ECG) showed

Department of Neurology,
Ghaem Hospital,
Mashhad University of Medical Sciences,
Mashhad, Iran.

Correspondence:

Karim Nikkhah MD,
Department of Neurology,
Ghaem Hospital,
Mashhad University of Medical Sciences,
Mashhad, Iran.

Tel: +98 511 8443444

Fax: +98 511 8416655

Email: dr_nikkhah@msn.com

Submitted: 5 February 2007

Revised: 7 May 2007

Accepted: 9 September 2007

signs of atrial fibrillation, ST depression, and T inversion in pericardial leads. Brain computed tomography (CT) demonstrated mild atrophy and a small hypodense lesion in the right parietooccipital region with no contrast enhancement and no mass effect, probably because of an old ischemia. Electroencephalography (EEG) demonstrated diffuse slowing with periodic complexes of sharp and slow waves discharges of 1 to 1.2 per seconds (figure 1), which can be seen in typical cases of CJD.

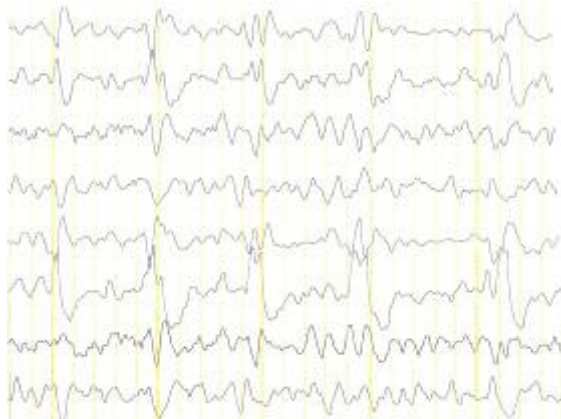

Figure 1: Generalized periodic sharp & slow waves at 1 to 1.2 CPS with diffuse slowing background.

Finally she died due to progressive neurological abnormalities, deteriorated breathing, and probably associated cardiac problems without a significant response to medications and supportive treatment. Brain autopsy of this patient revealed mild atrophy of cerebral cortex with the brain weighted 1200 gr. On microscopic examination, pathologic changes were more prominent in temporal and frontal cortex, including loss of nerve cells, vacuolation of nerve cell bodies (figure 2) and neuropils (status spongiosis) (figure 3).

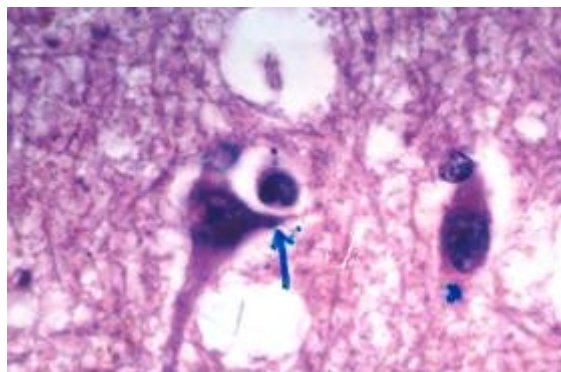


Figure 2: Vacuolation of nerve cell bodies on the cortex of right precentral gyrus (H&E).

The prion protein (prp) plaques were found by immunocytochemistry, although this feature is

more characteristic for natural scrapie in sheep and of kuru.⁸ These findings were confirmed by Gottingen center for spongiform encephalopathy (Germany).

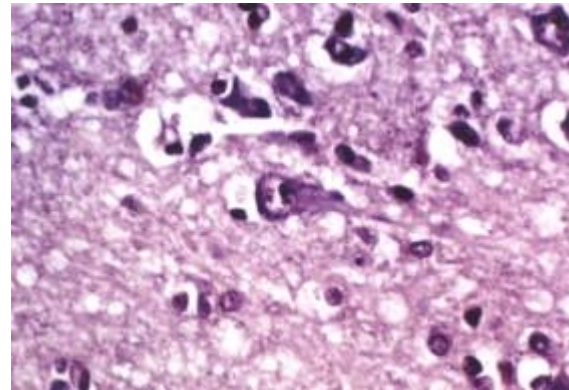


Figure 3: Vacuolation in the Neuropil of cerebral cortex, (status spongiosis) (H&E).

Discussion

Creutzfeldt and Jacob in 1920 and 1921 described a progressive disease of the cortex, basal ganglia, and spinal cord that affected mainly the middle aged individuals.^{4,7} This disease with few other human diseases including Kuru, Gerstman-Straussler syndrome (GSS), and fatal familial insomnia (FFI) with characteristic pathologic changes that led to early designation of spongiform encephalopathy, are now called prion diseases.^{8,9} Among prion diseases, the etiology of CJD is not fully understood. Infection and genetics could be involved in the pathology of the disease, however, 80%-90% of the patients, including the one presented here, are sporadic with unknown mode of transmission. Excluding the corneal transplantation and other rare conditions, human-to-human mode of transmission is quite unlikely.¹⁰

Definitive diagnosis of CJD can only be made by neuropathological findings or immunologic and biochemical examination of the brain.^{11,12}

The age of our patient was 70 that was within the usual age range for CJD (middle or late life), but according to her history of ischemic stroke and ischemic heart disease, we supposed that the patient suffered from a minor stroke. However, the progressing course of the illness and other clinical signs such as myoclonic jerks, focal and generalized seizures and history of unusual behavior for few months, impaired judgment, and memory loss led us to pay attention to other possible diseases such as CJD. In fact our patient had a gradual onset of dementia from few months before admission with a progressive course and other mentioned clinical symptoms.

The routine blood tests, CSF examination, EEG, and neuropathological findings (status spongiosis and loss of neurons), were also typical for CJD.¹² The course of the disease in our patient was fatal in seven months after the onset of the initial clinical symptoms (33 days after admission). However, based on the vascular risk factors and history of vascular events, she was admitted as a patient having stroke, a diagnosis that should be considered as an important presentation of CJD.^{13,14}

Conflict of Interest: None declared

References

- 1 Lewis P. Rowland, Merrit's Neurology, 11 th ed. Lippincott Williams&Wilkins, 2005. p. 265-7.
- 2 Maurice Victor, Allan H. Ropper, Principles of Neurology, 7 th ed. Me Graw-Hill, 2001. p. 813-7.
- 3 Will RG, Alperovitch A, Poser S, et al. Descriptive epidemiology of Creutzfeldt-Jacob disease in six European countries, 1993-1995. EU Collaborative Study Group for CJD. *Ann Neurol* 1998; 48: 763-7.
- 4 Brown P, Gibbs CJ Jr, Rodgress-Johnson P, et al. Human spongiform encephalopathy: The National Institute of Health series of 300 cases of experimentally transmitted disease. *Ann Neurol* 1994; 35: 513-29.
- 5 Berger JR, David NJ. Creutzfeldt-Jacob disease in a physician; a review of the disorder in health care workers. *Neurology* 1993; 43: 205-6.
- 6 Cousens SN, Zeidler M, Esmonde TF, et al. Sporadic Creutzfeldt-Jacob disease in the united kingdom :analysis of epidemiological surveillance data for 1970-96. *BMJ* 1997; 315: 389-95.
- 7 Walter G. Bradley, Robert B. Daroff , Gerald M. Fenichel, C. David Marsden, Neurology in clinical practice, Butter Worth, Heiemann, 2000. p. 1423-30.
- 8 David I Graham, Peter L Lantos. Greenfield's Neuropathology, 6 th ed, Arnold, 1997. p. 235-64.
- 9 Masters CL, Richardson EP Jr. Subacute spongiform encephalopathy (Creutzfeldt-Jacob) disease: the nature and progression of spongiform Change. *Brain* 1978; 101: 333-44.
- 10 Malamud N. Creutzfeldt-Jacob's disease: a clinicopathologic study. In: Prusiner SB, Hadlow WJ eds. Slow transmissible diseases of the nervous system, vol 1. New York: Academic Press, 1979. p. 271-85.
- 11 Beck E, Daniel PM, Matthews WB, et al. Creutzfeldt-Jacob disease. The neuropathology of a transmission experiment. *Brain* 1969; 92: 699-716.
- 12 Muramoto T, Kitamoto T, Tateishi J, Goto I. The sequential development of abnormal prion protein accumulation in mice with Creutzfeldt-Jacob disease. *AM J Pathol* 1992; 140: 1411-20.
- 13 Szabo K, Achtnichts L, Grips E, et al. Stroke-like presentation a case of Creutzfeldt-Jakob disease. *Cerebrovasc Dis* 2004; 18: 251-3.
- 14 Mchndiratta MM, Chowdhury D, Gupta M. Stroke like presentation of Creutzfeldt-Jakob disease. *J Assoc Physicians India* 2000; 48: 658-9.