

# A Newborn Infant with a Pulsatile Substernal Structure in a Midline Defect; Cantrell's Syndrome

R. Shabaniyan, M. Kadivar<sup>1</sup>, A.R. Kiani,  
M.A. Navabi<sup>2</sup>, M.R. Mirzaaghayan<sup>2</sup>,  
A. Kocharian

## Abstract

The present report describes a male newborn with a pulsatile structure beneath the sternum. Echocardiography showed common atrium, a single ventricle, mitral atresia, double outlet right ventricle, subpulmonary stenosis, small pulmonary artery branches, and a thin walled ventricular diverticulum suggestive of Cantrell's syndrome. The diverticulum was resected to prevent life threatening events such as arrhythmias, thrombogenicity, and spontaneous rupture of diverticulum. Maternal use of carbamazepine during pregnancy seems to be the etiologic factor.

**Iran J Med Sci 2007; 32(1): 48-50.**

**Keywords** • Cantrell's syndrome • carbamazepine • heart disease • diverticulum

## Introduction

**C**antrell's syndrome, described first by Cantrell and colleagues in 1958,<sup>1</sup> is a rare constellation of congenital midline defects involving the heart with a variety of complex malformations. The full Cantrell's pentalogy includes midline supraumbilical abdominal defects, defect of the distal part of sternum, deficiency of the diaphragmatic pericardium, deficiency of the ventral diaphragm, and congenital cardiac malformation.<sup>2</sup> Earlier, the patients with this combination were considered to have a variant of ectopia cordis.<sup>1</sup> Since the initial description, at least 150 new cases have been reported.<sup>1-3</sup> The present report describes a newborn infant with full features of Cantrell's syndrome whose mother used carbamazepine during pregnancy.

## Case Description

The case was a male neonate delivered by cesarean section at 37 weeks of gestation of a complicated pregnancy with an Apgar score of 8 and 9 (at 1 and 5 minutes after birth), and a birth weight of 2400 g. He was the product of non-consanguineous marriage born to a gravida one, para one, 23-year-old mother who did not have a proper prenatal care.

After an episode of suppurative otitis media, which was complicated by sagittal sinus thrombosis, the mother did have several episodes of seizure in the first trimester of pregnancy. She was admitted to the hospital, and treated with broad spectrum intravenous antibiotics for two weeks. The evaluation of the mother revealed no evidence in favor of systemic lupus erythematosus and antiphospholipid antibody was negative.

The thrombosis screening test results were also within normal limits. The magnetic resonance imaging revealed

Departments of Pediatric Cardiology and  
<sup>1</sup>Neonatology, Children's Medical Center,  
<sup>2</sup>Department of Cardiac Surgery,  
Imam Khomeini Hospital,  
Tehran University of Medical Sciences,  
Tehran, Iran.

### Correspondence:

Maliheh Kadivar MD,  
Department of Pediatrics,  
Division of Neonatology,  
Neonatal Intensive Care Unit,  
Children's Medical Center,  
Tehran University of Medical Sciences,  
Tehran, Iran.

**Tel:** + 98 21 66930635

**Fax:** +98 21 66930024

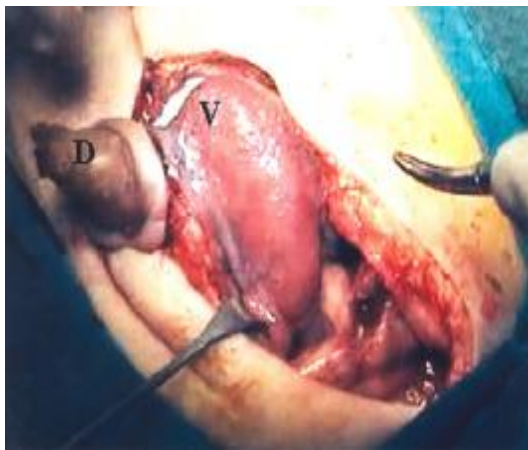
**Email:** [kadivarm@sina.tums.ac.ir](mailto:kadivarm@sina.tums.ac.ir)

abnormal signals in the superior sagittal sinus in axial T2 in favor of superior sagittal thrombosis without any shifts. She was treated with carbamazepine for maintenance therapy. No seizure was observed after the initiation of treatment.

After the delivery, a 2×2 cm pulsatile structure protruding through a midline defect in the epigastrium was seen beneath the newborn's sternum. The structure was connected to the umbilicus with a linear scarred skin lesion. Cardiac sounds were audible over the right hemithorax, indicating dextrocardia. Further, there was a systolic murmur (grade 2) with its maximum intensity at the right sternal border. Other associated congenital anomalies were as follows: wide nasal bridge, scaphocephaly, and hypoplastic scrotal sac with retractile testes. Physical examination was otherwise normal.

The electrocardiogram showed sinus rhythm, right axis deviation, right ventricular hypertrophy, and ST-T changes in the standard leads II and aVF. Chest radiography revealed the dextrocardia and normal cardiothoracic ratio. The color Doppler echocardiogram showed mitral atresia, a single ventricle (right ventricular morphology), normally related great arteries, common atrium, double outlet right ventricle, subpulmonary stenosis with 24 mmHg pulmonary gradient, small pulmonary artery branches, left aortic arch, and a thin walled ventricular diverticulum. Additional imaging studies such as brain and abdominal ultrasounds were normal. The chromosomal study revealed normal 46 XY karyotype.

The sternum was opened from the suprasternal notch toward the distal part, and then around the diverticulum, which had arisen from the ventricle (figure 1). The xyphoid process was absent. There was a pericardial defect, dextrocardia, left-sided superior vena cava and



**Fig 1:** The diverticulum (D) arising from the ventricle (V) after opening of the sternum.

right-sided inferior vena cava. The aorta was detected posterior to the pulmonary artery. A ventral diaphragmatic defect and the diastasis recti were also noticed. Without using the cardiopulmonary bypass technique, the base of the diverticulum was clamped, and excised with its attached bone bits. The edges were then sutured together. Ventral diaphragmatic defect was also repaired by suturing the diaphragmatic remnants to the anterior rib cage. Approximation of the sternal bars with stainless steel wires was done with great cautious to preserve the cardiac output while avoiding mediastinal compression or vessel kinking. The patient remained hemodynamically stable. The abdominal wall defect that was appeared as a linear scarred skin lesion over the epigastrium was not repaired at that time. The infant was discharged from the hospital after an uneventful postoperative recovery with cardiology follow up.

## Discussion

The cause of Cantrell's syndrome has yet to be identified, though some cases are linked to a gene located on (Xq26.1).<sup>1</sup> Parvari and colleagues mapped the thoracoabdominal syndrome gene to Xq24q271.<sup>2</sup> The pathologic event occurs in the embryonic period when primitive mesoderm differentiates into splanchnic and somatic layer.<sup>1</sup> Failure of primitive sternal bars to meet and fuse in the midline leads to a spectrum of sternal defects such as sternal fissure, bifid sternum, or absence of xyphoid process.<sup>1,3</sup>

Deficiency of the diaphragmatic portion of the pericardium makes a free connection between pericardial and peritoneal cavity. The absence of pericardium and pericardial diverticulum has also been reported.<sup>1</sup> Diaphragmatic defect varies from ventral absence to complete aplasia of diaphragm. Supraumbilical omphalocele, umbilical or epigastric hernia, and diastasis recti are frequent abdominal wall defects described in this syndrome.<sup>1,4</sup>

It was also reported that Cantrell's syndrome was associated with different malformations including craniofacial malformation, anencephaly, anophthalmia, lung hypoplasia, intestinal malrotation, dysplastic kidney, extrophy of cloaca, imperforated anus, cryptorchidism, and limb anomalies.<sup>1,5,6</sup>

Ventricular septal defect is almost invariably present as a component of complex cardiac malformation in Cantrell's syndrome. Other reported cardiac anomalies include atrial septal defect, left ventricular diverticulum, tetralogy of Fallot, pulmonary stenosis or atresia, dextrocardia, left superior vena cava, transposition of great arteries, tricuspid atresia, ectopic heart,

double outlet right ventricle, common arterial trunk, and total anomalous pulmonary venous drainage.<sup>1,5,7-9</sup>

In the case of ventricular diverticulum, early surgical intervention for resection deems necessary to prevent life threatening events such as arrhythmias, thrombogenicity, and spontaneous rupture of diverticulum. Furthermore, simple closure of the sternal defect during the first month of life will avoid the more complex reconstruction necessary in older children.<sup>1,3</sup>

Almost all signs and symptoms as well as pathology of Cantrell pentalogy were seen in our patient. It is important to mention that the patient was exposed to carbamazepine in the first trimester of fetal period. There are some reports, which reveal an increased rate of major congenital anomalies such as congenital heart defect among children whose mothers' epilepsy were treated with carbamazepine during pregnancy.<sup>10,11</sup> To the best of our knowledge, this is the first report of Cantrell's syndrome in a patients whose mother had used carbamazepine in the first trimester of pregnancy.

In conclusion, the present case did have all features of Cantrell's syndrome, which was most likely associated with the use of carbamazepine during the first trimester of pregnancy.

## References

- 1 Vazquez-Jimenez JF, Muehler EG, Daebritz S, et al. Cantrell's syndrome: a challenge to the surgeon. *Ann Thorac Surg* 1998; 65: 1178-85.
- 2 Chen CP, Shih JC, Tzen CY, Wang W. Three-dimensional ultrasound in the evaluation of complex anomalies associated with fetal ventral midline defects. *Ultrasound Obstet Gynecol* 2002; 19: 102-4.
- 3 Halbertsma FJ, van Oort A, van der Staak F. Cardiac diverticulum and omphalocele: Cantrell's pentalogy or syndrome. *Cardiol Young* 2002; 12: 71-4.
- 4 Weber TR, Au-Fliegner M, Downard CD, Fishman SJ. Abdominal wall defects. *Curr Opin Pediatr* 2002; 14: 491-7.
- 5 Fernandez MS, Lopez A, Vila JJ, et al. Cantrell's pentalogy. Report of four cases and their management. *Pediatr Surg Int* 1997; 12: 428-31.
- 6 Uygur D, Kis S, Sener E, et al. An infant with pentalogy of Cantrell and limb defects diagnosed prenatally. *Clin Dysmorphol* 2004; 13: 57-8.
- 7 Bogers AJ, Hazebroek FW, Hess J. Left and right ventricular diverticula, ventricular septal defect and ectopic cordis in a patient with Cantrell's syndrome. *Eur J cardiothorac Surg* 1993; 7: 334-5.
- 8 Achiron R, Shimmel M, Farber B, Glaser J. Prenatal sonographic diagnosis and perinatal management of ectopia cordis. *Ultrasound Obstet Gynecol* 1991; 1: 431-4.
- 9 Alayunt A, Yagdi T, Alat I, et al. Left ventricular diverticulum associated with Cantrell's syndrome and tetralogy of Fallot in an adult. *Scand Cardiovasc J* 2001; 35: 55-7.
- 10 Diav-citrin O, Shechtman S, Arnon J, Ornoy A. Is carbamazepine teratogenic? A prospective controlled study of 210 pregnancies. *Neurology* 2001; 57: 321-4.
- 11 Wide K, Winbladh B, Kallen B. Major malformations in infants exposed to antiepileptic drugs in utero, with emphasis on carbamazepine and valproic acid: a nationwide, population-based register study. *Acta Pediatr* 2004; 93: 174-6.