

Acquired Infrarenal Abdominal Aortic Coarctation: Treatment with Percutaneous Self Expandable Stent

H. Nough, M.A. Haji-Zeinali¹, Z. Ansari,
H.R. Varastehravan, M. Emami,
P. Mirmohamedi

Abstract

Abdominal aortic coarctation is an extremely rare vascular pathology. Its etiology can be congenital or acquired. Here we present a case of acquired infrarenal abdominal coarctation in a 66-year-old woman who complained of low back and legs pain. She had no signs of resting lower limb ischemia, with diminished distal pulses and normal blood pressure in upper and lower extremities. Magnetic resonance angiography of abdominal aorta, iliac and femoral arteries revealed local stenosis of abdominal aorta below the renal arteries (80% of luminal diameter). The length of coarctation was 3 cm. The patient was scheduled for percutaneous aortoplasty and stent implantation. Nintinol self-expandable stent was implanted. At 9 months clinical follow up no signs or symptoms of stenosis or diminished blood flow in lower extremities were found. Self-expandable stent is effective, easy to implant, and has good adaptation to the wall of aorta and can be considered in such cases successfully.

Iran J Med Sci 2008; 33(4): 244-247.

Keywords • Aortic coarctation • stent • transluminal arterial dilatation • abdominal

Introduction

Abdominal aortic coarctation (AAC) is an extremely rare vascular pathology. Its etiology can be congenital or acquired.¹ AAC was first described by Quain in 1848.² It comprises approximately 2% of all coarctations of aorta.^{1,3} The exact etiology of ACC is still controversial. Congenital, acquired, inflammatory, and infectious etiologies have been proposed.⁴

Multiple operative strategies have been described to manage AAC. Balloon angioplasty is an alternative treatment for AAC.¹ Usefulness of balloon and self-expanded stent implantation in the treatment of AAC is under evaluation.⁵ Many studies demonstrated the benefits of self-expandable stent such as feasibility, accurate implantation, low stent dislodgment or migration, and late remodeling in the treatment of aortic coarctation.⁶ In the present study we report a rare case of acquired infra renal artery coarctation that was treated with self-expanded stent.

Case Presentation

A 66-year-old woman with low back and exertional legs pain for two years referred from orthopedic clinic. The patient had

Department of Cardiology,
Heart Research Center,
Afshar Hospital,
Shahid Sadoughi University of Medical
Sciences,
Yazd, Iran.

¹Department of Cardiology,
Tehran Heart Center,
Tehran University of Medical Sciences,
Tehran, Iran.

Correspondence:

Zahra Ansari MD,
Department of Cardiology,
Heart Research Center,
Afshar Hospital,
Shahid Sadoughi University of Medical
Sciences,
Yazd, Iran.

Tel: +98 351 5231421

Fax: +98 351 5253335

Email: nedansari@yahoo.com
hrc@ssu.ac.ir

Submitted: 20 April 2008

Revised: 25 June 2008

Accepted: 7 September 2008

recurrent references to neurologists and orthopedic surgeons and received different treatments; however, no significant improvement was obtained. The patient described persistent low back and legs pain, which became intensive with activity. The blood pressure was 135/80 mmHg and within normal range in upper and lower extremities. The heart rate was 72 beats/min and physical examination was normal. No murmur was detected on abdomen and renal arteries. No abdominal mass was palpated. There was a relatively diminished pulse in femoral, popliteal, and posterior tibialis arteries (+1). No muscular or neurological disorders were found.

The results of all laboratory evaluations were in the normal range. Electrocardiography showed no abnormal changes. Chest radiography showed no evidence of cardiomegaly, aortic knob prominence, or rib notching.

In order to find vessels' pathology as an etiologic factor for the patient's pain, Doppler ultrasonography of abdominal vessels (aorta and iliac arteries) was carried out that showed no abnormal findings.

Magnetic resonance angiography (MRA) of abdominal aorta, iliac, and femoral arteries showed a local stenosis of abdominal aorta (80% of luminal diameter) below the renal arteries with no expansion to mesenteric, iliac, or other branches of aorta. The length of coarctation was 3 cm (figure 1). Abdominal aortography revealed localized (3 cm length) stenosis of aorta (80% of luminal diameter) below the renal arteries (figure 2).

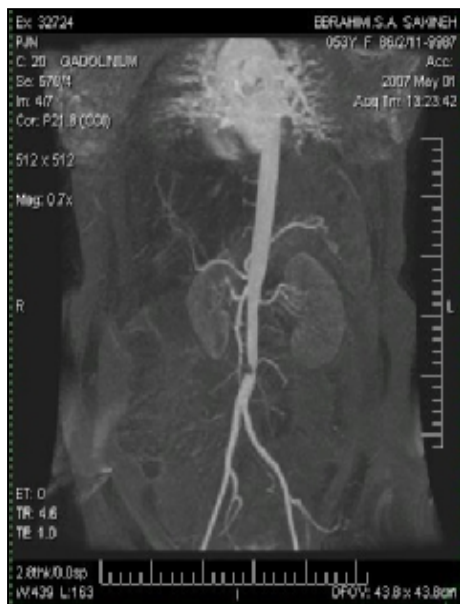

Figure 1: Magnetic resonance angiography of abdominal aorta: A local stenosis of abdominal aorta below the renal arteries with no expansion to mesenteric, iliac or other branches of aorta is seen.

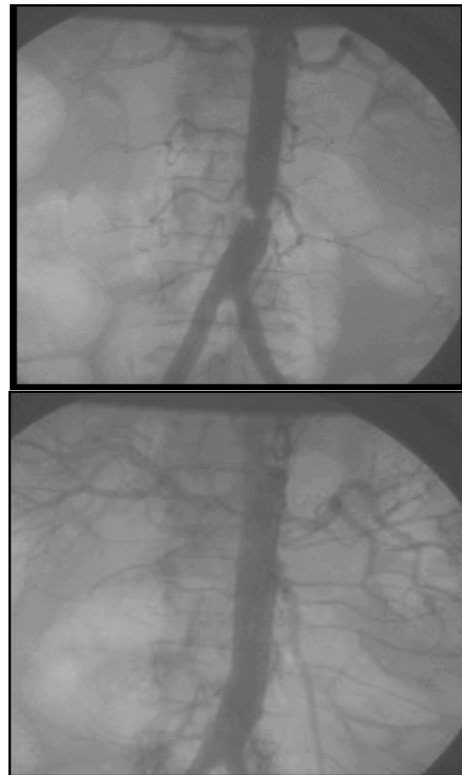


Figure 2: The coarctation before and after revascularization showing about 80% decrease in luminal diameter.

The patient received aspirin (ASA) 100 mg/day since 1 month, clopidogrel (Plavix®) 75 mg/day since 5 days before the procedure, and 5000 units unfractionate heparin before the procedure.

The procedure was performed via right femoral artery. The delivery system was placed at site on the 35% inch wire. For the procedure we used a self expandable nintinol stent (Optimed, Germany) with 20mm diameter and 60mm length. After placing the stent, it inflated with a optimed balloon (14mm diameter and 20mm length) with 8^{atm} pressure. We did not dilate the stenosis before placing the stent with balloon (predilation). The final aortogram showed good result without residual stenosis.

Discussion

Coarctation of abdominal aorta is quite rare with an overall incidence of 1/62500 in an autopsy study.⁷ Previous studies have shown that focal AAC without involvement of the renal or mesenteric arteries occurred in only a small percentage of patients with AAC.

Coarctation of abdominal aorta can be congenital or acquired. The etiology of acquired abdominal coarctation is poorly understood. Developed defects, a response to infection and inflammation, have been proposed as possible mechanisms.¹ Syphilis, rheumatic fever, non-

rheumatic inflammation, neoplasia are other possible mechanisms. According to some recent reports a possible association between neurofibromatosis and Takayasu arteritis has been proposed.^{8,9} Morris suggested that the localized intimal thickening in the lesions in the lower abdominal aorta might represent a proliferative form of atherosclerosis.¹⁰ In our reported case, according to the age and onset of symptoms in middle ages, acquired coarctation seems to be secondary to a localized atherosclerosis.

Patients with coarctation are more likely to develop lower extremity claudication and weak to absent distal pulses later in life.¹ In the present case despite the low back and exertional legs pain and diminished lower limbs pulses, existence of normal blood pressure can be explained by forming collateral vessels that compensated the lack of blood flow in lower extremities.

Abdominal coarctation needs to be surgically corrected when it is associated with aneurismal degeneration, aortoiliac occlusive disease, or severe hypertension.¹¹

Endovascular treatment is a less invasive alternative to open surgical repair for selected patients. Over the last two decades percutaneous balloon angioplasty has been used for treatment of coarctations.⁴ In 1991, O'Laughlin et al. reported the first use of an endovascular stent to treat coarctation of aorta.¹²

In our patient, the focal nature of the stenotic lesion and absence of significant branch vessel involvement were characteristics that allowed us for an endovascular repair.

An experimental study by Suarez de Lezo and Colleagues,⁵ showed the feasibility and immediate results of balloon-expandable stent implantation in 10 patients with severe coarctation of aorta. The same results were reported in 48 patients in another study.⁶ Another study by Sanjay Tyagi et al. revealed that implantation of balloon and self-expandable stents was an effective and safe treatment in adults with native coarctation of aorta. They showed that self-expanded stents could be implanted accurately across the coarctation with further reduction in gradients, did not have problems of stent dislodgment/ migration, and adapted better to aortic wall. Beneficial late remodeling on follow-up was an extra benefit.⁴ In the Haji-Zeinali's study the same results were achieved.¹³

Based on the available data, our patient was scheduled for self-expandable stent implantation. After performing percutaneous transluminal intervention and stent deployment, the patient became symptom free and within 9

months clinical follow-up, there were no signs or symptoms of stenosis or diminished blood pressure in lower extremities, or complications.

Conclusion

Focal infrarenal abdominal coarctation is very rare. Using self-expandable stent for acquired infrarenal coarctation is safe although long-term follow-up is required.

Conflict of Interest: None declared

References

- 1 Eliason JL, Passman MA, Guzman RJ, Naslund TC. Durability of percutaneous angioplasty and stent implantation for the treatment of abdominal aortic coarctation: a case report. *Vasc Surg* 2001; 35: 397-401.
- 2 Koksall C, Demirci S, Koksall GM, Zengin M. An infrarenal abdominal aortic coarctation. *Surg Radiol Anat* 2005; 27: 71-3.
- 3 Scott HW Jr, Dean RH, Boerth R, et al. Coarctation of the abdominal aorta: pathophysiologic and therapeutic considerations. *Ann Surg* 1979; 189: 746-57.
- 4 Tyagi S, Singh S, Mukhopadhyay S, Kaul UA. Self- and balloon-expandable stent implantation for severe native coarctation of aorta in adults. *Am Heart J* 2003; 46: 920-8.
- 5 Suárez de Lezo J, Pan M, Romero M, et al. Balloon-expandable stent repair of severe coarctation of aorta. *Am Heart J* 1995; 129: 1002-8.
- 6 Suárez de Lezo J, Pan M, Romero M, et al. Immediate and follow-up findings after stent treatment for severe coarctation of aorta. *Am J Cardiol* 1999; 83: 400-6.
- 7 Ilica AT, Bilici A, Ilhan A, et al. Thoracoabdominal aorta coarctation with bilateral renal artery involvement: diagnosis with multidetector CT angiography (MDCTA). *Int J Cardiovasc Imaging* 2007; 23: 645-8.
- 8 Bahnon HT, Cooley RN, Sloan RD. Coarctation of the aorta at unusual sites; report of two cases with angiographic and operative findings. *Ann Surg* 1948; 128: 803-20.
- 9 Inada K, Shimizu H, Kolayashi J, et al. Pulseless disease and atypical coarctation of aorta, with special reference to their genesis. *Surgery* 1962; 52: 433.
- 10 Morris Gc Jr, DE Bakey Me, Cooley Da, Crawford Es. Subisthmic Aortic Stenosis and Occlusive Disease. *Arch Surg* 1960; 80: 87-104.
- 11 Connolly JE, Wilson SE, Lawrence PL,

Acquired infrarenal abdominal aortic coarctation

- Fujitani RM. Middle aortic syndrome: distal thoracic and abdominal coarctation, a disorder with multiple etiologies. *J Am Coll Surg* 2002; 194: 774-81.
- 12 O'Laughlin MP, Perry SB, Lock JE, Mullins CE. Use of endovascular stents in congenital heart disease. *Circulation* 1991; 83: 1923-39.
- 13 Haji-Zeinali AM, Ghasemi M. Coarctoplasty with self-expandable stent implantation for treatment of coarctation of aorta in adults. *Arch Iran Med* 2006; 9: 348-53.