

# Isolated Primary Hydatid Disease of Omentum; Report of a Case and Review of the Literature

Ali Ghafouri<sup>1</sup>, Shirzad Nasiri<sup>2</sup>,  
Abolfazl Shojaee Far<sup>2</sup>, Mohammad Reza  
Mobayen<sup>2</sup>, Mehdi Tahamtan<sup>2</sup>, Moham-  
mad Nazari<sup>2</sup>,  
Zeinab Gharib Doost<sup>2</sup>

## Abstract

Hydatid disease, most commonly caused by the larval stage of *Echinococcus granulosus*, affects mainly human liver and lung, and rarely other parts of the body. It is prevalent in most sheep-raising Mediterranean Countries including Iran. Peritoneal hydatid cyst, either primary or secondary, represents an uncommon but significant manifestation of the disease. The present case report describes a case of primary isolated hydatid disease of omentum, which to our knowledge constitutes the first case of this kind in Iran.

**Iran J Med Sci 2010; 35(3): 259-261.**

**Keywords** • Hydatid • Echinococcus • primary • omentum

## Introduction

Hydatid disease may involve any organ or any part of the human body. Therefore, in any person who lives in an endemic area, and presents with a cystic lesion in any part of his/her body the hydatid disease must be considered in the differential diagnosis. Extrahepatic hydatid disease frequently occurs after hepatic involvement. Intraperitoneal hydatid disease constitutes about 3.9-12.5% of all intraabdominal hydatidosis.<sup>1-3</sup>

Omental hydatid disease is usually secondary to spontaneous rupture of liver or splenic cyst due to abdominal trauma. Primary peritoneal cyst is very rare and should be differentiated from mesenteric or duplication cyst.<sup>4</sup>

## Presentation

The case was a 21-year-old woman, who referred to a gynecologist 8 months after her first delivery complaining of abdominal pain, which she thought might be due to improper placement of IUD. Abdominal and pelvic ultrasonography were done for her. In ultrasonography a pure cystic lesion of approximately 63X76 mm dimensions with a double layer membrane, a septum and an internal wall characteristic of hydatid cyst was detected in greater omentum (figure 1). The cyst was independent on other organs. Moreover, CT scan with intravenous contrast revealed a cystic lesion with criteria similar to those characteristic of hydatid disease on the omentum (figure 2). Antihydatid cyst antibody, measured by ELISA, was negative, and liver function as well as hematological and biochemical tests were normal. She was living in a rural area, and was in touch with animals. She was referred to a surgery clinic.

Further physical examination revealed that for the preceding 6 months she had a mild constant epigastric pain, which used to radiate towards her back, and was not affected by food intake or change in body position. She had no history of vomiting

<sup>1</sup>Department of General and Thoracic Surgery,

<sup>2</sup>Department of General Surgery, Dr Shariati Hospital, School of Medicine, Tehran University of Medical Sciences, Tehran, Iran.

### Correspondence:

Ali Ghafouri MD,  
Department of General and Thoracic Surgery,  
Dr Shariati Teaching Hospital,  
Post Code: 1411713135  
Tehran University of Medical Sciences,  
Tehran, Iran.

**Tel:** +98 21 84902450

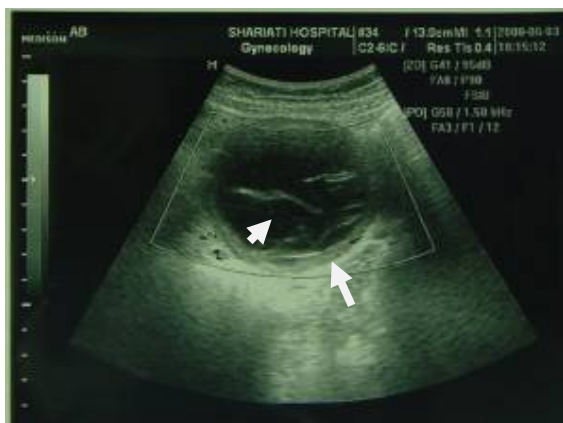**Fax:** +98 21 88633039

**Email:** aghafouri@sina.tums.ac.ir

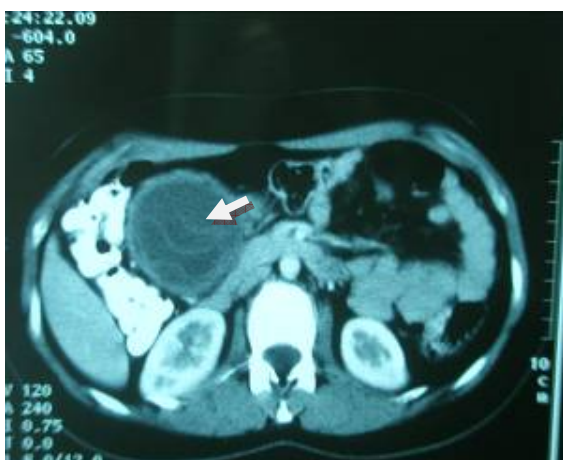Received: 1 June 2009

Revised: 7 October 2009

Accepted: 14 November 2009



**Figure 1:** Abdominal ultrasonography image of the omental hydatid cyst. Big arrow shows the double germinal membrane and short arrow shows a single germinal layer.



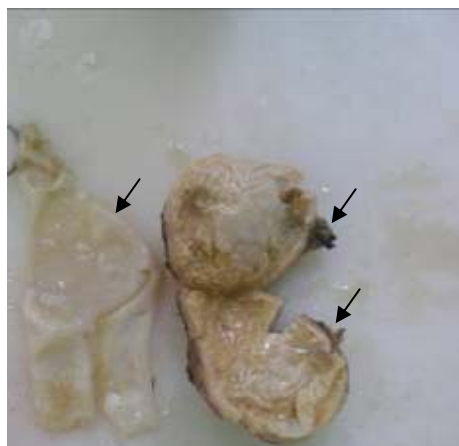
**Figure 2:** Abdominal CT scan showing a hydatid cyst with laminated layer in front of right kidney.

or change of bowel habit. She had no any specific medical history, except her caesarian section 8 months before.

Laparotomy showed a cyst measuring 63x67 mm within the greater omentum. The cyst was excised intact along with a rim of greater omentum. There was no invasion to surrounding tissues. Exploration revealed no other pathology within the abdomen. The cyst was infected and had a germinal layer (figure 3). Pathological findings confirmed the presence of hydatid disease including a germinal layer with wall calcification, necrosis, and chronic inflammation. Abdominal ultrasonography of the rest of her family was revealed that two of them had hepatic hydatid cysts.

## Discussion

The echinococcus or hydatid disease, a parasitic infestation caused by a tapeworm, is an endemic problem in some areas of the world including Mediterranean regions.<sup>1,4</sup> The mature



**Figure 3:** The opened cyst with its germinal layer and adventitia. Short arrow points to the adventitia and long arrow toward the germinal layer. A hemostat forceps has been used to give an indication of the size of the cyst.

adult worm, *Echinococcus granulosus*, lives in the dog intestine. The worm eggs are excreted via feces, and contaminate farms, vegetables and fruits. Human, sheep or cattle are the parasite's intermediate host. Humans are accidentally infected by eating contaminated vegetables or fruits. The parasites oncospheres are released in stomach or intestine. Then, they penetrate the intestinal wall, enter into blood circulation, and reaches liver via portal stream. After escaping hepatic filter, they enter the systemic circulation and settle mainly in the lungs or rarely in other organs.<sup>5</sup> When oncospheres reach a final location, they evolve into the larval stage, commonly known as the hydatid cyst.

Infestation with hydatid cyst is common in childhood, and may remain asymptomatic for years. The disease may appear at any age, but it is more frequent between ages 30 and 60. No sexual predilection is recognized but some studies reported higher occurrence in females.<sup>6</sup>

The cysts reach over 10 cm in diameter in 5 years, and cause extensive tissue damage. The cysts may remain asymptomatic until they reach a larger size. Clinical symptoms vary according to the size of the cyst, sites of cyst localization, mechanical pressure produced by the cysts, and systemic reactions in the case of perforation.

Nowadays, the diagnosis of hydatid disease is easier than was previously, because of the improvement in new imaging techniques including ultrasonography, CT scan and MRI. The accuracy of ultrasonography in the diagnosis of hydatid cyst is 70 to 85% and that of CT scan is 80 to 90%. The level of accuracy increases when the two techniques are used simultaneously. CT scan is of particular importance in the designation of surgery strategy.<sup>7</sup>

The two most widely used tests for the diagnosis of the cyst are immunoelectrophoresis,

with a sensitivity of 66-68%, and enzyme-linked immunosorbent assay (ELISA), with a sensitivity of 95-97%.

For an unusual site of cyst localization the differential diagnosis can be difficult, intraoperative findings can be different, and the site may remain unrecognized before surgical operation. In such a case, diagnosis can be confirmed by a combination of serological and radiological techniques. Due to the wide range of symptoms, which the disease can cause in endemic areas, all abdominal cystic lesions including mesenteric, choledochal, pancreatic, gastrointestinal duplication and ovarian cysts, and cystadenoma and lymphangioma, must be considered in the differential diagnosis of the disease. If the cyst is complicated, the differential diagnosis should include also intraabdominal abscess, hematoma and ascites.<sup>2</sup>

Over 90% of patients with hydatid cysts develop complications unless treated, and only 1% of them recover spontaneously. Therefore, hydatid cyst should be treated as soon as it is diagnosed. Generally, the aim of the treatment is to remove the cyst and to decrease the risks of complication and recurrence. The basis of the surgical treatment of omental hydatid cyst is to perform total cystectomy without sacrificing other organs,<sup>5</sup> even if, the patient is asymptomatic because of the risks of torsion, rupture, bleeding and infection.<sup>2</sup>

Pre- and postoperative albendazole therapy should be added to the treatment to prevent spillage and to avoid recurrence of the disease, however, in the case the disease recurrence or multiple locations, chemotherapy should be used routinely.<sup>4,8</sup> Certain measures such as spillage of the cyst contents during operation, spread of viable scolices and overlooked small cysts, which result in the disease recurrence, should be avoided.<sup>8</sup> The mortality and morbidity rates of disease recurrence is high. Preoperative treatment with albendazole, a systemic drug, is effective in reducing the rate of recurrence.<sup>9-11</sup>

When a cyst is attached to the abdominal wall, percutaneous aspiration and alcohol injection and reaspiration can be useful. Sometimes it may be aspirated by laparoscopy.<sup>4,8,12</sup> When a cyst is intraabdominal, complete or partial cystectomy with or without drainage or omentopexy is the option. The surgical method used in the present case report was intact resection.

## Conclusion

In countries in which hydatid disease is

endemic, hydatid cyst should be considered in the differential diagnosis of cystic lesions within the abdominal cavity. The cyst may be primary and asymptomatic, and be discovered during an examination for other problems. The intraabdominal hydatid cyst may be excised intact.

**Conflict of Interest:** None declared

## References

- 1 Yuksel M, Demirpolat G, Sever A, et al. Hydatid disease involving some rare locations in the body: a pictorial essay. *Korean J Radiol* 2007; 8: 531-40.
- 2 Sekmenli T, Koplay M, Sezgin A. Isolated omental hydatid cyst, clinical, radiologic and pathologic findings. *J Pediatr Surg* 2009; 44:1041-3.
- 3 Sethi SK, Patnaik S, Narayan, Nayak SN. Isolated omental hydatid cyst. *J Indian Med Assoc* 2004; 102: 644-6.
- 4 Atmatzidis KS, Pavlidis TE, Papaziogas BT, et al. Recurrence and long term outcome after open cystectomy with omentoplasty for hepatic disease in an endemic area. *Acta Chir Belg* 2005; 105:198-202.
- 5 Hamamci EO, Besim H, Korkmaz A. Unusual locations of hydatid disease and surgical approach. *ANZ J Surg* 2004; 74: 356-60.
- 6 Kiyak G, Ergül E, Korukluoğlu B. Primary Hydatid Disease of the Soft Tissue. *Acta Chir Belg* 2007; 107: 452-3.
- 7 Ilica AT, Kocaoglu M, Zeybek N, et al. Extrahepatic abdominal hydatid disease caused by Echinococcus granulosus: imaging findings. *AJR Am J Roentgenol* 2007; 189: 337-43.
- 8 Halil Alis, Selin Kapan, Osman Öner, et al. Primary omental hydatid cyst. *International Medical Case Reports Journal* 2009; 1: 7-10.
- 9 Sayek I, Onat D. Diagnosis and treatment of uncomplicated hydatid cyst of the liver. *World J Surg* 2001; 25: 21-7.
- 10 Rosa M, Sahoo S. Primary hydatid cyst of the omentum. *Diagn Cytopathol* 2009; 37: 117-8.
- 11 Engin G, Acunas B, Rozanes I, Acunas G. Hydatid disease with unusual localization. *Eur Radiol* 2000; 10: 1904-12.
- 12 Angulo JC, Escribano J, Diego A, et al. Isolated retrovesical and extrarenal retroperitoneal hydatidosis: clinical study of 10 cases and literature review. *J Urol* 1998; 159: 76-82.