

Ear Teratoma; a Case Report

M.A. Mojabi

Abstract

Teratomas are tumors originated from mature or immature tissues. Teratomas are made up of one embryonic layer or all three embryonic layers (endoderm, mesoderm, or ectoderm). Herein we report a 41-year-old man who presented with vertigo, vomiting, and tinnitus. After physical examination, laboratory evaluation and performing computed tomography, cholesteatoma was diagnosed, however, during radical mastoidectomy a cystic tumor was found. The result of pathology proved middle ear and mastoid teratoma.

Iran J Med Sci 2007; 32(3): 188-190.

Keywords • Teratoma • middle ear • eustachian tube • mastoid • dermoid cyst • cholesteatoma

Introduction

Recent reports suggest that rare teratomas of the middle ear do exist. Middle ear teratomas are defined as tumors consisting of benign tissues derived from all three embryonic layers; endoderm, mesoderm, and ectoderm. They are lesions of the neonatal period and early infancy. The origin of these tumors is multipotential cells, which are naturally present in testis or ovary and sometimes present in embryonic cells remaining in midline.^{1,2}

Germinal layers during embryonic period are situated in the midline under coelomic epithelium and usually migrate to gonads. If, for any reason, this process fails, the process of teratoma formation will be started.

The first ear teratoma was reported by Toynebee in 1866. Till now 19 other cases have been reported in different names such as congenital hairy polyp, epidermal cyst, dermoid cyst, and hamartoma.

WHO has tried to unify the different names of teratoma by introducing a new classification system. It classified ovarian teratoma into monoderm, mature, immature, and mixed.³ It must be mentioned that this classification is applicable for head and neck teratomas.

Monoderm type is formed from one germinal layer, which is usually ectoderm. Immature teratomas are usually malignant and a histological grading from 0 to 3 has been used to predict the prognosis. In grade 0, there are no immature tissues and mitotic activity. In coming grades, mitotic activity and rate of embryonic tissue gradually grow up. Mature teratoma is divided into cystic and solid masses that sometimes have malignant changes. Dermoid cyst, which its real name is teratoma is formed by mesoderm and ectoderm layer. Ten percent of all teratomas are arisen in head and neck.⁴

Case Report

The patient was a 41-year-old man who referred to our clinic

Department of ENT,
Qods Hospital,
Qazvin University of Medical Sciences,
Qazvin, Iran.

Correspondence:

Mirabdolali Mojabi MD,
Department of ENT,
Qods Hospital,
Qazvin University of Medical Sciences,
Qazvin, Iran.

Tel: +98 281 3337680

Fax: +98 281 3341700

Email: ma_mojabi@yahoo.com

because of tinnitus since one month and vertigo and vomiting since one week before. He did not use any drugs in the past but was smoker since 20 years ago. There was no abnormal finding in general physical examination, however in ear examination right tympanic membrane was inflamed and bulged toward outside. Pure tone audiometry showed normal audiogram in the left ear but 60 dB conductive hearing loss and 25dB sensorineural hearing loss in the right ear.

With primary diagnosis of acute otitis media, myringotomy was done and after draining thick pus ventilation tube was installed for removal of further discharge. After the operation, signs of relative cure were observed, but because of the type of ear discharges, computed tomography (CT) of ear was requested. Filling and haziness of tympanic cavity with spreading toward mastoid cells and destruction of intracellular walls were observed in CT scan (figure 1). The damage had moved toward posterior fossa. Clear erosion and severe thinness were observed in posterior of mastoid process. In addition, complete destruction of bone was observed in retroauricular so that the damage was directed toward the outside of the skull (under the scalp).

In general, the findings in the scan were in favor of progressive cholesteatoma. Therefore, the patient was operated with that impression. However during the operation a large cystic mass was observed in mastoid area. Dense discharge and lots of hair were removed when the mass was cut. After removal of the cyst, mastoid bone was completely destroyed and sigmoid sinus was left without any bony coverage. Moreover, lots of white thick discharge around it was removed. In examining the middle ear, the eustachian tube and middle ear were filled with dense discharge of the cyst and the ossicles were completely destroyed. Therefore, radical mastoidectomy was done and fascia of temporalis muscle was used as a graft to cover the middle ear. Also, the skin of arm was used as another graft to cover the sigmoid sinus. Pathological evaluation of the cyst noted that the cystic teratoma contained two layers of ectoderm and mesoderm (figure 2). After 6 years the patient has no discharge and has normal physical examination.

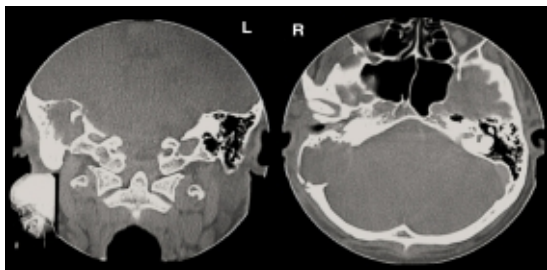


Figure 1: Coronal and axial CT images show fullness of right middle cavity with extension into the mastoid air cells (a) and posterior fossa (b).

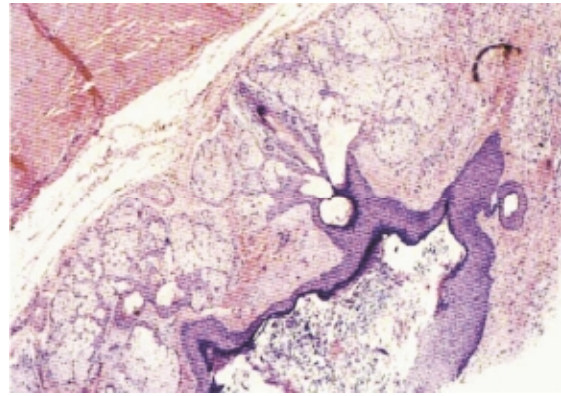


Figure 2: The slide shows the two layers of ectoderm and mesoderm in the cyst.

Discussion

Cystic teratoma contains mature somatic tissues. The tissue surrounding the teratoma is the skin. The keratinized squamous epithelium and the secretions of sebaceous glands with hair masses fill the cyst cavity. Other elements are bronchus, cartilage, bone, neural tissue, and tooth. Cystic teratoma accounts for 20% of all ovarian tumors, and in 1.8% of cases, malignant changes are seen.⁵ If all elements of teratoma are mature and differentiated, it will be benign. But if the cells are immature, it will be malignant or it may change to malignant. Teratoma is a lesion mostly seen in ovary, but it may be seen in testis, or rarely seen in the other parts of body.

The cystic teratoma, which has also been termed as "*Dermoid Cyst*" is a benign lesion in 99% of cases and is full of skin elements.^{6,7} In 80% of cases, teratomas are found in people with the age between 20 to 30 years. It is usually seen in one side, often in the right side as was presented in our case.

Solid teratomas or malignant teratomas consist just one percent of teratomas. They are seen more in ages before puberty and have a rapid growth and metastasizes far from ovary. The 5 years survival is 25-30%.⁶ The pathogenesis of teratomas is unknown and has been postulated in various ways. It is thought that head and neck monodermal teratomas arise from epithelium entrapped in areas of closure of embryogenic process. Others suggest that migration of ectodermal cells may give rise to teratomas.^{1,8}

Most of extra gonadal teratomas are seen in nasopharynx, so it is thought that teratomas located on the axis from the brain to the sacral area. In fact, the ear teratoma originates from the nasopharynx and moves along the eustachian tube.^{1,9} While complete surgical excision will be curative a thorough histological examination of the specimen is recommended to exclude the possibility of immature and frankly

malignant elements being mixed with the benign teratomatous elements.

Conclusion

In any patient aged between 20-30 years that presents with vertigo, vomiting, and tinnitus middle ear teratomas should be considered as a differential diagnosis. As in our reported case his age was more than the average, teratomas should also be considered in elderly patients as a differential diagnosis.

References

- 1 Ruah CB, Cohen D, Sadé J. Eustachian tube teratoma and its terminological correctness. *J Laryngol Otol* 1999; 113: 271-4.
- 2 Cotran RS, Robbins S. Pathologic Basis of Disease. 6th ed, Saunders Co; 1999. p. 262-3.
- 3 Talerman A. Germ Cell Tumours of The Ovary. In Blaustein's Pathology of Female Genital Tract, 4th ed, Springer-Verlag; 1994. p. 849-901.
- 4 Ferlito A, Devaney KO. Development Lesions of the head and neck terminology. 1995. p. 258-300.
- 5 Govan AT, MacFarlane PS. Govan Macfarlane. Pathology Illustrated. 2nd ed, Churchill Livingstone Co; 1989. p. 199-200.
- 6 Sokol RJ, Lasern Jr. JW. Current Obstetric Gynecologic, Diagnosis and Treatment. 8th ed. USA; 1996. p. 284.
- 7 Djouhri Marsot, Dupuch K. Joutel, "Perichiasmatic Granuloma Occuring After Radical Mastoidectomy," Eur. Readial Medline, 1998. p. 286-8.
- 8 Fried MP, Vernick DM. Dermoid cyst of the middle ear and mastoid. *Otolaryngol Head Neck Surg* 1984; 92: 594-6.
- 9 Devaney KO, Rinaldo A, Ferlito A. Teratoma of the middle ear: a real entity or a non-entity? *Acta Otolaryngol* 2005; 125: 122-4.