

Calvarium and Left Cerebral Parenchyma Involvement Arising from Squamous Cell Carcinoma in a Chronic Scalp Wound

Squamous cell carcinomas (SCCs) of the scalp constitute a significant medical condition with relatively uncommon invasive growth and metastasis.¹ However, SCCs originating from Marjolin's ulcer (MU) may have an altogether different course. Indeed, SCCs secondary to MU, by comparison with typical primary SCCs, not only have a considerable tendency to metastasize and invade to the calvarium and brain but also are associated with a significantly poor prognosis.²

Typical primary SCCs of the scalp are mostly caused by cumulative ultraviolet exposure, followed by chronic wounds and scarring processes (mostly post-burn scars), with the latter referred to as "MU".³ Our case had a history of scalp burn, sustained in childhood, in the left parietal region of the head. Therefore, it should come as little surprise that his scalp SCC invaded into his calvarium and brain parenchyma.

A 44-year-old man from Isfahan, Iran underwent surgery in our hospital due to the presence of a lesion (approximately 6×3.5 cm) on the scalp within an old burn injury. During the operation, the scalp lesion and the involved calvarium were resected. Intraoperatively, the frozen section procedure on the samples from the scalp and calvarium showed SCC involvement.

Twelve months later, the patient returned because of the recurrence of the lesion. Rather than heal, the lesion had grown drastically and there were ulcerations and gangrenous discharge. On physical examination, he had aphasia, right-sided paresis, and serosanguinous drainage without signs of infection. Moreover, a lobulated, ulcerated lesion (approximately 20×8 cm) on the inflamed scalp surface with central ulceration was visible (Figure 1).

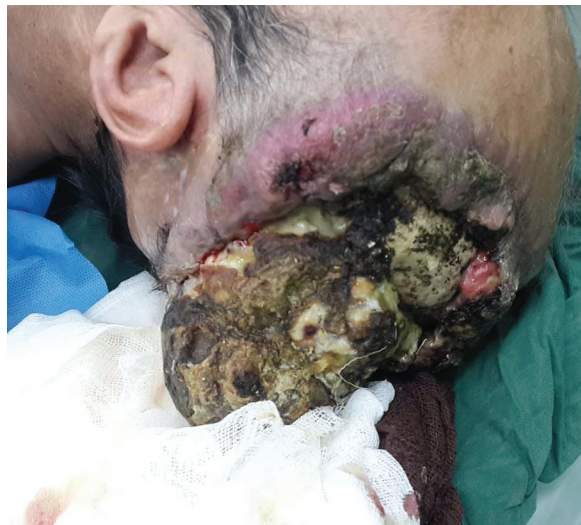

Figure 1: Preoperative photograph of the patient shows an extensive, recurrent, and invasive squamous cell carcinoma of the scalp.

Magnetic resonance imaging (MRI) demonstrated a heterogeneous lesion with low signal intensity on T1 sequence, high signal intensity on T2 and fluid-attenuated inversion recovery (FLAIR) sequences, and heterogeneous enhancement after gadolinium infusion. A large lobulated solid lesion with cystic components (necrosis) was also visualized in the parietal convexity. Additionally, the main bulk of the tumor was extracranial with invasion to the calvarium, dura, and left parietal parenchyma. All these findings were suggestive of a large malignant extracranial lesion with invasion to the calvarium and intracranial involvement, such as an SCC (Figure 2).

Unfortunately, the patient failed to refer to us for a period of up to one year after the surgical treatment and our telephone-conducted follow-up revealed that he had expired due to the recurrence of the SCC in the same region, exacerbated by the further invasion of the malignancy to the brain parenchyma.

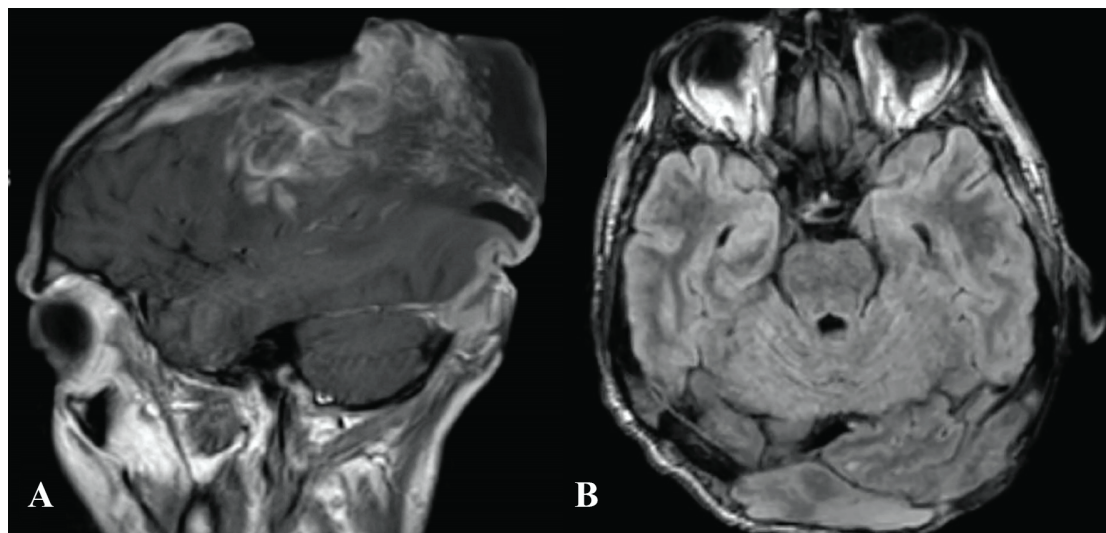


Figure 2: Invasion of the scalp squamous cell carcinoma to the brain parenchyma is illustrated: A) magnetic resonance imaging (MRI) of the brain in a sagittal T1-weighted image with contrast and B) MRI of the brain in an axial T1-weighted image without contrast.

Scalp burn injuries may have a long-term stable period, but they may change to MU with malignancy promptly and progressively once ulcerations are formed or when the burned scalp is stimulated by sunlight. This association between old burn scars and malignancy, consequently, requires close monitoring of chronic scalp wounds, especially burn injuries. The existing literature places great emphasis on the excision and grafting of old burn injuries to prevent scar formation and malignancy; nevertheless, such preventive strategies are poorly employed in a clinical context because of the high cost of surgery, the low incidence of MU (0.77%–2%), or the lack of healthy flap tissue.³

We strongly advise that suspicious old scalp burn wounds be preventively excised.

Written informed consent was obtained from the patient's guardian for the publication of the study.

Conflict of Interest: None declared.

Please cite this article as: Shafiei M, Omid P, Maraki F, Larti N, Zarei MR. Calvarium and Left Cerebral Parenchyma Involvement Arising from Squamous Cell Carcinoma in a Chronic Scalp Wound. *Iran J Med Sci.* 2020;45(5):397-398. doi: 10.30476/ijms.2020.83911.1317.

Mehdi Shafiei¹, MD; Pouya Omid¹, MD; Fatemeh Maraki², MSc; Negin Larti³, MSc, Mohammadreza Zarei⁴, MSc

¹Department of Neurosurgery, School of Medicine, Isfahan University of Medical Sciences, Isfahan, Iran;

²Department of Operating Room, School of Nursing and Midwifery, Shahrekord University of Medical Sciences, Shahrekord, Iran;

³Department of Operating Room, School of Paramedical Sciences, Kermanshah University of Medical Sciences, Kermanshah, Iran;

⁴Department of Operating Room, School of Nursing and Midwifery, Isfahan University of Medical Sciences, Isfahan, Iran

Correspondence:

Mohammadreza Zarei, MSc;

Department of Operating Room, Isfahan University of Medical Sciences, Hezar Jarib Street, Postal code: 81746-73461, Isfahan, Iran

Tel: +98 9137375832

Email: Mohammad.zarei3113@gmail.com

Received: 20 October 2019

Revised: 21 January 2020

Accepted: 26 January 2020

References

- 1 Green A, Battistutta D. Incidence and determinants of skin cancer in a high-risk Australian population. *Int J Cancer.* 1990;46:356-61. doi: 10.1002/ijc.2910460303. PubMed PMID: 2394501.
- 2 Lee MS, Lee JD, Cho SH, Kim HS. Extensive Squamous Cell Carcinoma Originating from a Burn Scar: Marjolin's Ulcer with an Unusual Presentation. *Ann Dermatol.* 2016;28:142-3. doi: 10.5021/ad.2016.28.1.142. PubMed PMID: 26848243; PubMed Central PMCID: PMC4737829.
- 3 Xiao H, Deng K, Liu R, Chen Z, Lin Y, Gao Y, et al. A review of 31 cases of Marjolin's ulcer on scalp: Is it necessary to preventively remove the scar? *Int Wound J.* 2019;16:479-85. doi: 10.1111/iwj.13058. PubMed PMID: 30588742.