

# Differentiation of Glomerular from Non-Glomerular Hematuria by Three Different Methods of Microscopic Examinations of Erythrocytes in Urine

A. Abolfathi, A. Hosaininasab, H. Argani<sup>1</sup>

## Abstract

**Background:** Morphological examinations of urinary erythrocytes can be of diagnostic value in initial evaluation of hematuria. Dysmorphic urinary red blood cells are known to indicate a glomerular origin of bleeding. We examined the clinical usefulness of this test in a population complained of hematuria by use of three different methods: light microscopy, phase contrast microscopy, and Wright staining and compared their sensitivity and specificity.

**Methods:** The study included 169 patients with hematuria (89 glomerular and 80 non-glomerular). The urine specimens were collected before invasive procedures such as biopsy and cystoscopy. In each urine sample, 100 urinary erythrocytes were examined. Statistical analysis was performed using Student's *t* test, correlation coefficient, and  $\chi^2$ . Reliability parameters including sensitivity, specificity and predictive values of negative and positive tests were also evaluated.

**Results:** Dysmorphic red cells were recorded as acanthocytes, doughnut-like cells, yeast like cells with more than one blebs and ghost forms. Isomorphic erythrocytes had uniform size and shape. Significant difference was found in the number of urinary dysmorphic red cells between the two groups of patients. Statistical analysis showed that by using percentage of glomerular type erythrocytes and setting the cut-off at 20-25%, the specificity for three procedures was almost the same ( $\approx 97.5\%$ ). But sensitivity for light microscopy, phase contrast microscopy, and Wright staining was in different ranges as 70.7%, 89.8%, and 86.5% respectively.

**Conclusion:** It was concluded that with some limitations, these simple, non-invasive techniques were useful in identifying the source of bleeding in the work up of hematuria by considering that sensitivity of the methods were in the order of phase contrast microscopy, Wright staining, and light microscopy.

**Iran J Med Sci 2007; 32(3): 163-168.**

**Keywords** • Red blood cell • morphology • hematuria • microscopy

Department of biochemistry,  
Faculty of Medicine,  
<sup>1</sup>Imam Khomeini Hospital,  
Tabriz University of Medical Sciences,  
Tabriz, Iran.

**Correspondence:**  
Aliakbar Abolfathi PhD,  
Department of biochemistry,  
Faculty of Medicine,  
Tabriz University of Medical Sciences,  
Tabriz, Iran.  
**Tel/Fax:** +98 411 3364666  
**Email:** [abolfathiak@yahoo.co.uk](mailto:abolfathiak@yahoo.co.uk)

## Introduction

**E**valuation of the cause of hematuria is a common diagnostic problem in clinical practice. Standard invasive investigations of these patients are expensive and potentially harmful.

Morphological examinations of urinary erythrocytes were suggested by Fairly and Birch,<sup>1</sup> in an attempt to find out methods to be cost effective and low risk for initial evaluation of hematuria. In various studies, morphological examination of urinary erythrocytes by phase contrast microscopy,<sup>1-3</sup> electron microscopy,<sup>1,4</sup> or light microscopy with and without staining,<sup>5-7</sup> has established differences between erythrocytes from glomerular and non-glomerular sources.

Erythrocytes of glomerular origin are usually small, and fragmented with variations in size and shape (dysmorphic). Erythrocytes of non-glomerular origin are largely uniform, resembling normal peripheral red cells (isomorphic), although a variable number may lose their hemoglobin (ghost cells) and few may be crenated.<sup>7,8</sup>

Hematology autoanalyzers have been also used to provide a more objective assessment of urinary erythrocyte morphology to differentiate glomerular from non-glomerular hematuria.<sup>9,10</sup>

Because sensitivity and specificity of various methods used in different studies are contradictory, we aimed to compare the three different microscopic methods; light microscopy (LM) with and without Wright staining and phase contrast microscopy (PCM) to find out the most sensitive and specific method for differentiation of glomerular from non-glomerular hematuria.

## Materials and Methods

### *Patients' selection and specimens' collection*

The study included 169 patients referred to nephrology and urology wards of Imam Khomeini hospital affiliated to Tabriz University of Medical Sciences since October 2001 to September 2003 with the complaint of hematuria. Glomerular and non-glomerular renal disease were detected by intravenous pyelography (IVP), ultrasonography, cystoscopy, or renal biopsy. The urine microscopy was performed by two observers who were blinded to the final diagnosis.

The urine specimens were collected before invasive procedures such as biopsy and cystoscopy. Thirty ml of fresh morning midstream urine was obtained. Urine samples were analyzed by dipstick for albumin, pH, sugar, and blood. The specific gravity of urine samples was controlled by ERMA refractometer. The specimens with pH more than 8 and less than 5 and specific gravity less than 1010 were excluded.

Serum blood urea nitrogen (BUN), creatinine, and glucose and complete blood count (CBC) of patients were also checked. The patients with abnormal morphology of red blood cells in peripheral blood and MCV less than 75 fl or end stage renal failure were excluded.

### *RBC morphology study*

Ten ml of urine was centrifuged at 2000 rpm (400g) for 10 min and sediment was re-suspended in 0.5 ml of supernatant. One drop of sediment was then examined by light microscopy ( $\times 400$ ) and phase contrast microscopy ( $\times 400$ ) by a Zeiss microscope with phase contrast attachment. In each sample of urine, 100 urinary erythrocytes were examined.

After adding one drop of 5% human serum albumin into urinary sediment and mixing it, a drop of suspension was placed on to the glass slide and air-dried smear was prepared. The smears were then stained with 0.3g/100 Wright stain according to the method used by Chang.<sup>11</sup> The slides were covered with cover glass. One hundred red cells were examined by high power ( $\times 1000$ ) and checked for the percentage of dysmorphic, isomorphic, hypochromic and normochromic RBCs.

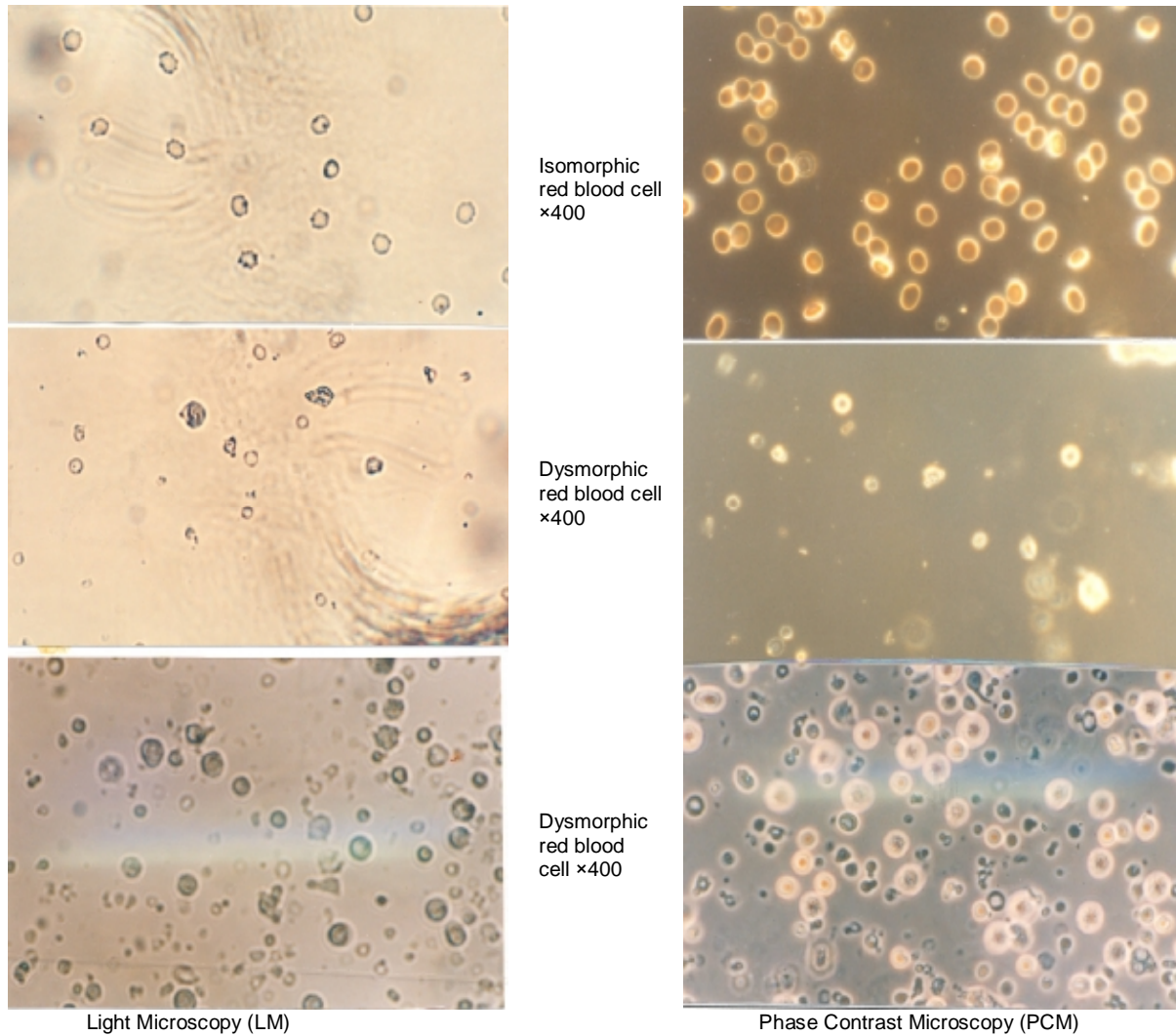
Statistical analysis was performed using Student's *t* test, correlation coefficient,  $\chi^2$ , and cross tabulation using SPSS software (version 11-0). All the values are reported as means  $\pm$  SD. Reliability parameters including sensitivity, specificity and predictive values of negative and positive tests were also evaluated.

## Results

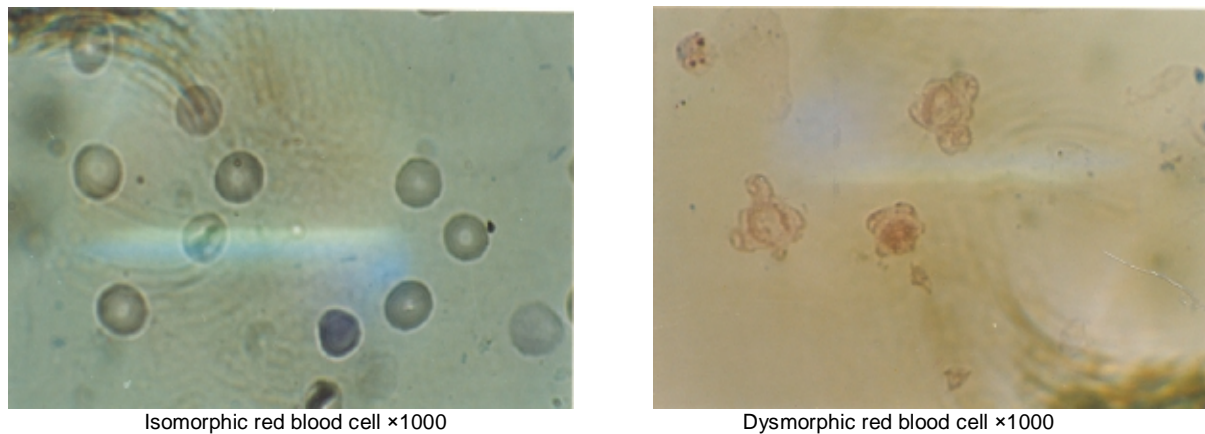
The diagnosis of the 169 patients with hematuria on the basis of the clinical picture and results of the appropriate investigations in radiology, cystoscopy, pathology and immunohistopathology were established. Of these 169 patients, hematuria was considered glomerular in 89 (53%) and non-glomerular in 80 (47%) patients. The mean age of the patients with glomerular hematuria was  $35 \pm 17$  and with non-glomerular hematuria was  $46 \pm 20$  years.

Statistical analysis ( $\chi^2$  test) did not show significant difference in the number of red blood cells in the urine samples between the two groups of patients ( $p > 0.5$ ).

Morphology of urinary erythrocytes as isomorphic and dysmorphic with different microscopic methods including W.S, PCM and LM were studied. Dysmorphic red cells were recorded as acanthocytes, doughnut-like cells, yeast like cells, spherical cells with more than one blebs and ghost forms of erythrocytes. In contrast to these, isomorphic erythrocytes had uniform size and shape (figures 1, 2). As noted in



**Figure 1:** Isomorphic and dysmorphic red blood cells in urine by LM and PCM.



**Figure 2:** Wright's stain smear of urinary sediment. Not isomorphic and dysmorphic RBC.

table 1 there was significant difference ( $p < 0.0001$ ) in the number of urinary dysmorphic red cells between the two groups of patients.

The two groups of patients were compared based on the presence of  $\geq 20\%$ - $25\%$  of dysmorphic erythrocytes in urine specimens and the results listed in table 2. If the cut off point

for dysmorphic erythrocytes be considered as  $\geq 20\%$  of whole red cells count, 75 patients studied by light microscopy, 86 patients by phase contrast microscopy, and 84 patients by Wright staining out of the 89 patients will be diagnosed as having glomerular hematuria. In 80 patients with non-glomerular hematuria, 5

patients studied by light microscopy and 2 patients studied by phase contrast microscopy and Wright staining had 20% or more dysmorphic RBCs respectively. If the cut off point for dysmorphic RBCs be considered  $\geq 25\%$ , these figures for patients with glomerular hematuria will be 63, 80 and 77 respectively.

**Table1:** Source of hematuria determined by conventional evaluation

Disease	Number of patients
Glomerular disease	89
Crescentic glomerulonephritis (CGN)	6
Membranoproliferative glomerulonephritis (MPGN)	24
Mesangioproliferative glomerulonephritis (MEGN)	4
Focal and segmental glomerulonephritis (F&SGS)	15
Minimal change nephrotic syndrome (MCNS)	2
Post streptococcal glomerulonephritis (PSGN)	16
Post infection glomerulonephritis(PIGN)	2
IgA nephropathy (IgAN)	2
Diabetic nephropathy (DN)	6
(AM)	1
Systemic lupus erythematosus	9
Goodpasture s disease (GP)	2
Urological disease	80
Renal calculi	40
Bladder cancer	15
Urethral cancer	2
Prostate cancer	1
Benign prostate hypertrophy	10
Post-transurethral resection	6

**Table 2:** Comparison of mean value of dysmorphic urinary RBCs in two groups of G and NG patients by three methods.

	NG=80	G=89	P value
	Mean±SD	Mean±SD	
LM	7.8±5.7	36.2±15.2	<0.0001
PCM	8.3±6.6	48.7±18.4	<0.0001
W.S	7.9±6.1	46.6±18.1	<0.0001

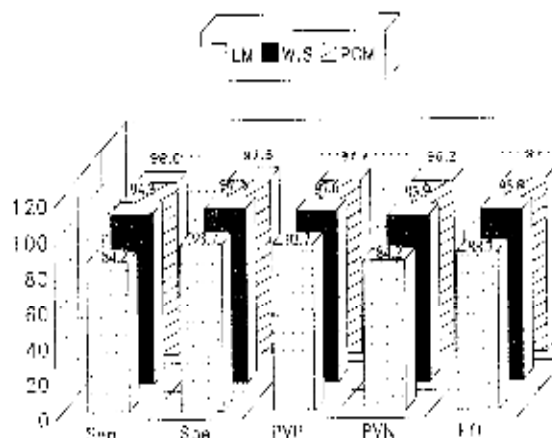
G=glomerular hematuria, PCM=phase contrast microscopy, NG=Non-glomerular hematuria, W.S=wright staining, LM=light microscopy

Analysis of variance did not show significant difference between number of dysmorphic RBCs and origin of glomerular hematuria ( $p>0.5$ ). To find out differential cut off between the number of dysmorphic RBCs and origin of hematuria, reliability parameters (sensitivity, specificity, positive predictive value, negative predictive value, and efficiency) were calculated (figure 3). These results revealed that 20-25% diagnostic "cut off" can be used by all three methods to differentiate glomerular from non-glomerular hematuria (figure 3).

Urine sediments stained by Wright staining showed significant increase in hypochromic red cells in patients with glomerular hematuria compared with patients with non-glomerular hematuria ( $p<0.001$ ). So hypochromic red cells

could have diagnostic value for differentiation of non-glomerular from glomerular hematuria, especially by Wright staining method.

In this survey also significant increase in ghost cells were observed in glomerular hematuria compared with non-glomerular hematuria ( $p<0.001$ ).



**Figure3:** Comparison of Reliability parameter in detection of glomerular hematuria with  $\geq 20\%$  dysmorphic urinary red blood cells in three different methods.

Sen=sensitivity, Spe=specificity, PVP=positive predictive value, PVN=negative positive predictive value, Eff=efficiency

To find the most sensitive method among the three methods, statistical analysis showed that both phase contrast microscopy and Wright staining were more sensitive than light microscopy to differentiate dysmorphic from isomorphic erythrocytes. There was no significant difference between phase contrast microscopy and Wright staining in diagnosis of dysmorphic RBCs. Correlation coefficients of 0.93, 0.94 and 0.99 were obtained respectively when phase contrast microscopy with light microscopy, Wright staining with light microscopy and phase contrast microscopy with Wright staining were compared.

### Discussion

Hematuria is the most prevalent clinical finding of kidney and urinary tract disease. With respect to its origin it could be divided to glomerular and non-glomerular.<sup>12</sup> The cause of red cell deformity which is used for differential diagnosis is still speculative. Different factors including, mechanical damage caused by passage of red blood cells through the glomerular basement membrane,<sup>13</sup> and biochemical changes (e.g osmolality, pH, urinary protein),<sup>14</sup> are assumed to be associated with dysmorphic transformation of urinary erythrocytes. Examination of urinary erythrocyte morphology has been proposed to differentiate glomerular from non-glomerular hematuria since 1979.<sup>15</sup> After nearly 25 years of this approach, reported

diagnostic rates are variable. The morphological definition of a dysmorphic erythrocyte,<sup>16-18</sup> and absolute number of dysmorphic erythrocytes necessary to make diagnosis of glomerular bleeding,<sup>19,20</sup> are widely variable. The clinical use of examination is also controversial.

In attempt to suggest definite criteria for glomerular bleeding from non-glomerular in this study, two parameters were found to be more important: glomerular and non-glomerular shape of urinary erythrocytes including size and form and percentage. The first report of variation in size and shape of urinary red blood cells in more detail was described by Birch and Fairly,<sup>15</sup> who correlated changes with clinical information. They recorded crenate and uniform as normal and anisocytes with abnormal shapes as dysmorphic. While Fassett and his colleagues,<sup>21</sup> reported echinocytes as abnormal but Kohler and Eveline,<sup>22</sup> described echinocytes and stomatocytes as normal red blood cells in urine. Tomati and his colleagues classified urinary erythrocytes into 10 shapes by differential interference microscopy (DIM).<sup>18</sup> In their classification; acanthocytes, doughnut-like cells with blebs, and yeast-like cells were the most distinguished among dysmorphic cells. In recent studies the detection of acanthocytes, doughnut shaped RBCs, and G1 cells in urine are suggested as a useful tool for the diagnosis of glomerular bleeding.<sup>23-25</sup> In addition to dysmorphic changes, urinary red blood cells from patients with glomerular disease were often hypochromic.<sup>5</sup> So that color of red blood cells could have diagnostic value.

In the present study, we tried to make definition of dysmorphic more accurately. In our study only restricted shapes (acanthocytes, doughnut-like cells, yeast-like cells and smaller erythrocytes with deformity) were counted and other dysmorphic shapes were ignored. Our cut-off to differentiate glomerular from non-glomerular hematuria was 20-25% dysmorphic red blood cells in urine. Our cut-off point was similar to Dekermerschou,<sup>26</sup> who diagnosed glomerular hematuria in the presence of 20% dysmorphic RBC. But other cut-off points that were defined for glomerular bleeding were variable from 10 to 80% dysmorphic RBC.<sup>22,26,27</sup> This variance could be reflected from different definitions of dysmorphic RBC. According to our criteria the dysmorphic RBCs in urine of patients with non-glomerular hematuria were rare and so 20-25% cut-off was an accurate point to specify glomerular bleeding.<sup>27</sup>

In contrast to Miltenyi and his colleagues,<sup>27</sup> who reported a relatively low specificity (63.6%) and sensitivity (84%) of dysmorphia for the diagnosis of glomerular disease, the reported specificity (96-98%) and sensitivity

(87-90%) in this study is in agreement with some other reports.<sup>2,28,29</sup>

Although according to the above-mentioned criteria, we found that phase contrast microscopy and Wright staining methods were more sensitive than light microscopy, but it still can be useful in the presence of skilled cytopathologist or expert nephrologists to investigate morphology of urine erythrocytes properly.

Our study confirms that examination of erythrocytes in the urine with these methods is simple, inexpensive, non-invasive and repeatable that permits an accurate distinction between glomerular and non-glomerular hematuria. These methods do not lead to a definite diagnosis, but do enable the selection of the most appropriate test and thus avoid unnecessary, often invasive diagnostic procedures.

## References

- 1 Birch DF, Fairley KF, Whitworth JA, et al. Urinary erythrocyte morphology in the diagnosis of glomerular hematuria. *Clin Nephrol* 1983; 20: 78-84.
- 2 Rizzoni G, Braggion F, Zacchello G. Evaluation of glomerular and non-glomerular hematuria by phase-contrast microscopy. *J Pediatr* 1983; 103: 370-4.
- 3 Pillsworth TJ Jr, Haver VM, Abrass CK, Delaney CJ. Differentiation of renal from non-renal hematuria by microscopic examination of erythrocytes in urine. *Clin Chem* 1987; 33: 1791-5.
- 4 Fassett RG, Horgan B, Gove D, Mathew TH. Scanning electron microscopy of glomerular and nonglomerular red blood cells. *Clin Nephrol* 1983; 20: 11-6.
- 5 Chang BS. Red cell morphology as a diagnostic aid in hematuria. *JAMA* 1984; 252: 1747-9
- 6 Hauglustaine D, Bollens W, Michielsen P. Detection of glomerular bleeding using a simple staining method for light microscopy. *Lancet* 1982; 2: 761-2
- 7 Zaman Z, Proesmans W. Dysmorphic erythrocytes and G1 cells as markers of glomerular hematuria. *Pediatr Nephrol* 2000; 14: 980-4.
- 8 Györy AZ, Hadfield C, Lauer CS. Value of urine microscopy in predicting histological changes in kidney: double blind comparison. *Br Med J* 1984; 288: 819-22.
- 9 Shichiri M, Oowada A, Nishio Y, et al. Use of autoanalyzer to examine urinary red cell morphology in the diagnosis of glomerular hematuria. *Lancet* 1986; 2: 781-2.
- 10 Goldwasser P, Antignani A, Mittman N, et al. Urinary red cell size: diagnostic value and determinants. *Am J Nephrol* 1990; 10: 148-56.

- 11 Chang BS. Red cell morphology as a diagnostic aid in hematuria. *JAMA* 1984; 252: 1747-9.
- 12 Fünfstück R, Stein G. Erythrocytes in urine; glomerulonephritis or other source of bleeding. Answer with microscope. *MMW Fortschr Med* 2000; 142: 30-2.
- 13 Collar JE, Ladva S, Cairns TD, Cattell V. Red cell traverse through thin glomerular basement membrane. *Kidney Int* 2001; 59: 2069-72.
- 14 Halbhuber KJ, Fünfstück R, Kühn B, et al. Dysmorphic red cell formation in glomerulonephritis. In vitro generation of dysmorphic erythrocytes. *Cell Mol Biol (Noisy-le-grand)* 1994; 40: 1125-33.
- 15 Birch DF, Fairley KF. Hematuria: Glomerular or nonglomerular? *Lancet* 1979; 11: 845-6.
- 16 Fairley KF, Birch DF. Hematuria. A simple method for identification of glomerular bleeding. *Kidney Int* 1982; 21: 105-8.
- 17 Chu YD, Kitamoto Y, Tomita M, et al. Differentiation of haematuria by differential interference microscopy with a simple criterion. *Kumamoto Med J* 1990; 42: 63-71.
- 18 Tomita M, Kitamoto Y, Nakayama M, Sato T. A new morphological classification of urinary erythrocytes for differential diagnosis of glomerular hematuria. *Clin Nephrol* 1994; 37: 84-9.
- 19 Fischereeder M. Hematuria and nephritic sediment. *MMW Fortschr Med* 2004; 146: 35-6, 38.
- 20 Marcussen N, Schumann JL, Schumann GB, et al. Analysis of cytodifferential urinalysis findings in 77 patients with concurrent renal biopsies. *Am J Kidney Dis* 1992; 20: 618-28.
- 21 Fasset RG, Horgan B, Mathew TH. Detection of glomerular bleeding by phase contrast microscopy. *Lancet* 1982; 26: 1432-4.
- 22 Köhler H, Wandel E, Brunck B. Acanthocyturia a characteristic marker for glomerular bleeding. *Kidney Int* 1991; 40: 115-20.
- 23 Miura H., Igarashi M, Tominaga M. Evaluation of new method for diagnosis of the origin of urinary bleeding by the morphological characteristics of urinary red blood cells. *Rinsho Byori* 2003; 51: 740-4.
- 24 Heine GH, Sester U, Grindt M, Köhler H. Acanthocytocytes in urine: useful tool to differentiate diabetic nephropathy from glomerulonephritis? *Diabetes Care* 2004; 27: 190-4.
- 25 Naghama D, Yoshiko K, Watanabe M, et al. A useful new classification of dysmorphic urinary erythrocytes. *Clin Exp Nephrol* 2005; 9: 304-9.
- 26 de Kermerchou S, Makdassi R, Deturck M, et al. Clinical value of studying hematuria using phase contrast microscopy. *Nephrologie* 1993; 14: 231-7.
- 27 Miltényi M, Tulassay T, Tausz I. Urinary protein patterns for differential diagnosis of glomerular hematuria. *Clin Nephrol* 1984; 22: 105.
- 28 Stapleton FB. Morphology of urinary red blood cells: A simple guide in localizing the site of hematuria. *Pediatr Clin North Am* 1987; 34: 561-9.
- 29 De Santo NG, Nuzzi F, Copodicasa G, et al. Phase contrast microscopy of the urine sediment for the diagnosis of glomerular and nonglomerular bleeding—Data in children and adults with normal creatinine clearance. *Nephron* 1987; 45: 35-9.