

Granuloma Annulare and Anterior Uveitis

M. Rahimi, N. Moinfar¹

Abstract

Granuloma annulare is self-limiting cutaneous condition of unknown etiology, causing necrobiotic dermal and subcutaneous papules. A number of conditions have been described in association with *Granuloma annulare*, including lymphoma, anemia, intestinal bleeding, seronegative arthralgia, vasculitis and autoimmune thyroiditis. This manuscript, as the first report of this combination in Iran, describes an unusual case of relapsing, concomitant anterior uveitis and biopsy proven *granuloma annulare*.

Iran J Med Sci 2005; 30(3): 144-146.

Keywords • *Granuloma annulare* • uveitis • dermatosis

Introduction

Anterior uveitis, is the most common form of ocular inflammation encountered. It is a common cause of a painful red eye. The exact pathophysiology is not yet known. Frequently, the cause is idiopathic, but certain ocular and systemic diseases may be the underlying cause of the iritis.¹ *granuloma annulare* (GA) is a benign, idiopathic, inflammatory dermatosis characterized clinically by dermal papules and annular plaques. Several different clinical variants are recognized including localized, generalized, subcutaneous, perforating and arcuate dermal erythema.² Actinic granuloma is viewed by some as a subset of GA, but by others as a separate but related entity.^{3,4} Inflammation are seen on histological examination foci of degenerative collagen associated with palisade granulomatous.⁵⁻⁷ Proposed pathogenic mechanisms include, cell-mediated immunity (type IV), immune complex vasculitis and an abnormality of tissue monocytes. However, none have convincing evidence to support them.⁸ A number of systemic and ocular conditions have been described in association with GA.⁹ we describe a patient with anterior uveitis who also suffered from GA.

Case Report

A 60-yr-old man from South of Iran referred to Uveitis Clinic, Shiraz University of Medical Sciences, presented with blurred vision and right eye pain several months after the onset of a peculiar rash along the back, upper arms and waist (Fig 1). His family, past medical and ocular history was negative. A detailed review of constitutional symptoms was unremarkable.

Best-corrected visual acuity was 20/30 in the right eye, and 20/20 in the left eye. The ocular examination was significant for posterior synechiae in the right eye with 2+ cell and flare. No granulomatous keratic precipitates or iris nodules were noted. There were no vitreous cells, no evidence of retinal vasculitis, chorioretinal infiltrates or papillitis. Serology for autoimmune conditions including HLA haplotyping was negative.

Department of Ophthalmology,
Khalili Hospital,
Shiraz, Iran,
and ¹Vitreoretinal Division,
Magruder Eye Institute, Orlando,
Florida, USA.

Correspondence:

Mansour Rahimi MD,
Ophthalmology Department,
Khalili Hospital,
Shiraz University of Medical Sciences,
Shiraz, Iran.
Tel: +98 711 6279373
Fax: +98 711 6279373
E-mail: mrahimi@sums.ac.ir

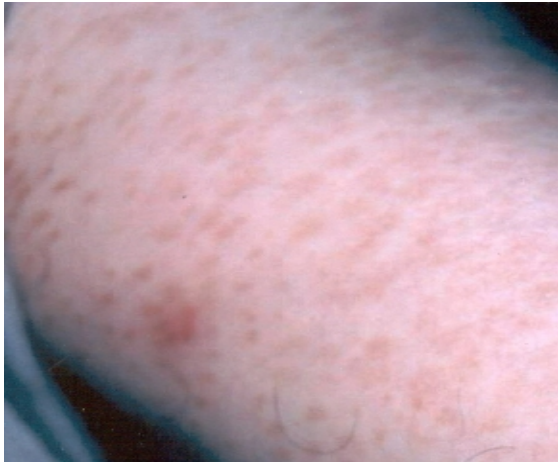

Fig 1: Dermal papules and annular plaques on the forearm

Punch biopsies of the subcutaneous nodules taken from multiple sites revealed collagen degeneration surrounded by epithelioid histiocytes and multinucleated giant cells, as well as increased extracellular mucin, consistent with GA (Fig 2). Both the uveitis and skin lesions responded initially to topical and systemic steroids, but relapsed concurrently during steroid tapering.

Discussion

This unique case describes a novel and concomitant association between uveitis and a cutaneous exanthem. GA is not a common necrobiotic cutaneous condition with multiple disease associations. It is now suggested that GA, particularly in its association with autoimmune thyroiditis in females, belongs in the spectrum of autoimmune conditions.¹⁰ Multiple other disease associations have now been described, including anemia and leukopenia,¹¹ vasculitis.¹² The patient in this case did eventually develop profound anemia, with the etiology as of yet undetermined. Given previous of lower intestinal bleeding as well as ileal and mesenteric elastotic granulomas seen with GA,¹¹ patients presenting with uveitis and rashes suggestive of GA should consider having gastrointestinal studies (barium enema, sigmoidoscopy, as in our patient).

Skin changes often direct the clinician to the accurate diagnosis of intraocular inflammation. The exanthem of lupus, rash of psoriatic arthritis, vitiligo of Harada's disease and aphthous lesions of Behçet's disease are examples. We suggest that physician treating uveitis become familiar with the distinctive cutaneous features of GA, and consider this association as part of their differential diagnoses. Further workup, particularly for anemia and gastrointestinal disease, is warranted.

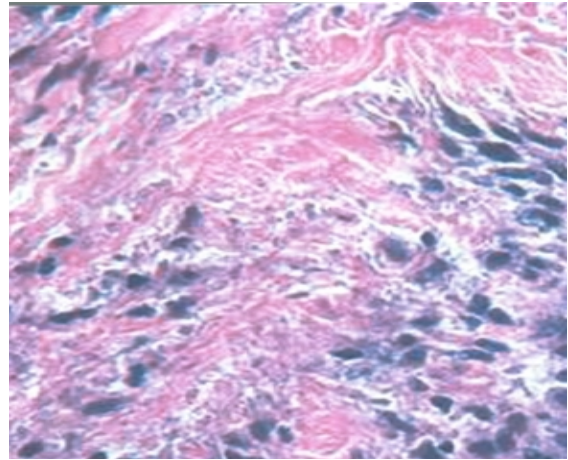


Fig 2: High-power magnification showing some of the spindle cells radiating around the periphery of the zone of altered collagen. (H/E; original magnification, x40).

References

- 1 Nussenblatt RB, Whitcup SM: Uveitis: Fundamentals and clinical practice. Third ed. Philadelphia: Mosby, 2005.
- 2 Smith MD, Downie JB, DiCostanzo D. Granuloma annulare. *Int J Dermatol* 1997; 36: 326-33.
- 3 Ghadially R. Granuloma annulare, actinic granuloma. In: Arndt K, et al, eds. Cutaneous Medicine and Surgery. WB Saunders Co; 1996. p. 438-43.
- 4 O'Brien JP, Regan W. Actinically degenerate elastic tissue is the likely antigenic basis of actinic granuloma of the skin and of temporal arteritis. *J Am Acad Dermatol* 1999; 40: 214-22.
- 5 Argent JD, Fairhurst JJ, Clarke NM. Subcutaneous granuloma annulare: four cases and review of the literature. *Pediatr Radiol* 1994; 24: 527-9.
- 6 Chung S, Frush DP, Prose NS. Subcutaneous granuloma annulare: MR imaging features in six children and literature review. *Radiology* 1999; 210: 845-9.
- 7 De Maeseneer M, Vande Walle H, Lenchik L. Subcutaneous granuloma annulare: MR imaging findings. *Skeletal Radiol* 1998; 27: 215-7.
- 8 Felner EI, Steinberg JB, Weinberg AG. Subcutaneous granuloma annulare: a review of 47 cases. *Pediatrics* 1997; 100: 965-7.
- 9 Braun-Falco O, Plewig G, Wolff HH, et al. Granuloma annulare. In: Braun-Falco O, ed. *Dermatology*. 2nd ed. Berlin: Springer-Verlag; 2000. p. 1387-9.
- 10 Vazquez-Lopez F, Pereiro M Jr, Manjon Haces JA, et al. Localized granuloma annulare and autoimmune thyroiditis in adult women: a case-control study. *J Am Acad*

- Dermatol* 2003; 48: 517-20.
- 11 Kurose N, Nakagawa H, Iozumi K, et al. Systemic elastotic granulomatosis with cutaneous, ocular, lymph nodal and intestinal involvement. *J Am Acad Dermatol* 1992; 26: 359-63.
- 12 Van Kooij B, van Dijk MC, de Boer J, et al. Is granuloma annulare related to intermediate uveitis with retinal vasculitis? *Br J Ophthalmol* 2003; 87: 763-6.

Visit on the Web at:
<http://www.sums.ac.ir/IJMS>