

# Psychosis as an Early Presentation of Neuro-Brucellosis

A.R. Ghaffarinejad, F. Sarafzadeh<sup>1</sup>,  
B. Sedighi<sup>2</sup>, T. Sadeghieh

## Abstract

Brucellosis is an endemic zoonotic infectious disease in Middle East countries including Iran. This infection may involve central nervous system. Psychosis has been reported in rare cases with chronic brucellosis.

A 26-year-old male shepherd patient who developed neuro-brucellosis and psychosis is presented. He had hallucinations (visual and auditory) and delusions. He was also impulsive and had serious difficulty in speech.

In patients with atypical psychosis in endemic areas, physicians should consider the portability of chronic brucellosis.

**Iran J Med Sci 2008; 33(1): 57-59.**

**Keywords** • Brucellosis • psychosis • Iran

## Introduction

**B**rucellosis is a zoonotic infectious illness, which can be transmitted to humans, from infected animals mainly after consumption of unpasteurized milk and milk products. It can also be transmitted after direct contact with infected animals via inhalation especially to children, slaughter house workers, farmers, and laboratory workers.<sup>1</sup> The disease is endemic in Iran as well as in other Middle East countries.<sup>2</sup>

Neurological involvement is a rare but serious complication and it occurs in 2-5% of patients. Neurological signs can appear during the active phase of disease or later.<sup>3</sup> Common clinical manifestations of neuro-brucellosis include meningoencephalitis, acute and subacute meningitis, and intracranial hypertension.<sup>4</sup>

Psychosis as a presentation of neuro-brucellosis is a rare condition. There were only a few previous reports of brucellar psychosis in the literature. Herein we report a case of brucellar psychosis and discuss his signs and symptoms.

## Case History

A 26-year-old man, married, shepherd, from Baft city, Kerman, (south of Iran) was admitted to Kerman psychiatric hospital because of acute psychotic symptoms. He had no positive previous and family history of psychiatric disorders. Six months before his psychiatric presentation, he developed high temperature, headache, ataxia, malaise, fatigue, and irrelevant speech. He was admitted to a local general hospital.

At that time he had resting tremor and cogwheel rigidity in neurological examination. Wright agglutination test of blood was positive ( $\frac{1}{640}$ ) and 2-mercaptoethanol (2-ME) reduction test of blood

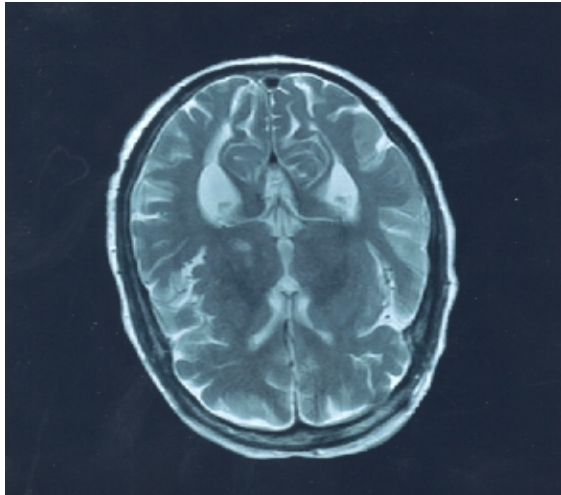
was positive ( $\frac{1}{320}$ ) as well. He was treated with doxycycline,

Department of Psychiatry,  
<sup>1</sup>Internal Medical, <sup>2</sup>Neurology,  
Kerman University of Medical Sciences,  
Kerman, Iran.

### Correspondence:

Alireza Ghaffarinejad MD,  
Department of Psychiatry,  
Kerman University of Medical Sciences,  
Kerman, Iran.  
Tel: + 98 341 2116328  
Fax: + 98 341 2110856  
Email: ghaffari\_ar@yahoo.com

rifampin, and Co-trimoxazole. Then he was transferred to neurological ward, where brain magnetic resonance imaging (MRI) was done and non-specific T<sub>2</sub> bright signals in basal ganglia were detected. There was no brain atrophy (figure 1). Two-mercaptoethanol test of CSF was positive ( $\frac{1}{125}$ ). Other findings were unremarkable.



**Figure 1:** Brain MRI shows non-specific T<sub>2</sub> bright signals in basal ganglia.

In the second admission to the psychiatric ward six months after discharge from general hospital, he was still taking his antibiotics and test of 2-ME of CSF was negative. Parkinsonian symptoms were subsided and a fine cogwheel rigidity could be detected only by precise examination. He was highly restless and impulsive, and had episodic unreasonable crying. His speech was high pitched, loud, incoherent, and sometimes resemble screaming associated with tearful eyes, and labile affect, but there was no evidence of genuine sadness. This condition was changed rapidly and replaced by impulses of laughing when the topic was changed by interviewer. He reported to be able to see and hear the voices of three fairy females who seduced and invited him for dance. He had uninhibited sexual impulses. His cognition was intact and had only partial insight. Two months after starting the treatment with 6 mg risperidone and 6 mg trihexyphenidyl, frequency of his impulsive behavior, delusions, and hallucinations were decreased, but his style of speech remained unchanged. Despite proper treatment with antibiotic, 2-ME test of blood remains positive ( $\frac{1}{320}$ ).

## Discussion

Nervous system involvement is not common in

brucellosis, so when neurological manifestations are predominant, the accurate diagnosis of brucellosis will be difficult. In such cases the bout of acute brucellosis may have been mild and mistaken for influenza or some other infectious diseases.

Failure to diagnose acute brucellosis prevents adequate treatment with antibiotics.<sup>5</sup> In our report, diagnosis of brucellosis was documented in the first stage of illness and the patient received adequate antibiotics. Although antibiotic treatment was continued for several months, neuro-brucellosis developed as a complication of subacute brucellosis.

Depression is the most frequent psychiatric disturbance in brucellosis. In acute brucellosis similar to the other febrile illnesses, delirium may occur.<sup>6</sup> So delusions and hallucinations may be the first presentation of brucellosis.<sup>7</sup>

Occurrence of psychosis following acute stage of brucellosis is a rare condition. To the best of our knowledge there were only two previous reports of psychosis with chronic brucellosis.<sup>8,9</sup> In one report the patient had clinical picture of schizophreniform psychosis.<sup>9</sup> Our patient had special features. In the presence of intact cognition, he had persistent hallucinations and delusion, so in these aspects he resembled to schizophrenic patients. But serious problem in speech are not seen in patients with schizophrenia. Labile affect and uninhibited behavior were similar to what are usually seen in patients in organic brain syndromes. Adequate antibiotic therapy in the 6 months period could not prevent the occurrence of psychosis.

We concluded that presence of psychotic symptoms without impaired cognition and fever could suggest the presence of chronic brucellosis. Before starting full blown psychosis, the patient had Parkinsonian symptoms. Transient Parkinsonism was reported in neuro-brucellosis,<sup>10</sup> psychosis in patients with chronic brucellosis has not yet clarified.

In patients with atypical psychosis in endemic areas, physicians should consider the portability of chronic brucellosis.

## References

- 1 Young EJ. *Brucella species*. In: Mandell GL, Bennett JE, Dolin R, eds. *Mandell, Douglas and Bennett's diseases*. Philadelphia; Churchill Livingstone; 2000. p. 2386-92.
- 2 Ayatollahi J. Epidemiological, clinical, diagnostic and therapeutic survey of 686 cases of brucellosis. *Ann Saudi Med* 2004; 24: 398-9.
- 3 Bellissima P, Turturici MA. Neurobrucellosis: Clinical and therapeutic features. *Infez Med* 1998; 6: 25-30.

- 4 Koussa S, Tohmé A, Ghayad E, et al. Neurobrucellosis: clinical features and therapeutic responses in 15 patients. *Rev Neurol (Paris)* 2003; 159: 1148-55.
- 5 Povar J, Aguirre JM, Arazo P, et al. Brucellosis with nervous system involvement. *An Med Interna* 1991; 8: 387-90.
- 6 Izadi S. *Neurobrucellosis SEMJ* 2001; 2: 1-7.
- 7 Amato E, Anasagasti I, Poza JJ, Yerobi JA. Acute psychosis as a manifestation of brucellosis. *Enferm Infecc Microbiol Clin* 1989; 7: 231-2.
- 8 Mohr JA, Wilson JD. Psychosis with chronic brucellosis. *J Okla State Med Assoc* 1973; 66: 319-21.
- 9 Annesley PT. Schizophreniform psychosis with chronic brucellosis. *Br J Psychiatry* 1968; 114: 353-4.
- 10 Mousa AR, Koshy TS, Araj GF, et al. Brucella meningitis: Presentation, diagnosis and treatment—a prospective study of ten cases. *Q J Med* 1986; 60: 873-85.